


**PATIENT**

Snuggles Cardose

**PRESENTING CLINICAL SIGNS**

second opinion heart dz and collapsing trachea , concern for R sided heart failure muffled heart sounds on exam Current meds Doxy, hydrocodone

**SPECIES**

Canine

**ULTRASONOGRAPHIC EXAMINATION OF THE HEART**
**BREED**

Lhasa Apso

**SEX**

Spayed Female

**AGE**

15 Years

**WEIGHT**

20 Pounds

CANINE CARDIAC PARAMETERS	MR VMAX (m/s)	TR VMAX (m/s)	LA/AO (Boon method)	LA/AO (Heart Base; Swe)	FS (%)	EF (%)	EPSS (cm)
NORMAL PARAMETER	4.5-5.5	<2.7	1.3	<1.6	28-40	40-100	<0.6
PATIENT			1.1	1.17	35		0.1
CANINE CARDIAC PARAMETERS	HR (BPM)	AV VMAX (m/s)	PV MAX (m/s)	BODY WEIGHT (kg)	LA 2D short axis Base view (cm)	LVIDd Avg; 2D and m-mode short axis (cm)	LVIDs Avg; 2D and m-mode short axis (cm)
NORMAL PARAMETER	50-100	0.7-1.7	0.7-1.6				
PATIENT		1.0	0.6		2.55	2.8	

**Cardiac Presentation**

The echocardiogram in this patient demonstrated normal **left atrial** size based on 3 separate methods of LA evaluation. The cranial and caudal **mitral** valve leaflets presented normal linear structure, extension in systole, and union in diastole with normal kinesis. The **left ventricle** presented thicknesses with linear contour and was not dilated nor restricted. The **myocardium** presented normal echogenicity without subjective evidence of significant fibrotic or ischemic disease. **Contractility** of the ventricular walls was adequate and in normal range for this patient evidenced by the fractional shortening measurement and subjective evaluation of the different regions of the myocardium. The **left ventricular outflow** tract demonstrated normal laminar flow and subjective structural integrity. The **right atrium** and auricle revealed normal size, structure and content. No evidence of masses was noted. **Tricuspid** valvular assessment demonstrated adequate linear morphology and kinesis. The **right ventricle** was of normal size (1/3 diameter of LV), chordae structure, myocardial echogenicity and thickness. **Pulmonary outflow** tract assessment revealed normal valve structure, laminar flow, and diameter (approx. 1:1 pa/ao ratio). No visible **pericardial** or free pleura fluid was noted. The cranial **mediastinum and pericardial and extra-cardiac regions** were free of masses in the visible window. Periodic arrhythmia noted, likely sinus arrhythmia given the patient history.

**ULTRASONOGRAPHIC FINDINGS**

- Normal echocardiogram with periodic arrhythmia

**INTERPRETATION OF THE FINDINGS & FURTHER RECOMMENDATIONS**

No evidence of cardiac disease to be responsible for the clinical signs. Primary respiratory evaluation warranted through chest radiographs and/or CT. The cough is non-cardiogenic in this patient. However, periodic arrhythmia is present. This may be simple sinus arrhythmia. However, EKG warranted.

**INTERPRETED BY**

 Eric Lindquist, DMV  
 DABVP, Cert. IVUSS

**IMAGING PERFORMED BY**

Jenn

**HOSPITAL NAME**

Rockaway AH

**REFERRING VET**

Dr. Maniar

**INVOICE**

33172

**DATE**

12/2/21



**PATIENT**

Snuggles Cardose

**SPECIES**

Canine

**BREED**

Lhasa Apso

**SEX**

Spayed Female

**AGE**

15 Years

**WEIGHT**

20 Pounds

**INTERPRETED BY**

Eric Lindquist, DMV  
DABVP, Cert. IVUSS

**IMAGING PERFORMED BY**

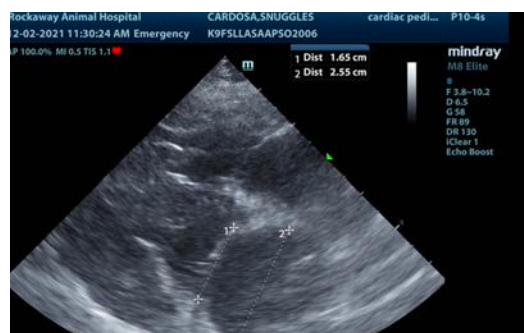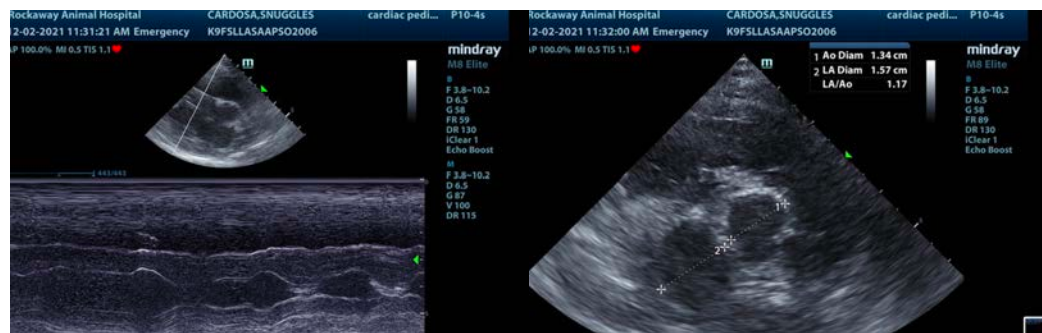
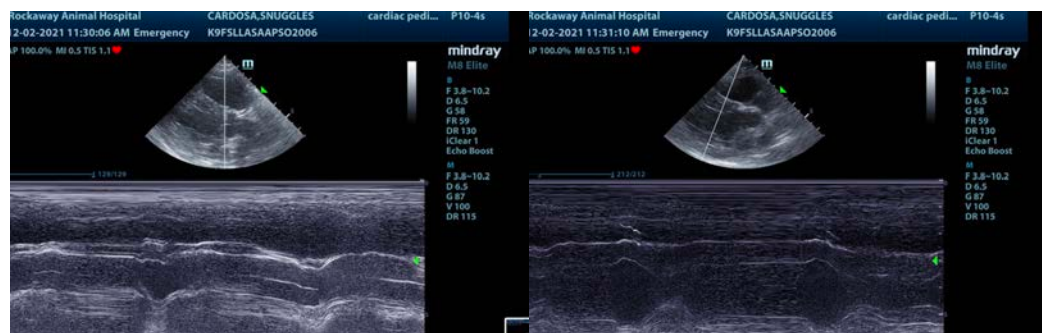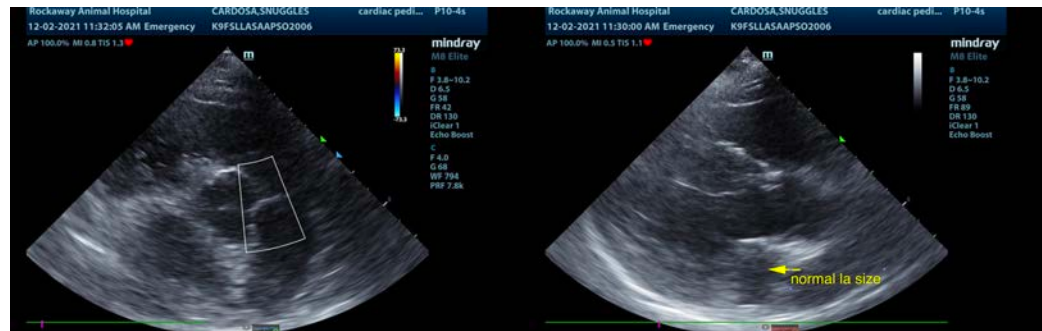Jenn

**HOSPITAL NAME**

Rockaway AH

**REFERRING VET**

Dr. Maniar



**INVOICE**

33172

**DATE**

12/2/21

The information and recommendations provided are based on the images presented by the referring veterinarian. No evaluation can be communicated regarding pathology that was not visible in the image/video clips provided.

Thank you for this referral. If the clinical or image interpretation does not parallel your findings or if I can be of any further assistance please contact me.

**Eric Lindquist, DMV, DABVP, Cert. IVUSS, CEO of SonoPath.com**  
[info@SonoPath.com](mailto:info@SonoPath.com)