
PATIENT

Sheldon Bowlby

PRESENTING CLINICAL SIGNS

History: echo for pre-dental anesthetic check

SPECIES

Canine

BREED

 Cavalier King Charles
Spaniel

SEX

Neutered male

AGE

7 years

WEIGHT

19 lbs

INTERPRETED BY

 Eric Lindquist, DMV
DABVP, Cert. IVUSS

IMAGING PERFORMED BY

Diane McFadden, RVT

HOSPITAL NAME

Blirstown AH

INVOICE

94287

DATE

12/2/21

ULTRASONOGRAPHIC EXAMINATION OF THE HEART

Persistently normal left atrial volumes, slight prolapse of the anterior mitral valve leaflet was noted. Left atrial and left ventricular volumes were normal with adequate contractility to provide compensation for the mitral insufficiency. Trivial tricuspid insufficiency was noted without right atrial enlargement. Minor tricuspid insufficiency measured 2.0 m/sec. The right ventricle was unremarkable. The pericardium was unremarkable. The pulmonic and aortic outflows were unremarkable.

CANINE CARDIAC PARAMETERS	MR VMAX (m/s)	TR VMAX (m/s)	LA/AO (Boon method)	LA/AO (Heart Base; Swe)	FS (%)	EF (%)	EPSS (cm)
NORMAL PARAMETER	4.5-5.5	<2.7	1.3	<1.6	28-40	40-100	<0.6
PATIENT	5.5	2.0	NM		45		NM
CANINE CARDIAC PARAMETERS	HR (BPM)	AV VMAX (m/s)	PV MAX (m/s)	BODY WEIGHT (kg)	LA 2D short axis Base view (cm)	LVIDd Avg; 2D and m- mode short axis (cm)	LVIDs Avg; 2D and m-mode short axis (cm)
NORMAL PARAMETER	50-100	0.7-1.7	0.7-1.6				
PATIENT		1.5	1.6	19 lbs	2.87 max	2.8	

ULTRASONOGRAPHIC FINDINGS

Persistent stage B1 valvular disease.

INTERPRETATION OF THE FINDINGS & FURTHER RECOMMENDATIONS

There was no progression from the prior sonogram. There is no overt contraindication to anesthetic procedure. If anesthesia is necessary, there is no overt contraindication to an anesthetic procedure. Suggested protocol includes Torbutrol premed, Propofol induction, and Isoflurane maintenance. Recheck echocardiogram in 6 months or earlier if murmur grade increases or clinical signs initiate.



PATIENT

Sheldon Bowlby

SPECIES

Canine

BREED

Cavalier King Charles
Spaniel

SEX

Neutered male

AGE

7 years

WEIGHT

19 lbs

INTERPRETED BY

Eric Lindquist, DMV
DABVP, Cert. IVUS

**IMAGING
PERFORMED BY**

Diane McFadden, RVT

HOSPITAL NAME

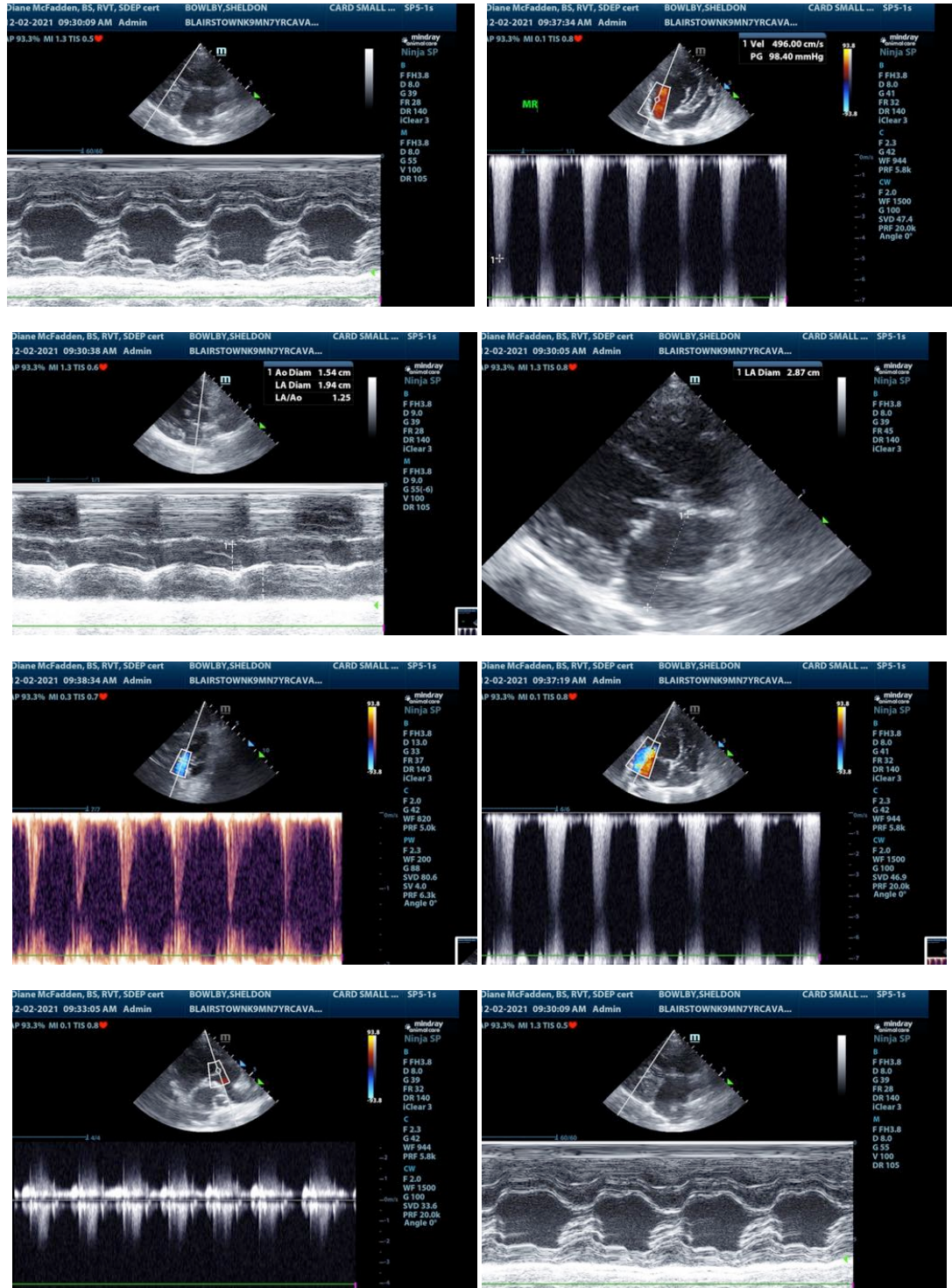
Blairstown AH

INVOICE

94287

DATE

12/2/21





PATIENT

Sheldon Bowlby

SPECIES

Canine

BREED

Cavalier King Charles
Spaniel

SEX

Neutered male

AGE

7 years

WEIGHT

19 lbs

INTERPRETED BY

Eric Lindquist, DMV
DABVP, Cert. IVUSS

**IMAGING
PERFORMED BY**

Diane McFadden, RVT

HOSPITAL NAME

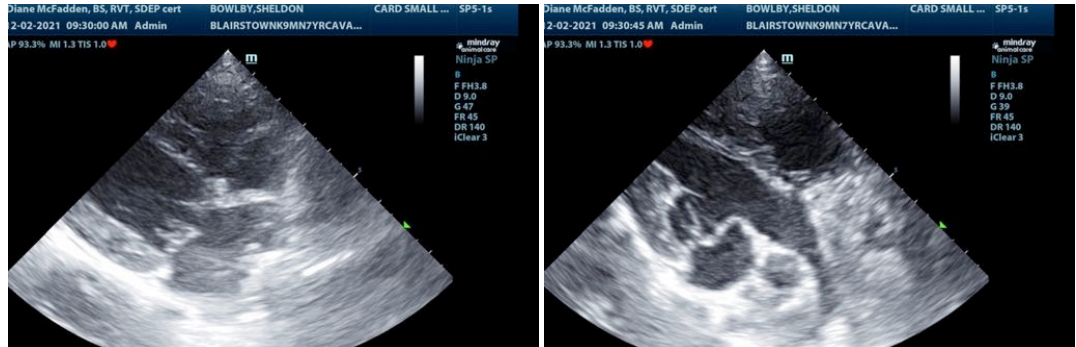
Blairstown AH

INVOICE

94287

DATE

12/2/21



The information and recommendations provided are based on the images presented by the referring veterinarian. No evaluation can be communicated regarding pathology that was not visible in the image/video clips provided.

Thank you for this referral. If the clinical or image interpretation does not parallel your findings or if I can be of any further assistance please contact me.

Eric Lindquist, DMV, DABVP, Cert. IVUSS, CEO of SonoPath.com
Info@SonoPath.com