



PATIENT

Roxie Matthews

SPECIES

Canine

BREED

Soft Coated Wheaten
Terrier

SEX

Spayed Female

AGE

15 Years

WEIGHT

29 Pounds

INTERPRETED BY

Eric Lindquist, DMV
DABVP, Cert. IVUSS

**IMAGING
PERFORMED BY**

Chaley Hunt, LVT

HOSPITAL NAME

Columbia AC

REFERRING VET

Dr. Michelle Engel

INVOICE

33191

DATE

12/2/21

PRESENTING CLINICAL SIGNS

History of elevated liver enzymes, with a jump in them today. Grade 4 dental disease, osteoarthritis, gradual weight loss, no other outward signs of illness. On Galliprant daily, Trazodone occasionally for anxiety.

Abnormal PE/Chem/CBC/UA Results: 3/24/21: ALT = 223, ALKP = 638, UPC = 0.3 12/2/21: ALT = 657, ALKP = 623

ULTRASONOGRAPHIC EXAMINATION OF THE ABDOMEN

Urinary System

The **urinary bladder**, trigone, and pelvic urethra presented normal thicknesses and normal tone. The ureters were not visible which is normal. No uroliths or sediment were visualized and anechoic urine was present. No evidence of inflammatory or neoplastic changes were noted. Ureteral papillae were normal.

The **kidneys** revealed largely normal size and structure, corticomedullary definition and ratio (cortex 1/3 of medulla) were essentially maintained with some age-related loss of curvilinear patterns regarding the capsule and C/M junction. The cortices presented largely uniform texture with some increased echogenicity expected for his age patient. Medullary structure differed distinctly from that of the cortex and no evidence of pelvic dilation was present. The left kidney measured 4.9 cm. The right kidney measured 5.7 cm. Occasional cortical cysts noted in both kidneys.

Adrenal Glands

Both **adrenal glands** were visualized and recognized as having normal shape, size, position and echogenicity for this breed. The phrenic vasculature, glandular echogenicity and detail were unremarkable. Capsule, cortex, and medullary definition were normal for this age patient. The left adrenal gland measured 0.31 cm at the cranial pole and 0.47 cm at the caudal pole.

Spleen

The **spleen** presented a smooth homogeneous parenchyma hyperechoic to liver and renal cortical parenchyma. The capsule was smooth without noticeable expansion or deviation from within the spleen or adjacent pathology. The splenic vasculature demonstrated normal volume without signs of congestion or thrombosis. No sonographic evidence of acute or chronic inflammatory, neoplastic, or infarctual changes were noted.

Liver

The **liver** was non-specific with coarse architecture, increased portal markings, and heterogeneous parenchymal changes. Minor irregular swelling noted to the caudate process. The gallbladder and common bile duct were unremarkable.

Gastrointestinal

Some retention of ingesta was noted in the **stomach**. The small intestine and colon were unremarkable.

Pancreas

The base and limbs of the **pancreas** were observed to be largely isoechoic to surrounding omental fat. Some parenchymal remodeling, however, with mild deviation from curvilinear normalcy was observed. Pancreatic duct and capsular irregularities were present consistent with age related changes. If pain upon imaging (+ Murphy sign) was present or if the patient is focally painful in subxyphoid palpation then low-grade smoldering chronic pancreatitis should be suspected.



PATIENT

Roxie Matthews

ULTRASONOGRAPHIC FINDINGS

- Non-specific chronic inflammatory hepatopathy

SPECIES

Canine

INTERPRETATION OF THE FINDINGS & FURTHER RECOMMENDATIONS

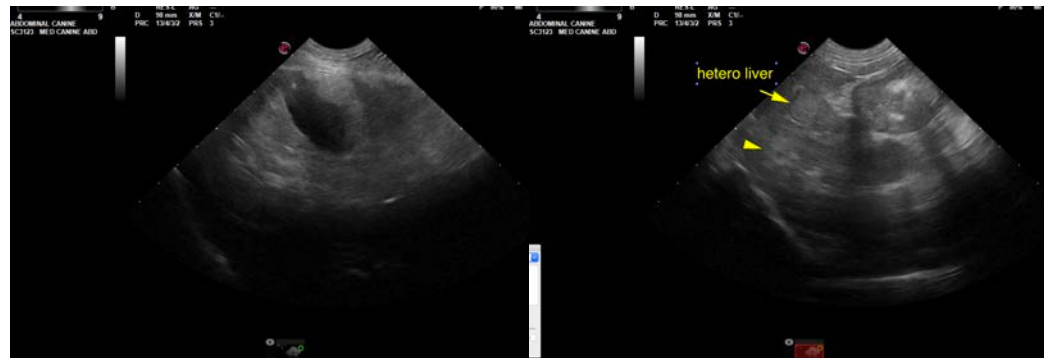
FNA could be considered for further definition of inflammatory cell type. However, core biopsy would be ideal from a surgical, sonographic, or laparoscopy approach for further definition. No overt evidence of neoplasia.

BREED

Soft Coated Wheaten Terrier

SEX

Spayed Female

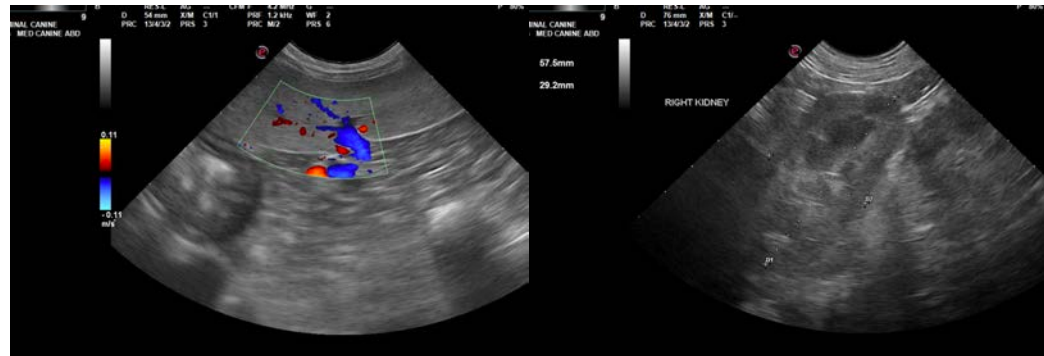


AGE

15 Years

WEIGHT

29 Pounds

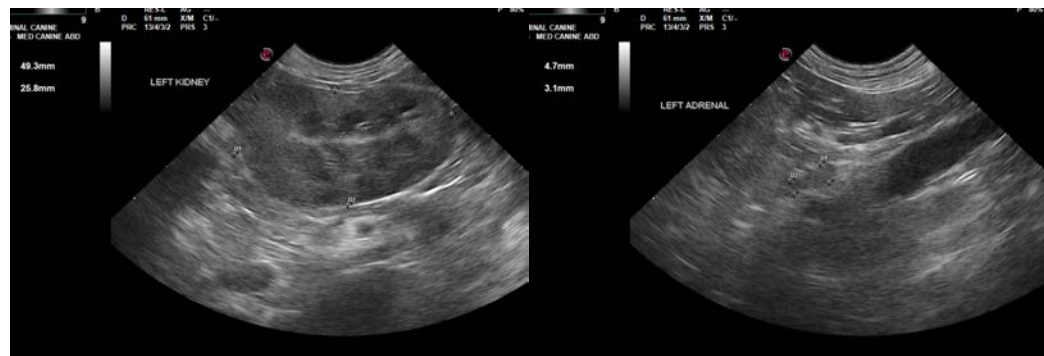

INTERPRETED BY

Eric Lindquist, DMV
DABVP, Cert. IVUSS

IMAGING PERFORMED BY

Chaley Hunt, LVT



HOSPITAL NAME

Columbia AC

REFERRING VET

Dr. Michelle Engel

INVOICE

33191

DATE

12/2/21

The information and recommendations provided are based on the images presented by the referring veterinarian. No evaluation can be communicated regarding pathology that was not visible in the image/video clips provided.

Thank you for this referral. If the clinical or image interpretation does not parallel your findings or if I can be of any further assistance please contact me.

Eric Lindquist, DMV, DABVP, Cert. IVUSS, CEO of SonoPath.com
info@SonoPath.com