



**PATIENT**

Lucy Wells

**SPECIES**

Canine

**BREED**

Lab X

**SEX**

Spayed Female

**AGE**

9 Years

**WEIGHT**

38 Pounds

**INTERPRETED BY**

Eric Lindquist, DMV  
DABVP, Cert. IVUSS

**IMAGING PERFORMED BY**

Dr. Mack

**HOSPITAL NAME**

Northside VC

**REFERRING VET**

Dr. Mack

**INVOICE**

33199

**DATE**

12/2/21

**PRESENTING CLINICAL SIGNS**

Presented on Monday with ataxia. Today Presented fro abs breathing  
Abnormal PE/Chem/CBC/UA Results: Elevated liver enzyme PE noted Ataxia, Bilateral hindlimb hypermetric gait with front limb paresis on Monday put on anti-inflammatory dose of pred Dyspneic, exaggerated inspiration and expiration. On rads diaphragm not expanded appropriately on expiration.

**ULTRASONOGRAPHIC EXAMINATION OF THE ABDOMEN**

**Urinary System**

The **urinary bladder**, trigone, and pelvic urethra presented normal thicknesses and normal tone. The ureters were not visible which is normal. No uroliths or sediment were visualized and anechoic urine was present. No evidence of inflammatory or neoplastic changes were noted. Ureteral papillae were normal.

The **kidneys** revealed normal size and structure, corticomedullary definition and ratio for this age. The cortices presented largely uniform texture with normal echogenic relationship to liver and spleen. Medullary structure differed distinctly from the cortex and no evidence of pelvic dilation was present. The capsules were acceptably uniform without significant irregularities. The right kidney measured 5.0 cm.

**Adrenal Glands**

The **left adrenal gland** was visualized and recognized as having normal shape, size, position and echogenicity for this breed. The phrenic vasculature, glandular echogenicity and detail were unremarkable. Capsule, cortex, and medullary definition were normal for this age patient. The left adrenal gland measured 0.5 cm.

The **right adrenal gland** was mildly heterogeneous and measured 1.0 cm at the cranial pole and 0.5 cm at the caudal pole.

**Spleen**

The **spleen** presented a smooth homogeneous parenchyma hyperechoic to liver and renal cortical parenchyma. The spleen was folded upon itself cranially. The capsule was smooth without noticeable expansion or deviation from within the spleen or adjacent pathology. The splenic vasculature demonstrated normal volume without signs of congestion or thrombosis. No sonographic evidence of acute or chronic inflammatory, neoplastic, or infarctual changes were noted.

**Liver**

The **liver** was uniformly swollen with minor, excessive gallbladder debris and over distension with dependent and suspended bile without evidence of overt mucocele formation. However, excessive sludge was present. The liver presented coarse architecture with mildly increased portal markings and subtle, mixed echogenic changes. This is consistent with vacuolar hepatopathy and some level of remodeling and history of inflammatory component. There was no overt suspicion of neoplasia.

**Gastrointestinal**

Some retention of chyme noted in the **stomach** with overdistention. No evidence of obstruction.



**PATIENT**

**Pancreas**

Lucy Wells

The base and limbs of the **pancreas** were observed to be largely isoechoic to surrounding omental fat. Pancreatic duct and capsular contour were acceptably normal and parenchyma respected normal curvilinear patterns. No overt evidence of active inflammatory or neoplastic disease was noted.

**SPECIES**

Canine

**ULTRASONOGRAPHIC FINDINGS**

- Low-grade inflammatory hepatopathy
- Gastric stasis of unknown cause – possible low-grade gastritis
- Unremarkable abdomen otherwise

**BREED**

Lab X

**INTERPRETATION OF THE FINDINGS & FURTHER RECOMMENDATIONS**

**SEX**

Non-neoplastic presentation. However, the Prednisone therapy may be suppressing a more significant presentation.

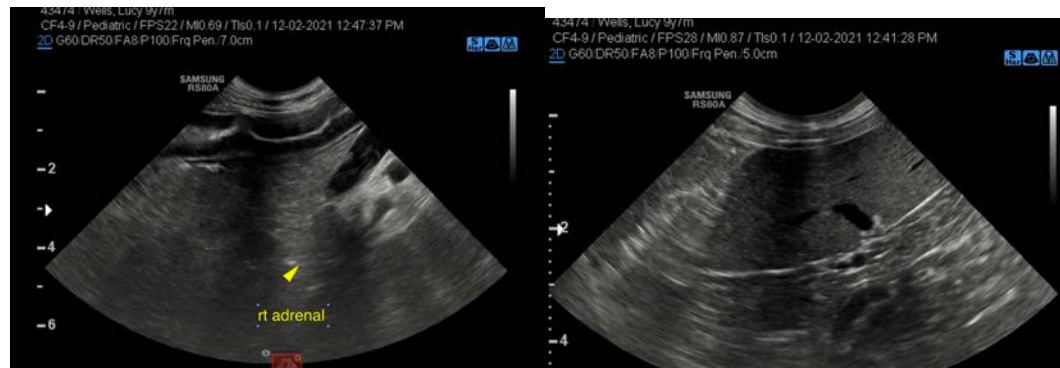
Spayed Female

**AGE**

9 Years

**WEIGHT**

38 Pounds



**INTERPRETED BY**

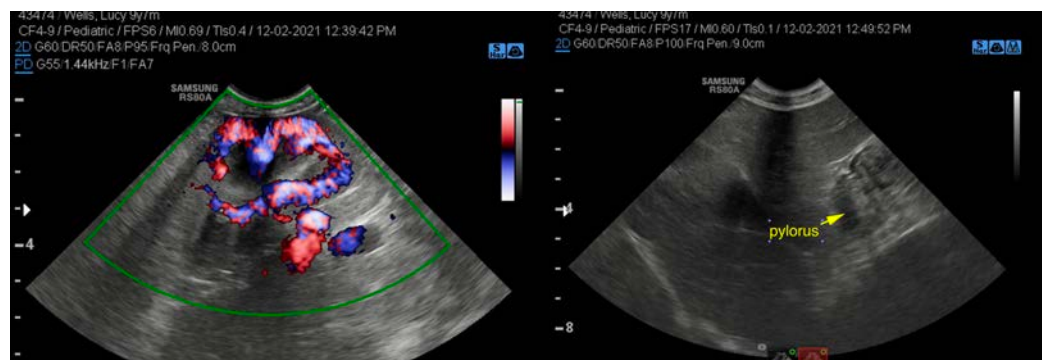
Eric Lindquist, DMV  
DABVP, Cert. IVUSS

**IMAGING PERFORMED BY**

Dr. Mack

**HOSPITAL NAME**

Northside VC



**REFERRING VET**

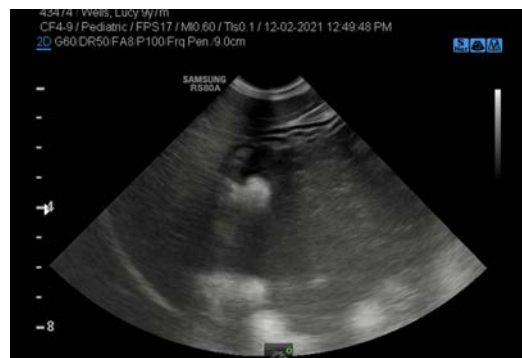Dr. Mack

**INVOICE**

33199

**DATE**

12/2/21





**PATIENT**

Lucy Wells

The information and recommendations provided are based on the images presented by the referring veterinarian. No evaluation can be communicated regarding pathology that was not visible in the image/video clips provided.

**SPECIES**

Canine

Thank you for this referral. If the clinical or image interpretation does not parallel your findings or if I can be of any further assistance please contact me.

**BREED**

Lab X

**Eric Lindquist**, DMV, DABVP, Cert. IVUSS, CEO of SonoPath.com

[info@SonoPath.com](mailto:info@SonoPath.com)

**SEX**

Spayed Female

**AGE**

9 Years

**WEIGHT**

38 Pounds

**INTERPRETED BY**

Eric Lindquist, DMV  
DABVP, Cert. IVUSS

**IMAGING  
PERFORMED BY**

Dr. Mack

**HOSPITAL NAME**

Northside VC

**REFERRING VET**

Dr. Mack

**INVOICE**

33199

**DATE**

12/2/21