



**PATIENT PRESENTING CLINICAL SIGNS**

Jem Callaghan

History: suspect prostatic mass; difficulty voiding urine. on gabapentin 300mg bid, Zeniquin 50mg bid

**SPECIES**

Abnormal PE/Chem/CBC/UA Results: SDMA high 21, BUN 43, ALKP 265; UA: bacteria, protein, RBCs and WBCs present, USPG 1.017

Canine

**BREED**

**ULTRASONOGRAPHIC EXAMINATION OF THE ABDOMEN**  
*Urinary System*

Beagle Mix

The **urinary bladder**, trigone, and pelvic urethra presented normal thicknesses and normal tone. The ureters were not visible which is normal. No uroliths or sediment were visualized and anechoic urine was present. No evidence of inflammatory or neoplastic changes was noted. Ureteral papillae were normal.

**SEX**

Neutered male

The prostate was enlarged and irregular with multi-focal areas of mineralization comprising a mass and measured 3.5 x 2.8 cm. The prostatic mass continued into the caudal aspect of the bladder with polypoid masses occupying the trigone and cystourethral junction as well as the proximal urethra. The post prostatic urethra was invaded by proliferative tissue.

**AGE**

11 years

The **kidneys** revealed largely normal size and structure, corticomedullary definition and ratio (cortex 1/3 of medulla) were essentially maintained with some age-related loss of curvilinear patterns regarding the capsule and C/M junction. The cortices presented largely uniform texture with some increased echogenicity expected for this age patient. Medullary structure differed distinctly from that of the cortex and no evidence of pelvic dilation was present. The right kidney measured 6.67 cm. The left kidney measured 6.0 cm.

**WEIGHT**

47 lbs

**INTERPRETED BY**

Eric Lindquist, DMV  
DABVP, Cert. IVUSS

**Adrenal Glands**

The left adrenal gland was uniform and measured 1.85 x 0.54 cm at the caudal pole and 0.5 cm at the cranial pole. The right adrenal gland was slightly swollen at the cranial pole measuring 1.23 cm. The caudal pole measured 0.61 cm and 1.99 cm in length.

**IMAGING PERFORMED BY**

Diane McFadden, RVT

**HOSPITAL NAME**

Shohola VH

**Spleen**

The **spleen** presented a smooth homogeneous parenchyma hyperechoic to liver and renal cortical parenchyma. The capsule was smooth without noticeable expansion or deviation from within the spleen or adjacent pathology. The splenic vasculature demonstrated normal volume without signs of congestion or thrombosis. No sonographic evidence of acute or chronic inflammatory, neoplastic, or infarctual changes was noted.

**INVOICE**

94287

**DATE**

12/2/21

**Liver**

The **liver** images submitted revealed subjectively normal liver size, contour, and structure. Parenchymal echogenicity was naturally coarse and hypoechoic to the spleen. Vascular and biliary tracts were of normal volume with no evidence of congestion. The gallbladder presented acceptably thin walls with primarily anechoic content. The cystic and common bile ducts were normal. No pathological hepatic



**PATIENT**

Jem Callaghan

lymphadenopathy was evident. No overt structural evidence of inflammatory, infiltrative or regenerative pathology was evident.

**SPECIES**

Canine

**Gastrointestinal**

Examination of the **gastrointestinal tract** revealed a stomach and intestine free of stasis, of normal wall thickness, acceptable curvilinear mural detail, and peristaltic activity. Small and large intestine demonstrated normal luminal chyme and stool consistency respectively. No obstructive or overt infiltrative disease was noted. No associated abnormal lymphatic activity was noted.

**BREED**

Beagle Mix

**SEX**

Neutered male

**Pancreas**

The base and limbs of the **pancreas** were observed to be largely isoechoic to surrounding omental fat. Pancreatic duct and capsular contour were acceptably normal and parenchyma respected normal curvilinear patterns. No overt evidence of active inflammatory or neoplastic disease was noted.

**AGE**

11 years

**ULTRASONOGRAPHIC FINDINGS**

Urethral and post prostatic mass.

**WEIGHT**

47 lbs

**INTERPRETATION OF THE FINDINGS & FURTHER RECOMMENDATIONS**

Traumatic catheterization or ultrasound-guided FNA of the prostatic mass could be considered. However, there is some risk for tumor trailing. Referral for urethral stent placement and chemotherapeutic intervention is recommended.

**INTERPRETED BY**

Eric Lindquist, DMV  
DABVP, Cert. IVUS

**IMAGING PERFORMED BY**

Diane McFadden, RVT

**HOSPITAL NAME**

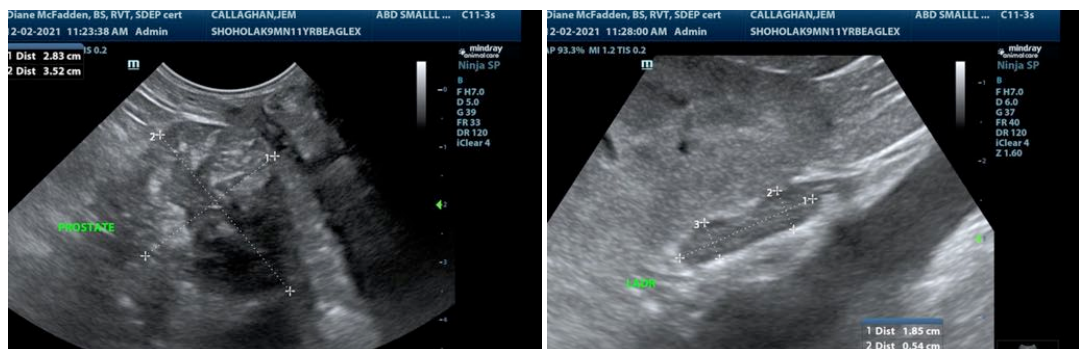
Shohola VH

**INVOICE**

94287

**DATE**

12/2/21





**PATIENT**

Jem Callaghan

**SPECIES**

Canine

**BREED**

Beagle Mix

**SEX**

Neutered male

**AGE**

11 years

**WEIGHT**

47 lbs

**INTERPRETED BY**

Eric Lindquist, DMV  
DABVP, Cert. IVUSS

**IMAGING  
PERFORMED BY**

Diane McFadden, RVT

**HOSPITAL NAME**

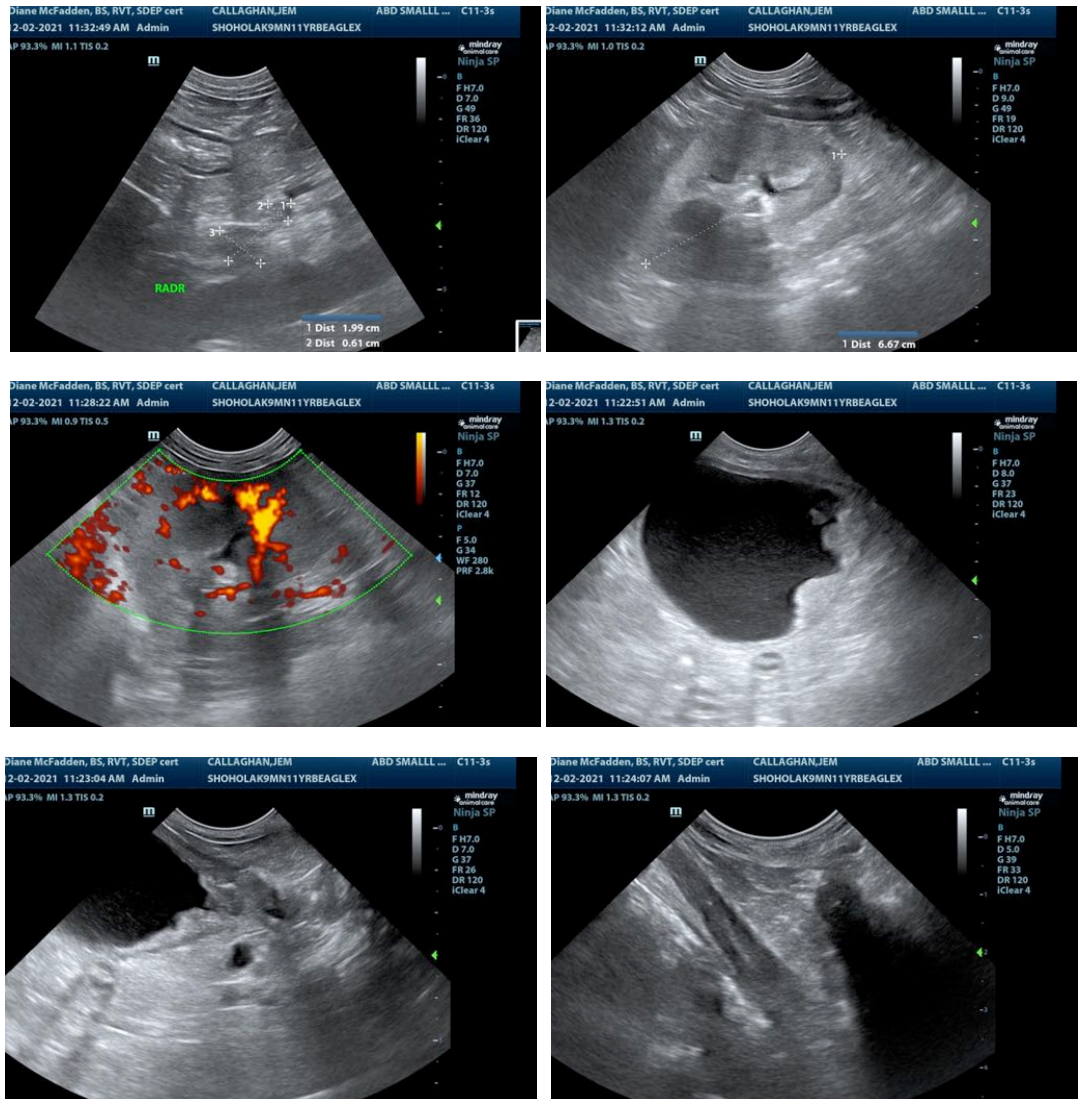
Shohola VH

**INVOICE**

94287

**DATE**

12/2/21



The information and recommendations provided are based on the images presented by the referring veterinarian. No evaluation can be communicated regarding pathology that was not visible in the image/video clips provided.


Thank you for this referral. If the clinical or image interpretation does not parallel your findings or if I can be of any further assistance please contact me.

**Eric Lindquist, DMV, DABVP, Cert. IVUSS, CEO of SonoPath.com**  
Info@SonoPath.com



**PATIENT**

Jem Callaghan



The following is an applicable excerpt from the *Curbside Guide to Diagnosis & Treatment of Sonographic Disease* offered by [SonoPath.com](http://sonopath.com) Lindquist, Frank, Lobetti, and Modler.

**SPECIES**

Canine

An essential quick guide for every general practitioner and sonographer.

<https://sonopath.com/products/curbside-guide-editing-due-release-12012015>

**BREED**

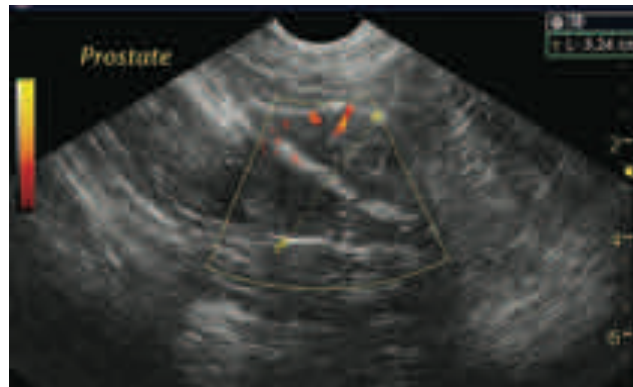Beagle Mix

**Canine Prostatic Neoplasia**

<http://www.sonopath.com/ProstaticCarcinoma>

**SEX**

Neutered male



Long axis of the prostate in a neutered male dog with prostatic carcinoma. The prostatic gland (between calipers) is significantly enlarged. Multiple hyperechoic foci consistent with mineralization are seen. Note the low echogenicity of the prostatic parenchyma rendering the urethral pathway relatively hyperechoic. Also note the presence of power Doppler signal in the organ periphery which is not seen in normal prostatic glands and benign prostatic hyperplasia.

**AGE**

11 years

**WEIGHT**

47 lbs

**INTERPRETED BY**

Eric Lindquist, DMV  
DABVP, Cert. IVUSS

**Description:** Prostatic neoplasia is frequently seen in dogs and can be diagnosed via ultrasonographic examination. The most commonly diagnosed prostatic neoplasms are adenocarcinoma and undifferentiated carcinoma. Transitional cell carcinoma (TCC) frequently spreads from the urinary bladder and urethra to the prostatic tissue (see the “Transitional Cell Carcinoma” chapter for more details). Metastatic squamous cell carcinoma, lymphoma, hemangiosarcoma, and leiomyosarcoma have been reported, but are less prevalent. Prostatic neoplasia has been documented in cats, but is quite rare.

**IMAGING PERFORMED BY**

Diane McFadden, RVT

**HOSPITAL NAME**

Shohola VH

**Clinical Signs:** Prostatic neoplasia presents in both neutered and intact males; however, a 2002 study suggested that neutered males were at greater risk for developing prostatic neoplasia than intact males. Typically, prostatic neoplasia is seen in older dogs (mean age of 10 years). Breed predilection includes mixed breed dogs, Shetland Sheepdogs, Dobermans, Scottish Terriers, and Airedale Terriers. Clinical signs and commonly reported signs from owners typically include: stranguria, frequent urinations, hematuria, dyschezia, weight loss, and decreased appetite. Other findings upon physical examination include fever, ataxia, pain upon rectal examination, and pain upon spinal palpation.

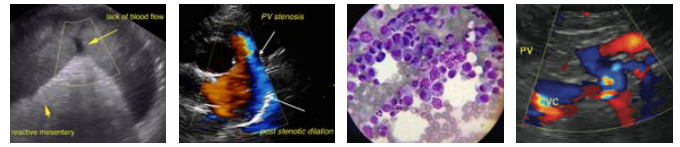
**INVOICE**

94287

**DATE**

12/2/21

**Diagnostics:** Ultrasonographic examination should be performed if prostatic neoplasia is suspected. Common ultrasonographic findings include an enlarged, irregular prostate that typically has a hypoechoic appearance. Multifocal, poorly coalescing hyperechoic foci are also seen in prostatic malignancies. Hyperechoic foci are due to mineralization of the prostate; they cause far field shadowing. Cystic components can also be observed and are thought to indicate abscessation and/or necrosis. It



**PATIENT**

Jem Callaghan

can be difficult to differentiate chronic bacterial prostatitis from a prostatic neoplasia; however, regional lymphadenopathy is much more common with prostatic neoplasia than it is with chronic bacterial prostatitis. Malignancies of the prostate have often metastasized by the time of diagnosis. Frequent sites of metastases include the sublumbar lymph nodes, the pelvis, lumbar vertebrae, and the lungs. If metastases to the pelvis or lumbar vertebrae have occurred, bony lysis will often be noted radiographically. Metastasis to the liver, brain, kidney and spleen may occur. A definitive diagnosis of a prostatic neoplasm can be achieved through biopsy as well as fine needle aspiration (FNA) or through ultrasound-guided traumatic catheterization.

**SPECIES**

Canine

**BREED**

Beagle Mix

A complete and thorough workup includes a CBC, biochemical profile, urinalysis, as well as three radiographic views of the thorax, an abdominal ultrasound, and an ultrasound-guided prostatic biopsy or FNA, if indicated. Urinalysis may reveal hematuria and pyuria. Prostatic fluid analysis can also be helpful in identifying neoplastic cells.

**SEX**

Neutered male

**AGE**

11 years

**Treatment:** Unfortunately, once diagnosed, prostatic carcinoma offers a poor prognosis; prostatectomy, chemotherapy, and radiation therapy have proven unsuccessful in improving quality or length of life. Nonsteroidal anti-inflammatory drugs (NSAIDs), such as deracoxib, meloxicam, and piroxicam, have been used for their palliative, anti-neoplastic properties with prostatic carcinomas. Certain tumors, including various carcinomas (e.g. TCC, prostatic carcinoma, mammary carcinoma, squamous cell carcinoma) overexpress COX-2, which converts arachidonic acid to prostaglandin G2 (PGG2)/prostaglandin H2 (PGH2), and ultimately to prostaglandin E<sub>2</sub> (PGE<sub>2</sub>). The metabolite, PGE<sub>2</sub>, is associated with increased inflammation, tumor invasiveness, angiogenesis, and reduced apoptosis. In vivo and in vitro, NSAIDs inhibit COX-2, resulting in the suppression of PGE<sub>2</sub>, and thereby inhibiting tumor growth and metastasis. This effect has been achieved with both non-selective COX inhibitors as well as COX-2 inhibitors (the latter will suppress COX-1 at increased doses).

**WEIGHT**

47 lbs

**INTERPRETED BY**

Eric Lindquist, DMV  
DABVP, Cert. IVUSS

Some cases of prostatic carcinoma are managed palliatively with cyst/abscess ultrasound-guided drainage, antibiotic infusion, systemic antibiotics, and NSAID treatment and/or chemotherapy. Anecdotally, it has been observed that patients that often present clinical signs of hematuria or dysuria owing to cyst or abscess formation may be treated with repeat ultrasound-guided drainage. This appears to work especially well if there is a considerable cystic component to the prostatic tumor. The key is to image the prostate adequately, drain any cysts that are present, sample the abnormal parenchyma (FNA or biopsy), and potentially infuse antibiotics directly into the cystic cavities if a suppurative fluid is retrieved. The patient should be monitored clinically over time and reevaluated to see if cysts recur. Every case responds differently to treatment, and the behavior of parenchymal and cystic growth will vary.

**IMAGING PERFORMED BY**

Diane McFadden, RVT

**HOSPITAL NAME**

Shohola VH

**INVOICE**

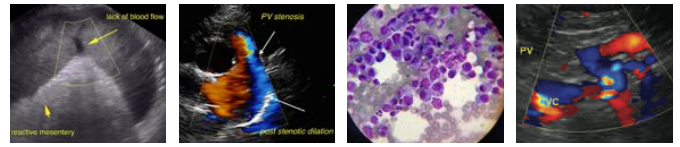
94287

**DATE**

12/2/21

Currently, investigational studies involving fluoroscopic-guided direct chemotherapeutic embolization through the iliac arteries as well as urethral stent placement are offered by select tertiary veterinary facilities that have an interventional radiology department. Ultrasound-guided endoscopic diode laser ablation through a perineal urethrostomy is also being attempted as a salvage and palliative procedure.

**Conclusion:** Prostatic neoplasia is more commonly detected in neutered male dogs than intact males. Diagnosis is typically obtained using ultrasound, cytology, and histopathology. Unfortunately, traditional therapy typically yields a guarded to poor long-term prognosis, but palliation with NSAIDs



**PATIENT**

Jem Callaghan

and/or chemotherapy can temporarily improve clinical signs. Investigational techniques may provide additional therapeutic options but are currently experimental.

**SPECIES**

Canine

**BREED**

Beagle Mix

**SEX**

Neutered male

**AGE**

11 years

**WEIGHT**

47 lbs

**INTERPRETED BY**

Eric Lindquist, DMV  
DABVP, Cert. IVUSS

**IMAGING PERFORMED BY**

Diane McFadden, RVT

**HOSPITAL NAME**

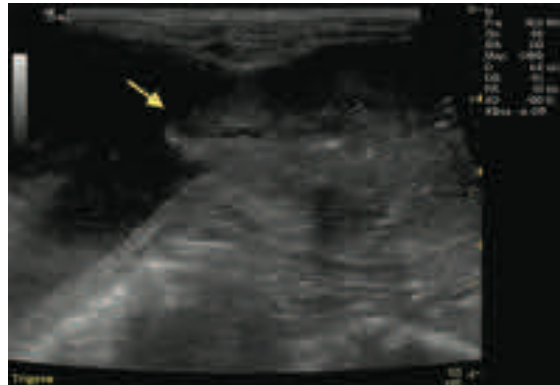
Shohola VH

**INVOICE**

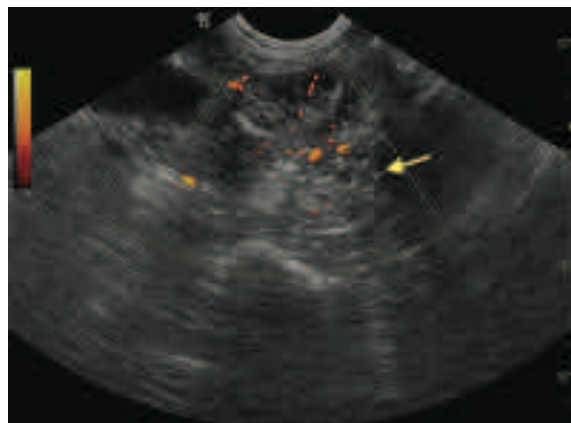94287

**DATE**

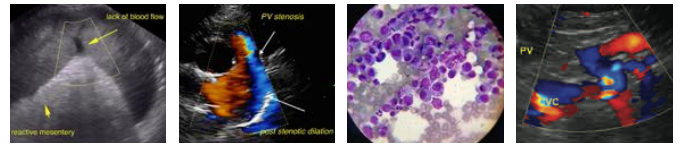
12/2/21



Long axis of the prostate in a dog with prostatic carcinoma with cystourethral junction to the left. Note the typical "starry sky" pattern of prostatic carcinoma with multiple echogenic foci representing mineralizations (arrow) on a relatively hypoechoic background created by the neoplastic infiltrate. Considerable vascularity is present throughout the parenchyma noted on power Doppler.



Long axis of the prostate in a dog with prostatic carcinoma during ultrasound guided sampling. The prostatic mass is largely isoechoic to surrounding fat in this particular example and can easily be missed without correct gain and focal point adjustments. The needle trajectory is seen as a weakly echogenic interface (arrowheads). Note the echo yield is limited technically by the steep insonation angle here. Note the sharp deviation of the descending colon owing to the prostatic mass effect upon it (arrow). This colonic deviation was a key point toward identifying this isoechoic prostatic mass in this case.



**PATIENT**

Jem Callaghan

**SPECIES**

Canine

**BREED**

Beagle Mix

**SEX**

Neutered male

**AGE**

11 years

**WEIGHT**

47 lbs

**INTERPRETED BY**

Eric Lindquist, DMV  
DABVP, Cert. IVUSS

**IMAGING PERFORMED BY**

Diane McFadden, RVT

**HOSPITAL NAME**

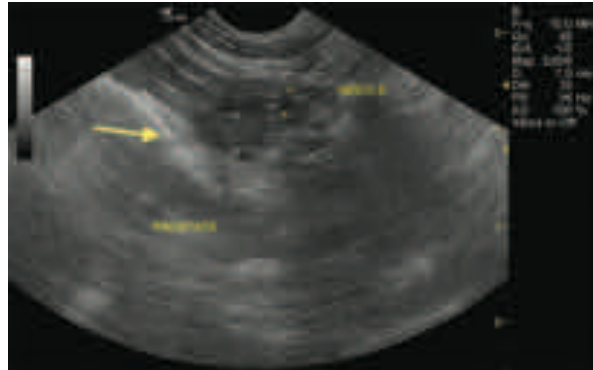Shohola VH

**INVOICE**

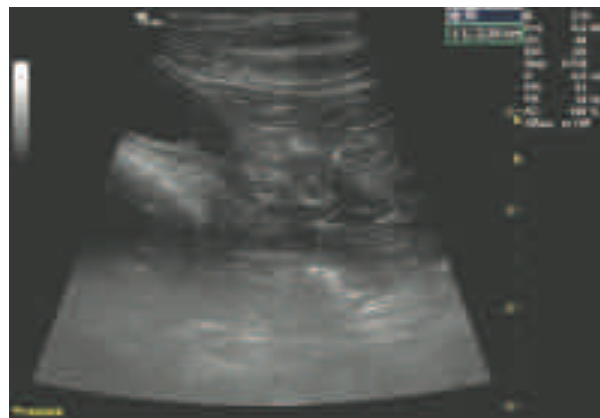94287

**DATE**

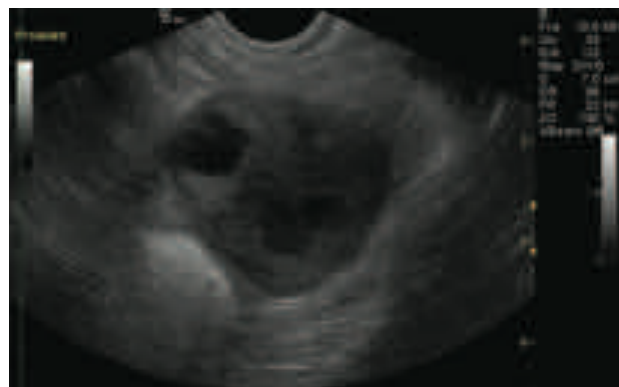12/2/21



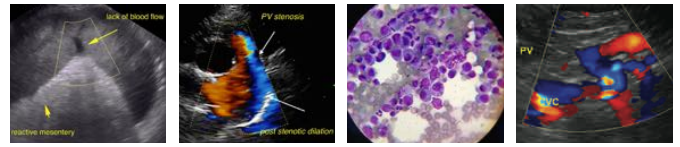
Long axis of the prostate in a dog with prostatic carcinoma during ultrasound guided sampling. The prostatic mass is largely isoechoic to surrounding fat in this particular example and can easily be missed without correct gain and focal point adjustments. The needle trajectory is seen as a weakly echogenic interface (arrowheads). Note the echo yield is limited technically by the steep insonation angle here. Note the sharp deviation of the descending colon owing to the prostatic mass effect upon it (arrow). This colonic deviation was a key point toward identifying this isoechoic prostatic mass in this case.



Long axis of the prostate in a neutered male dog with prostatic carcinoma. Note that prostatic carcinomas are not necessarily large and commonly similar in echogenicity and echotexture as compared to the surrounding peritoneal fat. Proper scanning technique tracing the bladder neck and urethra is essential not to miss the lesion.



Short axis of the prostate in a dog with cystic prostatic carcinoma. Multifocal intraparenchymal cyst-like lesions with anechoic to hypoechoic content are seen. Asymmetric enlargement is noted. The regular bilobed shape and typical dorsal notch are lost. The echotexture in this particular prostatic mass is reminiscent of the occasional prostatic lymphoma that can occur as exemplified in the next image.



**PATIENT**

Jem Callaghan

**SPECIES**

Canine

**BREED**

Beagle Mix

**SEX**

Neutered male

**AGE**

11 years

**WEIGHT**

47 lbs

**INTERPRETED BY**

Eric Lindquist, DMV  
DABVP, Cert. IVUSS

**IMAGING PERFORMED BY**

Diane McFadden, RVT

**HOSPITAL NAME**

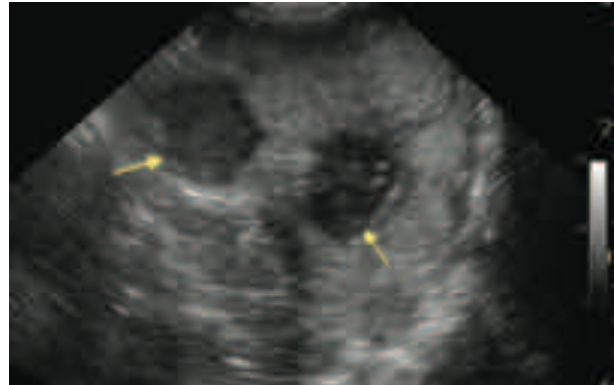
Shohola VH

**INVOICE**

94287

**DATE**

12/2/21



Cross section of the prostate in a dog with enlarged irregular prostate. The regular parenchymal echoarchitecture is displaced by two well delineated hypoechoic nodules (arrows). Note the generalized swelling of the gland. The sonographic appearance resembles prostatitis and abscessation, yet the diagnosis was significantly different on USG FNA (prostatic lymphoma). Note: abscessation can be differentiated from proliferative nodules with power Doppler as signals are negative with abscessation or necrosis and typically positive with tissue proliferation.

**References:**

Cerf DJ, Lindquist EC. Palliative ultrasound-guided endoscopic laser ablation of transitional cell carcinomas of the lower urinary tract in dogs. *J Am Vet Med Assoc* 2012;240(1):51-60.

Culp, WTN. Interventional oncology and the management of urinary tract cancer. Proceedings from the American College of Veterinary Internal Medicine, New Orleans, LA, May 30-June 2, 2012.

Francey T. Prostatic Diseases. In: Ettinger SJ, Feldman EC, eds. *Textbook of Veterinary Internal Medicine 7th ed.* Philadelphia, PA: WB Saunders; 2010:2047-58.

Hecht S. Male Reproductive Tract. In: Pennick D, D'Anjou MA, eds. *Atlas of Small Animal Ultrasonography.* Ames, IA: Blackwell Publishing; 2008:417-43.

Milner RJ. Do NSAIDs make a difference in cancer. Proceedings from the American College of Veterinary Internal Medicine, Denver, CO, June 15-18, 2011.

Mohammed SI, Khan KN, Sellers RS, et al. Expression of cyclooxygenase-1 and 2 in naturally-occurring canine cancer. *Prostag Leukotr Ess* 2004;70(5):479-83.

Nyland, TG, Mattoon JS. *Small Animal Diagnostic Ultrasound 2nd ed.* Philadelphia, PA: WB Saunders; 2002:250-66.

Sorenmo KU, Goldschmidt MH, Shofer FS, et al. Evaluation of cyclooxygenase-1 and cyclooxygenase-2 expression and the effect of cyclooxygenase inhibitors in canine prostatic carcinoma. *Vet Comp Oncol* 2004;2(1):13-23.