



PATIENT PRESENTING CLINICAL SIGNS

Jack Hirst Vomiting and excessive appetite
 Abnormal PE/Chem/CBC/UA Results: WNL, T4:2.4

SPECIES ULTRASONOGRAPHIC EXAMINATION OF THE HEART & ABDOMEN

Feline

BREED

DSH

SEX

Neutered Male

AGE

11 Years

WEIGHT

8.9 Pounds

FELINE CARDIAC PARAMETERS	BODY WEIGHT (kg)	HR (BPM)	IVSd (cm)	LVIDd (cm)	LVWd (cm)	FS (%)	EF (%)
NORMAL PARAMETER	-----	150-240	0.3-0.6	1.0-2.1	0.25-0.6	35-67	80-100
PATIENT		NM		1.53		79	98
FELINE CARDIAC PARAMETERS	LA/AO (Boon)	LA/AO HEART BASE (Sisson)	LA 2D 4-chamber long axis AS to FW (Sisson) (cm)		LVOT VEL. (m/s)	RVOT VEL. (m/s)	IVRT (m/)
NORMAL PARAMETER	<1.5	0.88-1.79	0.7-1.7		<1.6	<1.3	40-60
PATIENT			1.32		1.5	1.1	NM

Adapted from June Boon, Veterinary Echocardiography, 1998
 Sisson D et al. JVIM 1991; 5: 232, Jacobs et al. Am J Vet Res 1985; 46:1705

Cardiac Presentation

The echocardiogram in this patient demonstrated normal **left atrial** size based on 3 separate methods of LA evaluation. The cranial and caudal **mitral valve** leaflets presented normal linear structure, extension in systole, and union in diastole with normal kinesis. The **left ventricle** presented thicknesses with linear contour and was not dilated nor restricted. The **myocardium** presented normal echogenicity without subjective evidence of significant fibrotic or ischemic disease. **Contractility** of the ventricular walls was adequate and in normal range for this patient evidenced by the fractional shortening measurement and subjective evaluation of the different regions of the myocardium. The **left ventricular outflow** tract demonstrated normal laminar flow and subjective structural integrity. The **right atrium** and auricle revealed normal size, structure and content. No evidence of masses was noted. **Tricuspid** valvular assessment demonstrated adequate linear morphology and kinesis. The **right ventricle** was of normal size (1/3 diameter of LV), chordae structure, myocardial echogenicity and thickness. **Pulmonary outflow** tract assessment revealed normal valve structure, laminar flow, and diameter (approx. 1:1 pa/ao ratio). No visible **pericardial** or free pleura fluid was noted. The cranial **mediastinum and pericardial and extra-cardiac regions** were free of masses in the visible window.

Urinary System

The **urinary bladder**, trigone, and pelvic urethra presented normal thicknesses and normal tone. The ureters were not visible which is normal. No uroliths or sediment were visualized and anechoic urine was present. No evidence of inflammatory or neoplastic changes were noted. Ureteral papillae were normal.

The **kidneys** revealed normal size and structure, corticomedullary definition and ratio for this age. The cortices presented largely uniform texture with normal echogenic relationship to liver and spleen. Medullary structure differed distinctly from the cortex and no evidence of pelvic dilation was present.

INTERPRETED BY

Eric Lindquist, DMV
 DABVP, Cert. IVUSS

IMAGING PERFORMED BY

Dr. Rodriguez

HOSPITAL NAME

Foxfield Vet Services

REFERRING VET

Dr. Rodriguez

INVOICE

33193

DATE

12/2/21



PATIENT

Jack Hirst

The capsules were acceptably uniform without significant irregularities. The left kidney measured 3.85 cm.

Adrenal Glands

SPECIES

Feline

The regions of the **adrenal glands** were unremarkable.

Spleen

BREED

DSH

The **spleen** presented a smooth homogeneous parenchyma hyperechoic to liver and renal cortical parenchyma. The capsule was smooth without noticeable expansion or deviation from within the spleen or adjacent pathology. The splenic vasculature demonstrated normal volume without signs of congestion or thrombosis. No sonographic evidence of acute or chronic inflammatory, neoplastic, or infarctual changes were noted.

SEX

Neutered Male

Liver

The **liver** images submitted revealed subjectively normal liver size, contour, and structure. Parenchymal echogenicity was naturally coarse and hypoechoic to the spleen. Vascular and biliary tracts were of normal volume with no evidence of congestion. The gallbladder presented acceptably thin walls with primarily anechoic content. The cystic and common bile ducts were normal. No pathological hepatic lymphadenopathy was evident. No overt structural evidence of inflammatory, infiltrative or regenerative pathology was evident.

WEIGHT

8.9 Pounds

Gastrointestinal

The **gastrointestinal** presentation revealed mild uniform prominence of the gastric mucosa as well as areas of "ropy" small intestinal wall with slight disruption of the normal 1:3 muscularis/mucosal ratio. The intestinal submucosa was slightly irregular, thickened and hyperechoic suggestive of low grade, chronic disease. No concerning lymphadenopathy was visible. No evidence of obstruction was present. Chronic inflammatory bowel disease is likely with a low possibility of an early neoplastic event such as lymphoma. Full thickness tissue biopsies via open laparotomy, ideally guided by intraoperative ultrasound in order to obtain the most representative mural sample, would be necessary to rule out this possibility.

INTERPRETED BY

Eric Lindquist, DMV
DABVP, Cert. IVUSS

IMAGING PERFORMED BY

Dr. Rodriguez

Pancreas

The base and limbs of the **pancreas** were observed to be largely isoechoic to surrounding omental fat. Pancreatic duct and capsular contour were acceptably normal and parenchyma respected normal curvilinear patterns. No overt evidence of active inflammatory or neoplastic disease was noted.

HOSPITAL NAME

Foxfield Vet Services

ULTRASONOGRAPHIC FINDINGS

- IBD GI pattern
- Unremarkable abdomen otherwise

REFERRING VET

Dr. Rodriguez

INTERPRETATION OF THE FINDINGS & FURTHER RECOMMENDATIONS

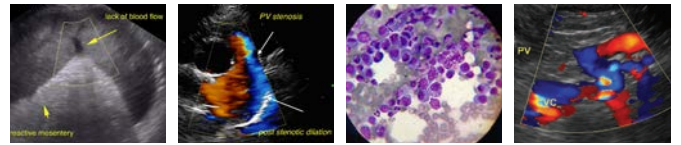
Malassimilation may be an issue in this patient if there is any weight loss.

INVOICE

33193

DATE

12/2/21



PATIENT

Jack Hirst

SPECIES

Feline

BREED

DSH

SEX

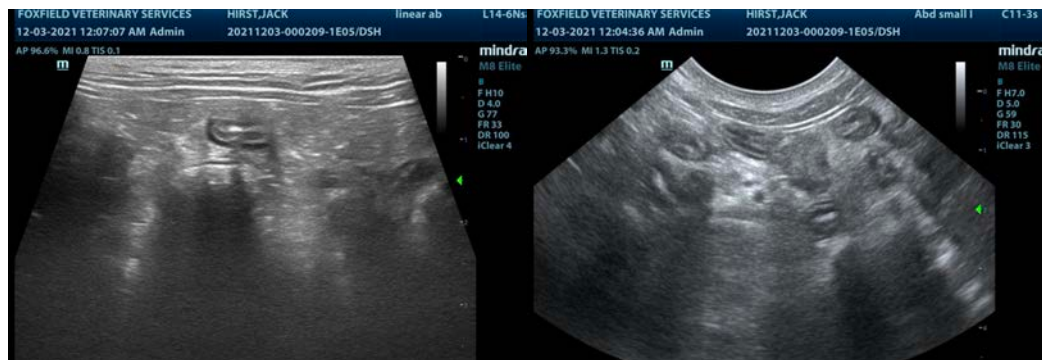Neutered Male

AGE

11 Years

WEIGHT

8.9 Pounds



SEX

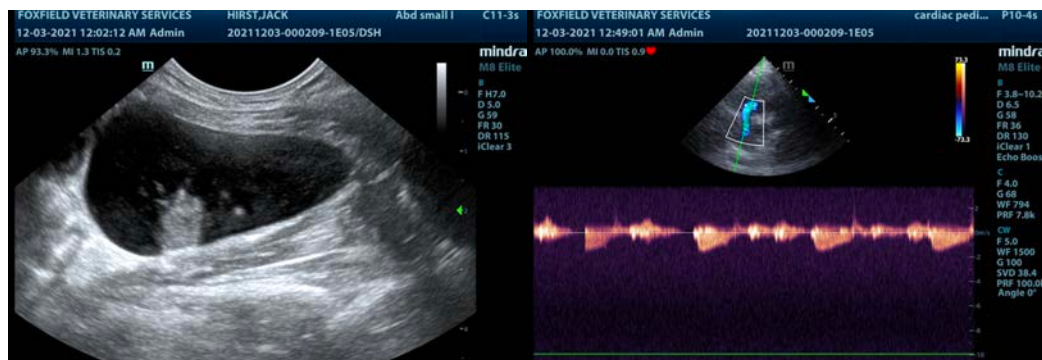
Neutered Male

AGE

11 Years

WEIGHT

8.9 Pounds



INTERPRETED BY

Eric Lindquist, DMV
DABVP, Cert. IVUSS

IMAGING PERFORMED BY

Dr. Rodriguez

HOSPITAL NAME

Foxfield Vet Services

REFERRING VET

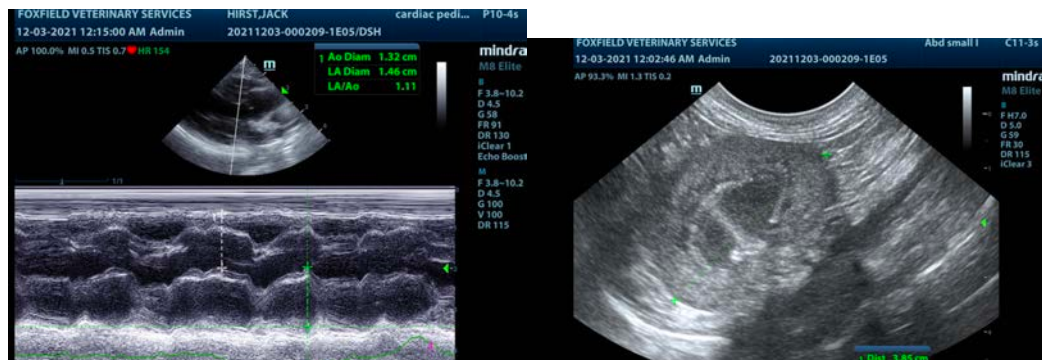
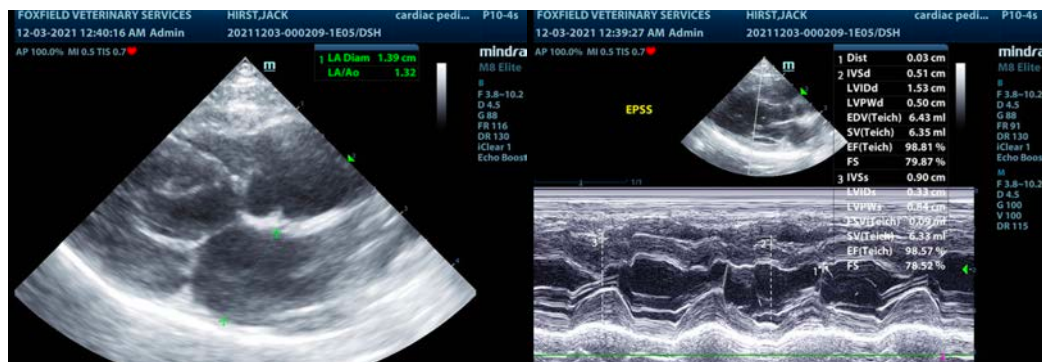
Dr. Rodriguez

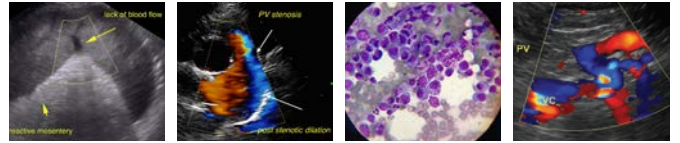
INVOICE

33193

DATE

12/2/21





PATIENT

Jack Hirst

The information and recommendations provided are based on the images presented by the referring veterinarian. No evaluation can be communicated regarding pathology that was not visible in the image/video clips provided.

SPECIES

Feline

Thank you for this referral. If the clinical or image interpretation does not parallel your findings or if I can be of any further assistance please contact me.

BREED

DSH

Eric Lindquist, DMV, DABVP, Cert. IVUSS, CEO of SonoPath.com

info@SonoPath.com

SEX

Neutered Male

AGE

11 Years

WEIGHT

8.9 Pounds

INTERPRETED BY

Eric Lindquist, DMV
DABVP, Cert. IVUSS

**IMAGING
PERFORMED BY**

Dr. Rodriguez

HOSPITAL NAME

Foxfield Vet Services

REFERRING VET

Dr. Rodriguez

INVOICE

33193

DATE

12/2/21