



PATIENT PRESENTING CLINICAL SIGNS

Charlie Held GB DZ AND HEPATOMEGALY (SEE LASY AUS) TODAY V/D , BW--> SEVERE PANCREATITIS,ALL ELSE WNL

SPECIES ULTRASONOGRAPHIC EXAMINATION OF THE ABDOMEN

Canine

Urinary System

BREED

Yorkshire Terrier

The **urinary bladder**, trigone, and pelvic urethra presented normal thicknesses and normal tone. The ureters were not visible which is normal. No uroliths or sediment were visualized and anechoic urine was present. No evidence of inflammatory or neoplastic changes were noted. Ureteral papillae were normal.

SEX

Neutered Male

The **kidneys** revealed largely normal size and structure, corticomedullary definition and ratio (cortex 1/3 of medulla) were essentially maintained with some age-related loss of curvilinear patterns regarding the capsule and C/M junction. The cortices presented largely uniform texture with some increased echogenicity expected for his age patient. Medullary structure differed distinctly from that of the cortex and no evidence of pelvic dilation was present. The right kidney measured 4.63 cm. The left kidney measured 4.7 cm.

AGE

13 Years

Adrenal Glands

WEIGHT

15.5 Pounds

Both **adrenal glands** were visualized and recognized as having normal shape, size, position and echogenicity for this breed. The phrenic vasculature, glandular echogenicity and detail were unremarkable. Capsule, cortex, and medullary definition were normal for this age patient. The left adrenal gland measured 0.5 cm.

INTERPRETED BY

Eric Lindquist, DMV
DABVP, Cert. IVUSS

Spleen

The **spleen** revealed a focal mass measuring 2.0 cm. This may represent round cell neoplasia, hemangiosarcoma, or possible abscessation. Splenectomy recommended.

IMAGING PERFORMED BY

Dr. Ohad Barnea

Liver

The **liver** presented a uniform vacuolar hepatopathy pattern with generalized enlargement. Increased portal markings noted, consistent with remodeling. Minor gallbladder debris noted.

HOSPITAL NAME

Tenafly Vet Center

Gastrointestinal

Examination of the **gastrointestinal tract** revealed a stomach and intestine free of stasis, of normal wall thickness, acceptable curvilinear mural detail, and peristaltic activity. Small and large intestine demonstrated normal luminal chyme and stool consistency respectively. No obstructive or overt infiltrative disease was noted. No associated abnormal lymphatic activity was noted.

REFERRING VET

Dr. Ohad Barnea

Pancreas

The **pancreas** was uniform with minor remodeling. No evidence of significant disease.

INVOICE

33198

ULTRASONOGRAPHIC FINDINGS

- Splenic mass
- Benign hepatopathy with mild remodeling
- Pancreatic remodeling

DATE

12/2/21



PATIENT

Charlie Held

SPECIES

Canine

BREED

Yorkshire Terrier

SEX

Neutered Male

AGE

13 Years

WEIGHT

15.5 Pounds

INTERPRETED BY

Eric Lindquist, DMV
DABVP, Cert. IVUSS

IMAGING PERFORMED BY

Dr. Ohad Barnea

HOSPITAL NAME

Tenafly Vet Center

REFERRING VET

Dr. Ohad Barnea

INVOICE

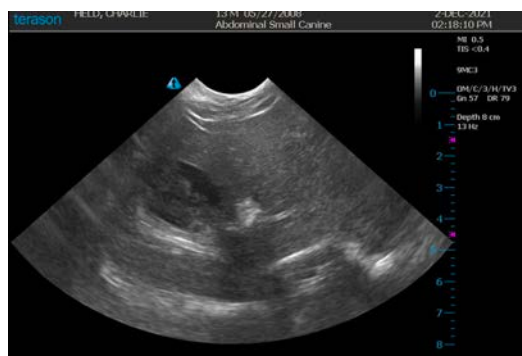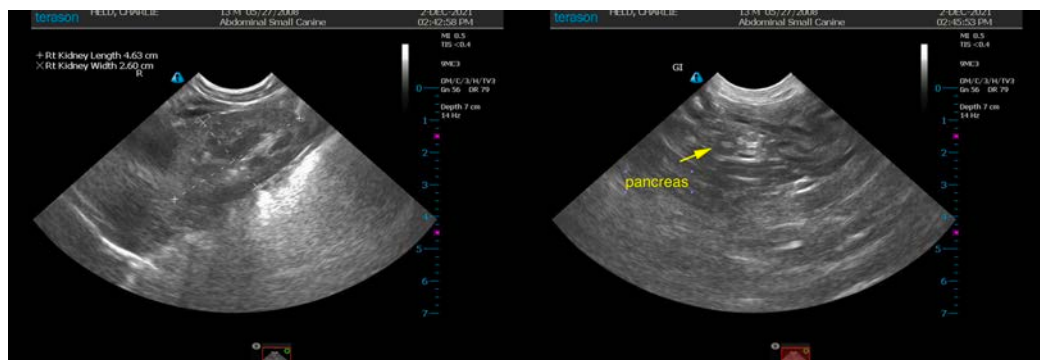
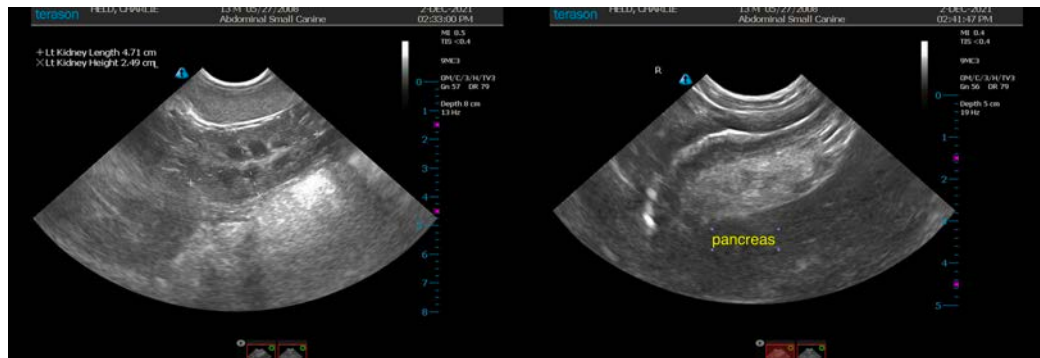
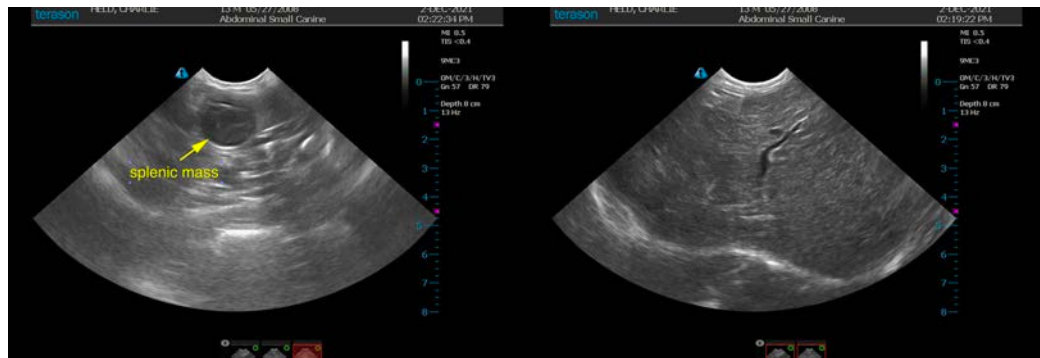
33198

DATE

12/2/21

INTERPRETATION OF THE FINDINGS & FURTHER RECOMMENDATIONS

No obvious evidence of metastatic disease. Rapid echocardiogram recommended to assess for metastasis to the right auricle or pericardium as well as 3-view chest radiographs. Splenectomy, liver biopsy and gastric biopsy indicated, yet structurally the GI tract is unremarkable.





PATIENT

Charlie Held

The information and recommendations provided are based on the images presented by the referring veterinarian. No evaluation can be communicated regarding pathology that was not visible in the image/video clips provided.

SPECIES

Canine

Thank you for this referral. If the clinical or image interpretation does not parallel your findings or if I can be of any further assistance please contact me.

BREED

Yorkshire Terrier

Eric Lindquist, DMV, DABVP, Cert. IVUSS, CEO of SonoPath.com

info@SonoPath.com

SEX

Neutered Male

AGE

13 Years

WEIGHT

15.5 Pounds

INTERPRETED BY

Eric Lindquist, DMV
DABVP, Cert. IVUSS

**IMAGING
PERFORMED BY**

Dr. Ohad Barnea

HOSPITAL NAME

Tenafly Vet Center

REFERRING VET

Dr. Ohad Barnea

INVOICE

33198

DATE

12/2/21