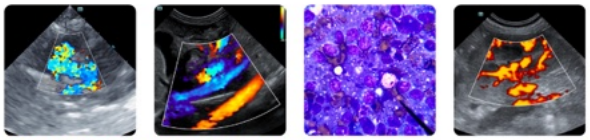

PATIENT
Mr Sparkles VanHaren

SPECIES
Feline

BREED
Domestic Shorthair

SEX
Neutered male

AGE
14 years

WEIGHT
14.25 lbs

INTERPRETED BY
Eric Lindquist, DMV DABVP, Cert. IVUSS

IMAGING PERFORMED BY
Jill Rumachik

HOSPITAL NAME
Clarity Imaging LLC

REFERRING VET
Dr. Jacka

INVOICE
69468

DATE
12/19/25

PRESENTING CLINICAL SIGNS

History: Recent vomiting (often food and hair) with weight loss (approx 1# in the past year) Abnormal PE/Chem/CBC/UA Results: 12/11/25: - CBC: RBC low normal, no apparent inflammation - Chemistry panel: kidney and liver values normal, one kidney parameter (BUN) borderline elevated (30) - T4: normal (not hyperthyroid) - Urinalysis: no protein, acceptable concentration for age, culture negative

ULTRASONOGRAPHIC EXAMINATION OF THE ABDOMEN

Urinary System

The **urinary bladder**, trigone, and pelvic urethra presented normal thicknesses and normal tone. The pelvic urethra was imaged 2.0 cm beyond the cystourethral junction and appeared normal. The ureters were not visible which is normal. No uroliths or sediment were visualized and anechoic urine was present. No evidence of inflammatory or neoplastic changes was noted. Ureteral papillae were normal.

The left **kidney** revealed an anechoic 0.5 cm cyst at the caudal pole with slight adjacent cortical collapse and mild loss of corticomedullary definition. There is mild loss of corticomedullary definition. The left kidney measured 3.8 cm. The right kidney was normal in size and structure measuring 4.0 cm.

Adrenal Glands

Both **adrenal glands** were visualized and recognized as having normal shape, size, position and echogenicity for this breed. The phrenic vasculature, glandular echogenicity and detail were unremarkable. Capsule, cortex, and medullary definition were normal for this age patient.

Spleen

The **spleen** was mildly enlarged with uniform, but subtly micronodular parenchyma, and undulating capsular contour. This is consistent with reactive spleen owing to immune stimulus or early infiltrative disease such as mast cell disease or lymphoma. 25-gauge FNA would be ideal if weight loss is an issue to differentiate early round cell neoplasia versus splenitis or reactive spleen all of which can present in this manner. The spleen measured up 1.2 cm.

Liver

The **liver** was enlarged with irregular contour and hypoechoic parenchyma. The gallbladder and common bile duct were unremarkable.

Gastrointestinal

Examination of the **gastrointestinal tract** revealed a stomach and intestine free of stasis, of normal wall thickness, acceptable curvilinear mural detail, and peristaltic activity. Small and large intestine

PATIENT
Mr Sparkles VanHaren

SPECIES
Feline

BREED
Domestic Shorthair

SEX
Neutered male

AGE
14 years

WEIGHT
14.25 lbs

INTERPRETED BY
Eric Lindquist, DMV
DABVP, Cert. IVUSS

IMAGING PERFORMED BY
Jill Rumachik

HOSPITAL NAME
Clarity Imaging LLC

REFERRING VET
Dr. Jacka

INVOICE
69468

DATE
12/19/25

demonstrated normal luminal chyme and stool consistency respectively. No obstructive or overt infiltrative disease was noted. No associated abnormal lymphatic activity was noted.

Pancreas

The **pancreas** was prominent and mildly irregular. History of pancreatitis is likely.

ULTRASONOGRAPHIC FINDINGS

Splenohepatomegaly.

Minor gallbladder sand was noted.

Chronic pancreatic changes.

Left renal cyst and mild degenerative changes.

INTERPRETATION OF THE FINDINGS & FURTHER RECOMMENDATIONS

I am concerned about occult neoplasia in the spleen and liver in this patient; therefore, screening FNA of the spleen and liver is recommended. The prognosis is guarded depending upon cytology results.

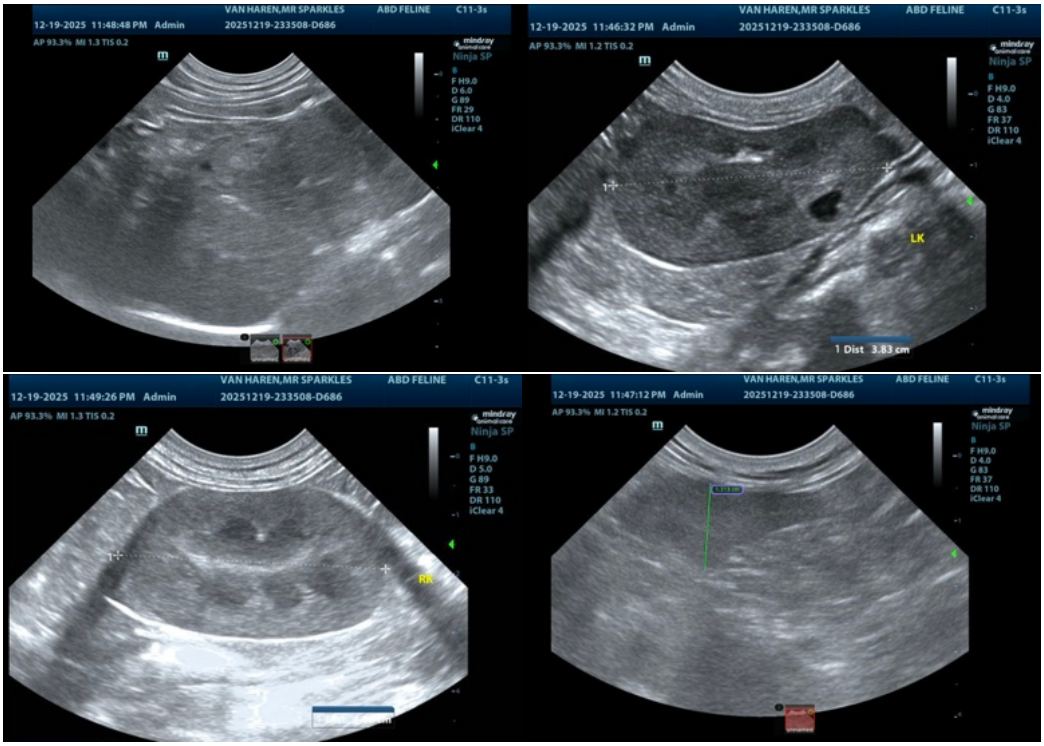

SonoPath
FOSTERING THE ART OF VETERINARY MEDICINE™

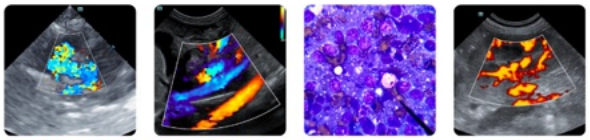

Clinical Sonography & Telecytology
Educational Teleconsultation Services™

SonoPath.com info@sonopath.com 1.800.838.4268

PATIENT

Mr Sparkles VanHaren

SPECIES

Feline

BREED

Domestic Shorthair

SEX

Neutered male

AGE

14 years

WEIGHT

14.25 lbs

INTERPRETED BY

Eric Lindquist, DMV
DABVP, Cert. IVUSS

IMAGING PERFORMED BY

Jill Rumachik

HOSPITAL NAME

Clarity Imaging LLC

REFERRING VET

Dr. Jacka

INVOICE

69468

DATE

12/19/25

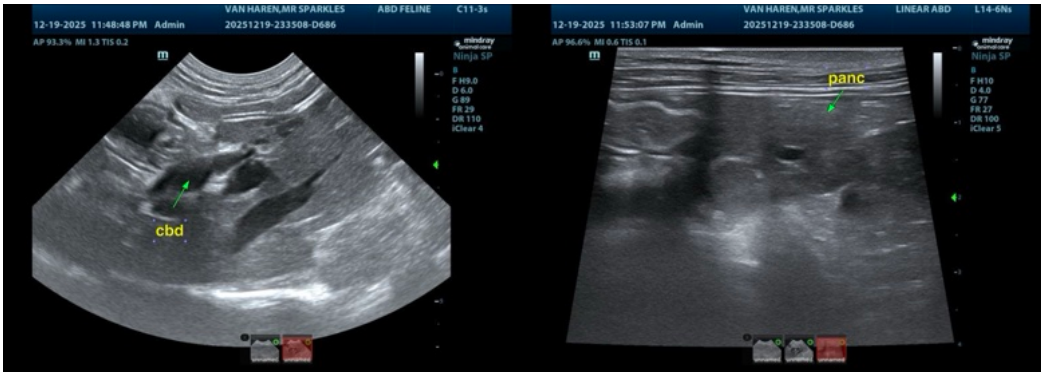

The information and recommendations provided are based on the images presented by the referring veterinarian/sonographer. No evaluation can be communicated regarding pathology that was not visible in the image/video clips provided.

Thank you for this referral. If the clinical or image interpretation does not parallel your findings or if I can be of any further assistance please contact me.

Eric Lindquist, DMV, DABVP (CFM), Cert. IVUSS, CEO of SonoPath.com

info@SonoPath.com