


PATIENT

Spots Budakian

PRESENTING CLINICAL SIGNS

Patient presents for dyspnea and elevated BNP. No reported meds or blood work, no thoracic radiograph.

SPECIES

Feline

ULTRASONOGRAPHIC EXAMINATION OF THE HEART
BREED

DSH

SEX

Neutered Male

AGE

14 Years

WEIGHT

9.14 Pounds

FELINE CARDIAC PARAMETERS	BODY WEIGHT (kg)	HR (BPM)	IVSd (cm)	LVIDd (cm)	LVWd (cm)	FS (%)	EF (%)
NORMAL PARAMETER	-----	150-240	0.3-0.6	1.0-2.1	0.25-0.6	35-67	80-100
PATIENT		49	0.44	1.87	0.44	32	63
FELINE CARDIAC PARAMETERS	LA/AO (Boon)	LA/AO HEART BASE (Sisson)	LA 2D 4-chamber long axis AS to FW (Sisson) (cm)	LVOT VEL. (m/s)	RVOT VEL. (m/s)	IVRT (m/)	
NORMAL PARAMETER	<1.5	0.88-1.79	0.7-1.7	<1.6	<1.3	40-60	
PATIENT	1.9	2.2	1.8	1.0	0.76	NM	

Adapted from June Boon, Veterinary Echocardiography, 1998
 Sisson D et al. JVIM 1991; 5: 232, Jacobs et al. Am J Vet Res 1985; 46:1705

Cardiac Presentation

The cardiac presentation revealed normal septal and free wall thicknesses, with minor left ventricular septal impingement on the left ventricular outflow tract, yet dynamic obstruction was not present. Mitral and tricuspid insufficiency present with volume overload in the left atrium and right atrium. Slight pleural effusion and pulmonary edema patterns noted. "Smoke" was noted in the left atrium, indicative of a hyperthrombotic state. Comet tail lung pattern noted in the lung fields.

INTERPRETED BY

Eric Lindquist, DMV

DABVP, Cert. IVUSS

IMAGING PERFORMED BY

Kelly Vazquez

HOSPITAL NAME

Westwood Regional

REFERRING VET

Dr. George Cattiny

ULTRASONOGRAPHIC FINDINGS

- Most consistent with unclassified cardiomyopathy, possible underlying myocarditis

INTERPRETATION OF THE FINDINGS & FURTHER RECOMMENDATIONS

Recommend quadrotherapy in this patient with Pimobendan off label at 0.3 mg/kg BID, ACE inhibitor 0.5 mg/kg SID, Lasix at 6.25 mg BID, and Plavix therapy. Target resting respiratory rate of <25/min. Oxygen and heat support warranted as necessary. Guarded prognosis. Recheck echo in 2-4 weeks, earlier if clinical presentation merits.

INVOICE

43549

DATE

12/19/22



PATIENT

Spots Budakian

SPECIES

Feline

BREED

DSH

SEX

Neutered Male

AGE

14 Years

WEIGHT

9.14 Pounds

INTERPRETED BY

Eric Lindquist, DMV
DABVP, Cert. IVUS

IMAGING PERFORMED BY

Kelly Vazquez

HOSPITAL NAME

Westwood Regional

REFERRING VET

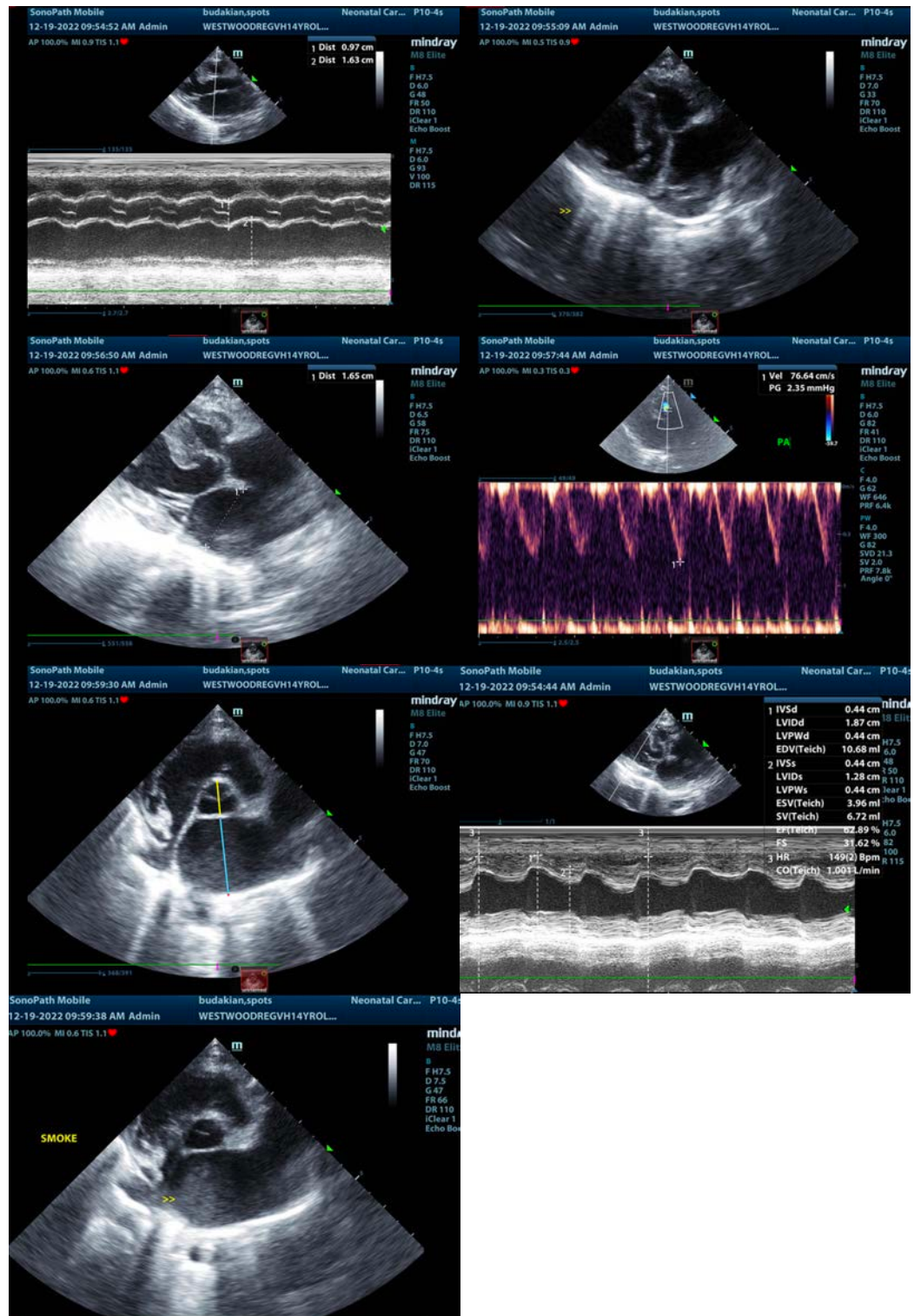
Dr. George Cattiny

INVOICE

43549

DATE

12/19/22





PATIENT

Spots Budakian

The information and recommendations provided are based on the images presented by the referring veterinarian/sonographer. No evaluation can be communicated regarding pathology that was not visible in the image/video clips provided.

SPECIES

Feline

Thank you for this referral. If the clinical or image interpretation does not parallel your findings or if I can be of any further assistance please contact me.

Eric Lindquist, DMV, DABVP, Cert. IVUSS, CEO of SonoPath.com

info@SonoPath.com

BREED

DSH

SEX

Neutered Male

AGE

14 Years

WEIGHT

9.14 Pounds

INTERPRETED BY

Eric Lindquist, DMV

DABVP, Cert. IVUSS

IMAGING PERFORMED BY

Kelly Vazquez

HOSPITAL NAME

Westwood Regional

REFERRING VET

Dr. George Cattiny

INVOICE

43549

DATE

12/19/22