



**PATIENT**

Peanut Della Torre

**SPECIES**

Canine

**BREED**

Belgian Malinois

**SEX**

Spayed Female

**AGE**

2

**WEIGHT**

43

**INTERPRETED BY**

Eric Lindquist, DMV  
DABVP, Cert. IVUSS

**IMAGING PERFORMED BY**

Jenn

**HOSPITAL NAME**

Rockaway AH

**REFERRING VET**

Dr. Maniar

**PRESENTING CLINICAL SIGNS**

History: re check last u/s 12/8 showed a 2.5 -3 cm linear structure in the pyloric antrum with acoustic shadowing, when owner dropped patient off she gave us a small green plastic object that she vomited up on Wednesday

**LIMITED ULTRASONOGRAPHIC EXAMINATION**

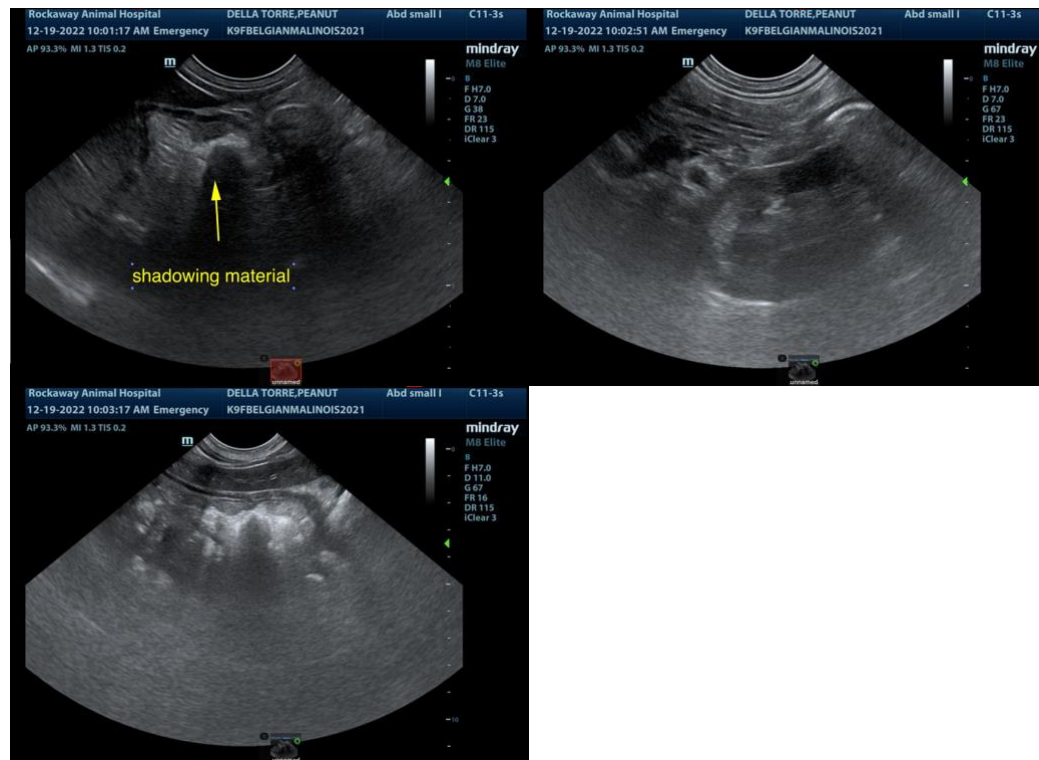
The upper **gastrointestinal tract** revealed persistent shadowing material, measuring approximately 1-2 cm, which was non obstructive at the time of the sonogram. This may represent oral medications; however, the small intestine and colon were unremarkable and empty.

**ULTRASONOGRAPHIC FINDINGS**

- Minor residual 1-2 cm shadowing material

**INTERPRETATION OF THE FINDINGS & FURTHER RECOMMENDATIONS**

This is possible residual foreign matter or oral medications, depending on the feeding and medication history. Feeding and induction of vomiting post prandial may allow for evacuation of the material, yet it is non obstructive.



**INVOICE**

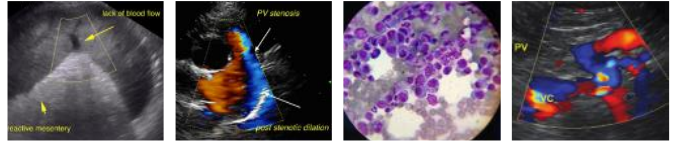
20182

**DATE**

12/19/22

**The information and recommendations provided are based on the images presented by the referring veterinarian. No evaluation can be communicated regarding pathology that was not visible in the image/video clips provided.**

Thank you for this referral. If the clinical or image interpretation does not parallel your findings or if I can be of any further assistance please contact me.



**PATIENT**

Peanut Della Torre

**Eric Lindquist**, DMV, DABVP, Cert. IVUSS, CEO of SonoPath.com  
info@SonoPath.com

**SPECIES**

Canine

**BREED**

Belgian Malinois

**SEX**

Spayed Female

**AGE**

2

**WEIGHT**

43

**INTERPRETED BY**

Eric Lindquist, DMV  
DABVP, Cert. IVUSS

**IMAGING  
PERFORMED BY**

Jenn

**HOSPITAL NAME**

Rockaway AH

**REFERRING VET**

Dr. Maniar

**INVOICE**

20182

**DATE**

12/19/22