

PATIENT

Oliver Goodwin

PRESENTING CLINICAL SIGNS

P presented to clinic not ADR. Not Eating. Nausea. P is tense to abdomen palpitation . Pleural effusion, ascitic. BP: 163/98, 176/102. BAR; HR; 130; hydration: WNL; BCS 5/9; Pulse: S,S; Temp : 102.0 F

SPECIES

Canine

ULTRASONOGRAPHIC EXAMINATION OF THE HEART & ABDOMEN

BREED

Labrador

SEX

Neutered Male

AGE

8 Years

WEIGHT

70.6 Pounds

CANINE CARDIAC PARAMETERS	MR VMAX (m/s)	TR VMAX (m/s)	LA/AO (Boon method)	LA/AO (Heart Base; Swe)	FS (%)	EF (%)	EPSS (cm)
NORMAL PARAMETER	4.5-5.5	<2.7	1.3	<1.6	28-40	40-100	<0.6
PATIENT			1.15	--	35	--	0.1
CANINE CARDIAC PARAMETERS	HR (BPM)	AV VMAX (m/s)	PV MAX (m/s)	BODY WEIGHT (kg)	LA 2D short axis Base view (cm)	LVIDd Avg; 2D and m-mode short axis (cm)	LVIDs Avg; 2D and m-mode short axis (cm)
NORMAL PARAMETER	50-100	0.7-1.7	0.7-1.6	BELOW	BELOW	BELOW	BELOW
PATIENT	--	--	--		--	3.5	

Cardiac Presentation

The echocardiogram in this patient demonstrated normal **left atrial** size based on 3 separate methods of LA evaluation. The cranial and caudal **mitral** valve leaflets presented normal linear structure, extension in systole, and union in diastole with normal kinesis. The **left ventricle** presented thicknesses with linear contour and was not dilated nor restricted. The **myocardium** presented normal echogenicity without subjective evidence of significant fibrotic or ischemic disease. **Contractility** of the ventricular walls was adequate and in normal range for this patient evidenced by the fractional shortening measurement and subjective evaluation of the different regions of the myocardium. The **left ventricular outflow** tract demonstrated normal laminar flow and subjective structural integrity. The **right atrium** and auricle revealed normal size, structure and content. No evidence of masses was noted. **Tricuspid** valvular assessment demonstrated adequate linear morphology and kinesis. The **right ventricle** was of normal size (1/3 diameter of LV), chordae structure, myocardial echogenicity and thickness. **Pulmonary outflow** tract assessment revealed normal valve structure, laminar flow, and diameter (approx. 1:1 pa/ao ratio). Pleural effusion noted in the chest, likely related to the abdominal pathology. The cranial **mediastinum and pericardial and extra-cardiac regions** were free of masses in the visible window.

Urinary System

The **urinary bladder**, trigone, and pelvic urethra presented normal thicknesses and normal tone. The ureters were not visible which is normal. No uroliths or sediment were visualized and anechoic urine was present. No evidence of inflammatory or neoplastic changes were noted. Ureteral papillae were normal.

The **kidneys** revealed largely normal size and structure, corticomedullary definition and ratio (cortex 1/3 of medulla) were essentially maintained with some age-related loss of curvilinear patterns regarding the capsule and C/M junction. The cortices presented largely uniform texture with some increased echogenicity expected for his age patient. Medullary structure differed distinctly from that of the cortex

INTERPRETED BY

Eric Lindquist, DMV

DABVP, Cert. IVUSS

IMAGING PERFORMED BY

Dr. Adrienne Waffle

HOSPITAL NAME

Torch Lake VC

REFERRING VET

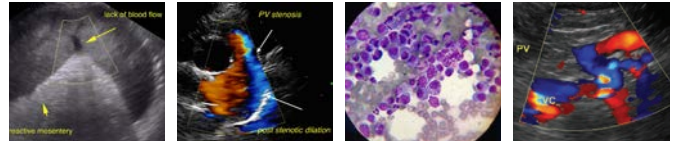
Dr. Adrienne Waffle

INVOICE

43548

DATE

12/19/22



PATIENT

Oliver Goodwin

and no evidence of pelvic dilation was present. The left kidney measured 5.65 cm. The right kidney measured 6.16 cm.

Adrenal Glands

SPECIES

Canine

The **left adrenal gland** was slightly swollen. The **right adrenal gland** was not visualized.

Spleen

BREED

Labrador

The **spleen** presented a smooth homogeneous parenchyma hyperechoic to liver and renal cortical parenchyma. The capsule was smooth without noticeable expansion or deviation from within the spleen or adjacent pathology. The splenic vasculature demonstrated normal volume without signs of congestion or thrombosis. No sonographic evidence of acute or chronic inflammatory, neoplastic, or infarctual changes were noted.

SEX

Neutered Male

Liver

AGE

8 Years

The **liver** images submitted revealed subjectively normal liver size, contour, and structure. Parenchymal echogenicity was naturally coarse and hypoechoic to the spleen. Vascular and biliary tracts were of normal volume with no evidence of congestion. The gallbladder presented acceptably thin walls with primarily anechoic content. The cystic and common bile ducts were normal. No pathological hepatic lymphadenopathy was evident. No overt structural evidence of inflammatory, infiltrative or regenerative pathology was evident.

WEIGHT

70.6 Pounds

Gastrointestinal

INTERPRETED BY

Eric Lindquist, DMV

Examination of the **gastrointestinal tract** revealed a stomach and intestine free of stasis, of normal wall thickness, acceptable curvilinear mural detail, and peristaltic activity. Small and large intestine demonstrated normal luminal chyme and stool consistency respectively. No obstructive or overt infiltrative disease was noted. No associated abnormal lymphatic activity was noted.

Pancreas

DABVP, Cert. IVUSS

The base and limbs of the **pancreas** were observed to be largely isoechoic to surrounding omental fat. Pancreatic duct and capsular contour were acceptably normal and parenchyma respected normal curvilinear patterns. No overt evidence of active inflammatory or neoplastic disease was noted.

IMAGING PERFORMED BY

Dr. Adrienne Waffle

Free Abdomen

Moderate amount of free fluid noted in the abdomen.

HOSPITAL NAME

Torch Lake VC

Ill-defined, mixed hypoechoic, nodular changes noted throughout the cranial abdomen, omentum and pancreas. Coalescing omentum noted in the cranial abdomen, enveloping the upper GI tract. Secondary ascites present.

REFERRING VET

Dr. Adrienne Waffle

ULTRASONOGRAPHIC FINDINGS

- Nodular omental changes and free fluid - carcinomatosis/lymphomatosis type presentation
- Age related renal changes
- Slightly swollen left adrenal gland
- Normal echocardiogram
- Pleural effusion

INVOICE

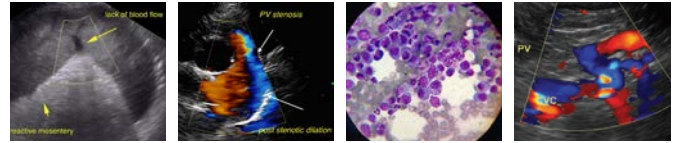
43548

INTERPRETATION OF THE FINDINGS & FURTHER RECOMMENDATIONS

DATE

12/19/22

No evidence of cardiac disease. Dual cavity neoplasia, lymphomatosis, carcinomatosis suspected. FNAs indicated.



PATIENT

Oliver Goodwin

SPECIES

Canine

BREED

Labrador

SEX

Neutered Male

AGE

8 Years

WEIGHT

70.6 Pounds

INTERPRETED BY

Eric Lindquist, DMV

DABVP, Cert. IVUSS

IMAGING PERFORMED BY

Dr. Adrienne Waffle

HOSPITAL NAME

Torch Lake VC

REFERRING VET

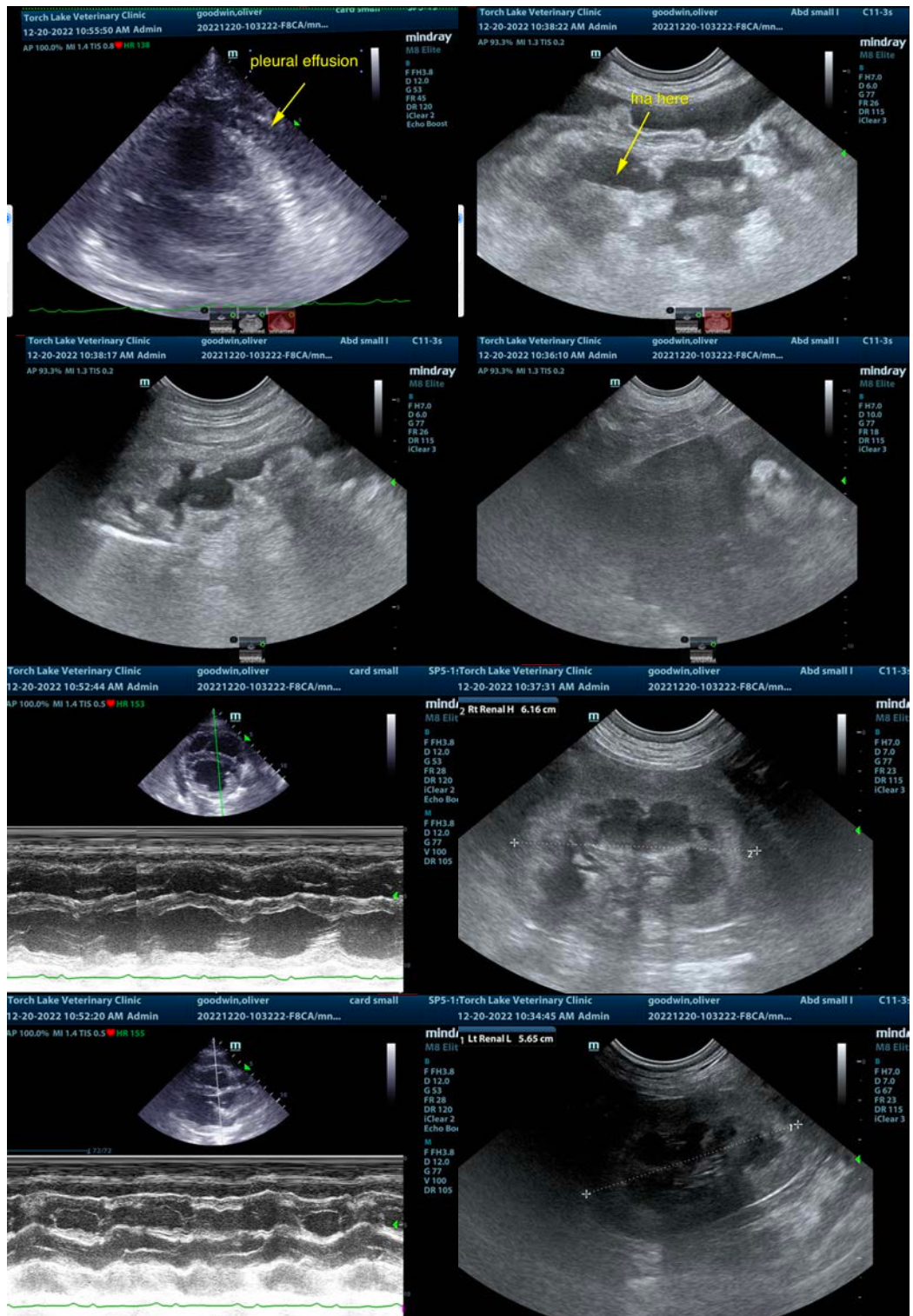
Dr. Adrienne Waffle

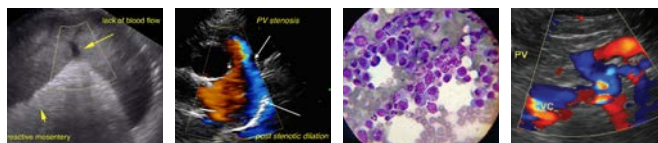
INVOICE

43548

DATE

12/19/22





PATIENT

Oliver Goodwin

The information and recommendations provided are based on the images presented by the referring veterinarian/sonographer. No evaluation can be communicated regarding pathology that was not visible in the image/video clips provided.

SPECIES

Canine

Thank you for this referral. If the clinical or image interpretation does not parallel your findings or if I can be of any further assistance please contact me.

Eric Lindquist, DMV, DABVP, Cert. IVUSS, CEO of SonoPath.com

info@SonoPath.com

BREED

Labrador

SEX

Neutered Male

AGE

8 Years

WEIGHT

70.6 Pounds

INTERPRETED BY

Eric Lindquist, DMV

DABVP, Cert. IVUSS

IMAGING PERFORMED BY

Dr. Adrienne Waffle

HOSPITAL NAME

Torch Lake VC

REFERRING VET

Dr. Adrienne Waffle

INVOICE

43548

DATE

12/19/22