


PATIENT

Harrison Warren

SPECIES

Feline

BREED

Domestic Longhair

SEX

Neutered male

AGE

13 years

WEIGHT

10 lbs

INTERPRETED BY

 Eric Lindquist, DMV
 DABVP, Cert. IVUSS

IMAGING PERFORMED BY

Dr. Waffle

HOSPITAL NAME

Torch Lake VC

REFERRING VET

Dr. Waffle

INVOICE

43204

DATE

12/19/22

PRESENTING CLINICAL SIGNS

History: Hx of tachypnea this weekend. Bronchial pattern noted - treated with dex sp. Worsened significantly than night. Owner returned to ER in am. Rads initially interpreted as bronchial - but sent to IDEXX for stat read. Was started on Clavamox. Owner reports he has significantly improved in last 24 hours

Abnormal PE/Chem/CBC/UA Results: Idexx report - bronco interstitial pattern. concern for early heart failure BP 114/118, 137/111; 150/121 HR - 130 RR - 40 Unable to auscultate murmur Bloodwork pending

ULTRASONOGRAPHIC EXAMINATION OF THE HEART

The echocardiogram in this patient demonstrated normal septal and free wall thicknesses with adequate contractility, yet volume overload was noted in the left atrium and right atrium. Mitral and tricuspid insufficiency was noted. Comet tail lung pattern was noted in the lung fields.

FELINE CARDIAC PARAMETERS	BODY WEIGHT (kg)	HR (BPM)	IVSd (cm)	LVIDd (cm)	LVWd (cm)	FS (%)	EF (%)
NORMAL PARAMETER	-----	150-240	0.3-0.6	1.0-2.1	0.25-0.6	35-67	80-100
PATIENT		NM	0.4	1.8	0.55	30	
FELINE CARDIAC PARAMETERS	LA/AO (Boon)	LA/AO HEART BASE (Sisson)	LA 2D 4-chamber long axis AS to FW (Sisson) (cm)		LVOT VEL. (m/s)	RVOT VEL. (m/s)	IVRT (m/)
NORMAL PARAMETER	<1.5	0.88-1.79	0.7-1.7		<1.6	<1.3	40-60
PATIENT	2.0	>2.0	2.0 max				NM
Adapted from June Boon, Veterinary Echocardiography, 1998 Sisson D et al. JVIM 1991; 5: 232, Jacobs et al. Am J Vet Res 1985; 46:1705							



PATIENT

Harrison Warren

ULTRASONOGRAPHIC FINDINGS

Left-sided heart failure owing to unclassified cardiomyopathy.

SPECIES

Feline

INTERPRETATION OF THE FINDINGS & FURTHER RECOMMENDATIONS

I recommend quadrotherapy in this patient with Pimobendan off label at 0.3 mg/kg b.i.d., Lasix at 6.25 mg/kg b.i.d. and ace inhibitor at 0.5 mg/kg s.i.d. Plavix therapy would also be appropriate. Recheck echocardiogram is recommended in a month. Target respiratory rate is less than 25/minute.

BREED

Domestic Longhair

SEX

Neutered male

AGE

13 years

WEIGHT

10 lbs

INTERPRETED BY

Eric Lindquist, DMV
DABVP, Cert. IVUSS

IMAGING PERFORMED BY

Dr. Waffle

HOSPITAL NAME

Torch Lake VC

REFERRING VET

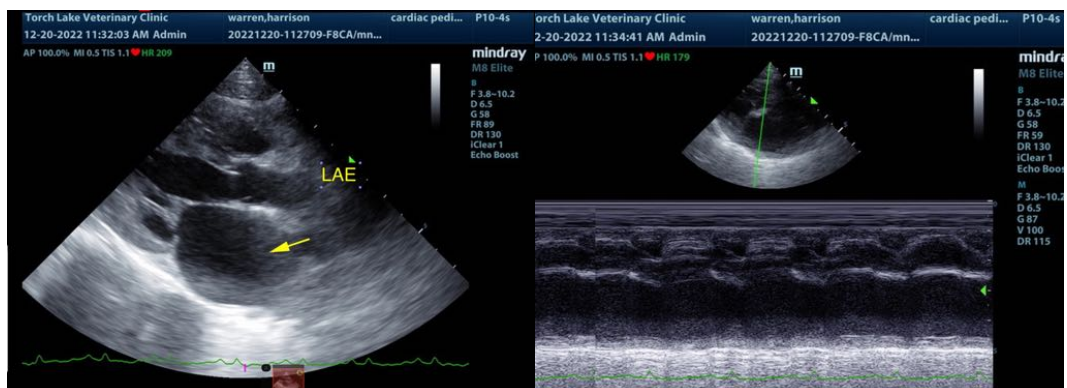
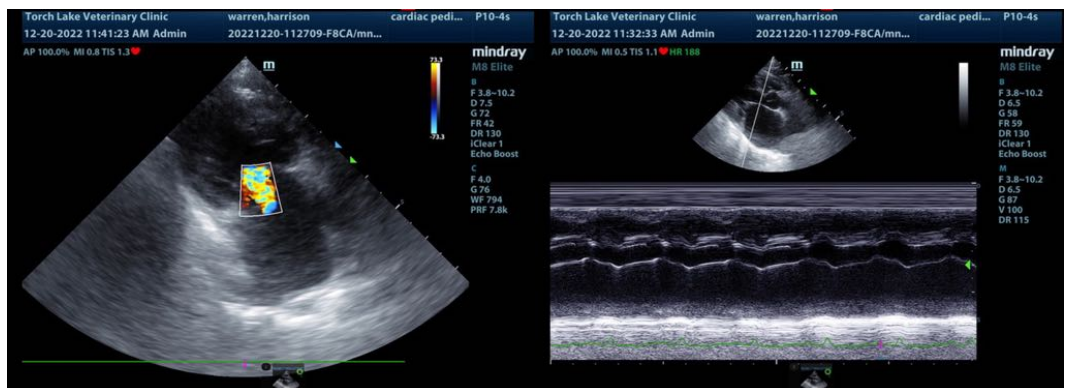
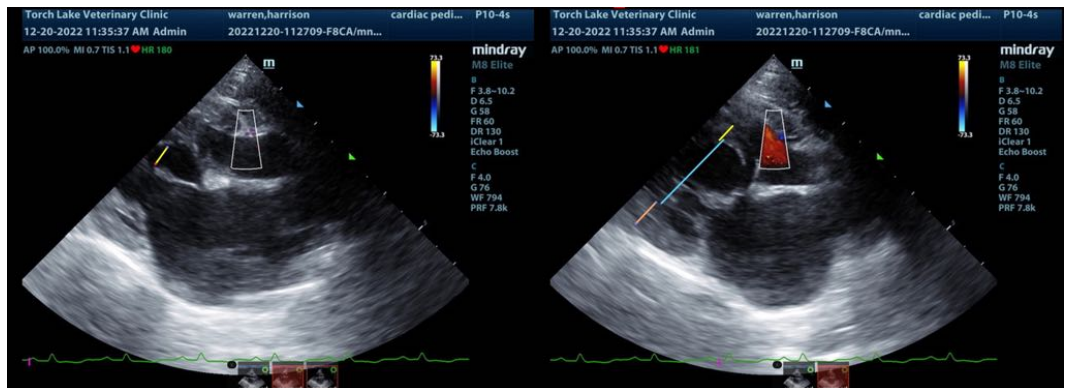
Dr. Waffle

INVOICE

43204

DATE

12/19/22





PATIENT

Harrison Warren

The information and recommendations provided are based on the images presented by the referring veterinarian/sonographer. No evaluation can be communicated regarding pathology that was not visible in the image/video clips provided.

SPECIES

Feline

Thank you for this referral. If the clinical or image interpretation does not parallel your findings or if I can be of any further assistance please contact me.

BREED

Domestic Longhair

Eric Lindquist, DMV, DABVP, Cert. IVUSS, CEO of SonoPath.com
info@SonoPath.com

SEX

Neutered male

AGE

13 years

WEIGHT

10 lbs

INTERPRETED BY

Eric Lindquist, DMV
DABVP, Cert. IVUSS

**IMAGING
PERFORMED BY**

Dr. Waffle

HOSPITAL NAME

Torch Lake VC

REFERRING VET

Dr. Waffle

INVOICE

43204

DATE

12/19/22