



PATIENT

Bella Mariam

SPECIES

Feline

BREED

Domestic Shorthair

SEX

Female

AGE

6 years

WEIGHT

3.37 kg

PRESENTING CLINICAL SIGNS

History: Grade 5-6 HM with palpable thrill was heard by the RDVM. He also heard cardiac arrhythmia

Abnormal PE/Chem/CBC/UA Results: Abnormal proBNP result

ULTRASONOGRAPHIC EXAMINATION OF THE HEART

The **left atrium** in this patient demonstrated upper limits of normal size in the LA max position. False membrane appears to be present and attached to the left atrial septum, which is consistent with congenital anomaly. Minor **mitral** valve insufficiency was noted. Minor **left ventricular** dilation was noted likely owing to stenosis. A false membrane attached to the left atrial septum was noted. Minor, irregular **myocardial** remodeling was noted. **Contractility** of the ventricular walls was adequate and in normal range for this patient evidenced by the fractional shortening measurement and subjective evaluation of the different regions and angles of the myocardium. The aortic valve appeared dysplastic in this patient with excessive **outflow** velocity and aortic insufficiency. The septal leaflet of the aortic valve appeared to be shortened. This is consistent with valvular aortic stenosis. The **right atrium** and auricle revealed normal size, structure and content. No evidence of masses was noted or chamber overload. **Tricuspid** valvular assessment demonstrated adequate linear morphology and kinetics. The **right ventricle** was of normal size (1/3 diameter of LV), chordae structure, myocardial echogenicity and thickness. **Pulmonic** tract assessment revealed normal valve structure, laminar flow, and diameter (approx.1:1 pa/ao ratio). No visible **pericardial** or free pleura fluid was noted or extra cardiac pathology in the visible planes. The cranial **mediastinum and pericardial regions** were free of masses in the visible window. Periodic arrhythmia was present. EKG is indicated.

INTERPRETED BY

Eric Lindquist, DMV
DABVP, Cert. IVUSS

IMAGING PERFORMED BY

Dr. Inam ul haq

HOSPITAL NAME

City Veterinary Clinic
Abu Dhabi Khalifa City

REFERRING VET

Dr. Inam ul haq

INVOICE

43206

DATE

12/19/22

FELINE CARDIAC PARAMETERS	BODY WEIGHT (kg)	HR (BPM)	IVSd (cm)	LVIDd (cm)	LVWd (cm)	FS (%)	EF (%)
NORMAL PARAMETER	-----	150-240	0.3-0.6	1.0-2.1	0.25-0.6	35-67	80-100
PATIENT	3.37 kg	220	0.43	1.91	0.38	43	77
FELINE CARDIAC PARAMETERS	LA/AO (Boon)	LA/AO HEART BASE (Sisson)	LA 2D 4-chamber long axis AS to FW (Sisson) (cm)	LVOT VEL. (m/s)	RVOT VEL. (m/s)	IVRT (m/)	
NORMAL PARAMETER	<1.5	0.88-1.79	0.7-1.7	<1.6	<1.3	40-60	
PATIENT			1.6	3.0	0.95	NM	
Adapted from June Boon, Veterinary Echocardiography, 1998 Sisson D et al. JVIM 1991; 5: 232, Jacobs et al. Am J Vet Res 1985; 46:1705							



PATIENT **ULTRASONOGRAPHIC FINDINGS**

Bella Mariam

Valvular aortic stenosis with increased LVOT velocity and secondary aortic insufficiency.
Secondary left ventricular dilation, mild and presently compensated.

SPECIES

Feline

False membrane of the atrial septum.
Secondary minor mitral insufficiency.

BREED

Domestic Shorthair

Possible atypical form of cor triatriatum

INTERPRETATION OF THE FINDINGS & FURTHER RECOMMENDATIONS

SEX

Female

Atenolol therapy will likely be in this patient's best interest as this is essentially an aortic valve dysplasia/valvular stenosis type presentation. Target heart rate is < 180 bpm. There is no evidence of left sided failure; however, some comet tail lung pattern was noted. Chest radiographs are recommended to assess concurrent pulmonary disease is indicated. Trace pericardial effusion was noted and may be related to systemic disease and is not cardiogenic. Atenolol therapy is recommended at 6.25 mg b.i.d., yet should be evaluated in light of the electrocardiogram. Cardiologist review would be ideal for further definition. Recheck echocardiogram is recommended in 6 months or earlier if clinical signs initiate.

AGE

6 years

WEIGHT

3.37 kg

INTERPRETED BY

Eric Lindquist, DMV
DABVP, Cert. IVUSS

IMAGING PERFORMED BY

Dr. Inam ul haq

HOSPITAL NAME

City Veterinary Clinic
Abu Dhabi Khalifa City

REFERRING VET

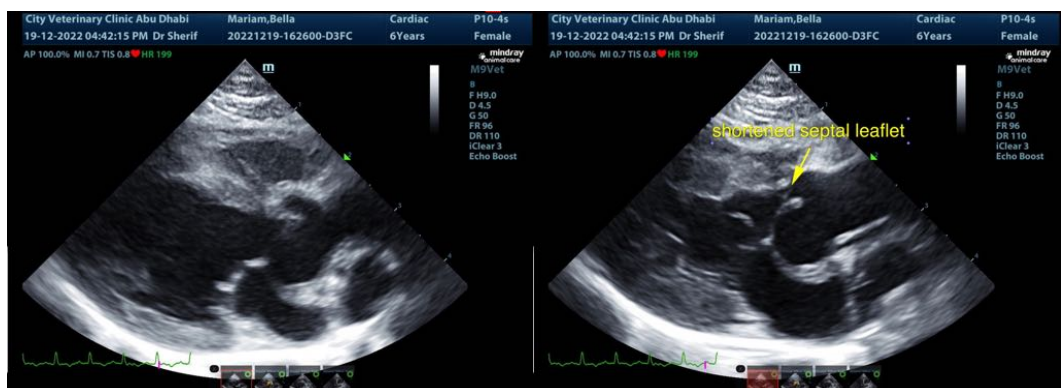
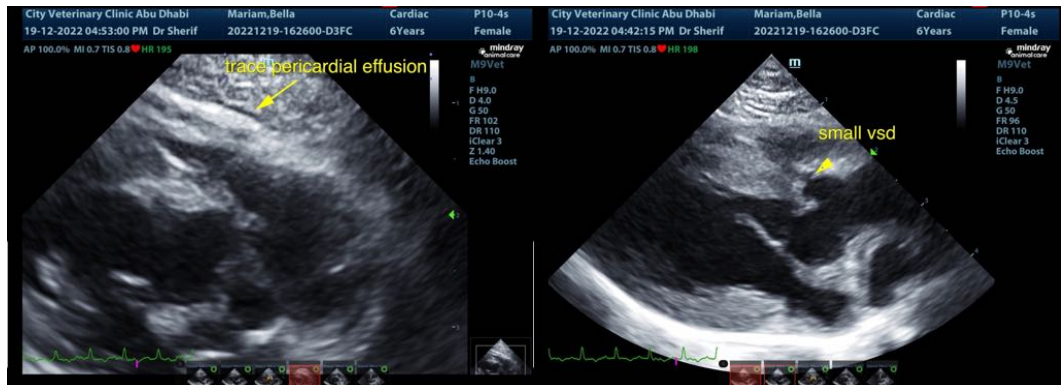
Dr. Inam ul haq

INVOICE

43206

DATE

12/19/22





PATIENT

Bella Mariam

SPECIES

Feline

BREED

Domestic Shorthair

SEX

Female

AGE

6 years

WEIGHT

3.37 kg

INTERPRETED BY

Eric Lindquist, DMV
DABVP, Cert. IVUSS

IMAGING PERFORMED BY

Dr. Inam ul haq

HOSPITAL NAME

City Veterinary Clinic
Abu Dhabi Khalifa City

REFERRING VET

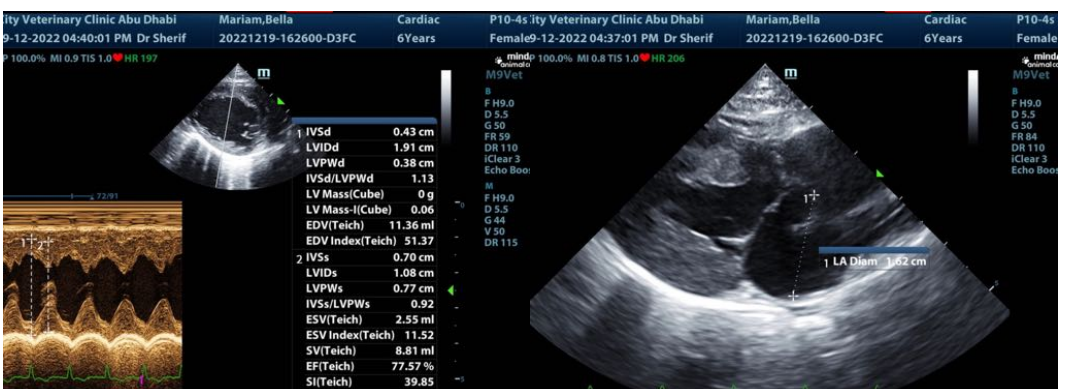
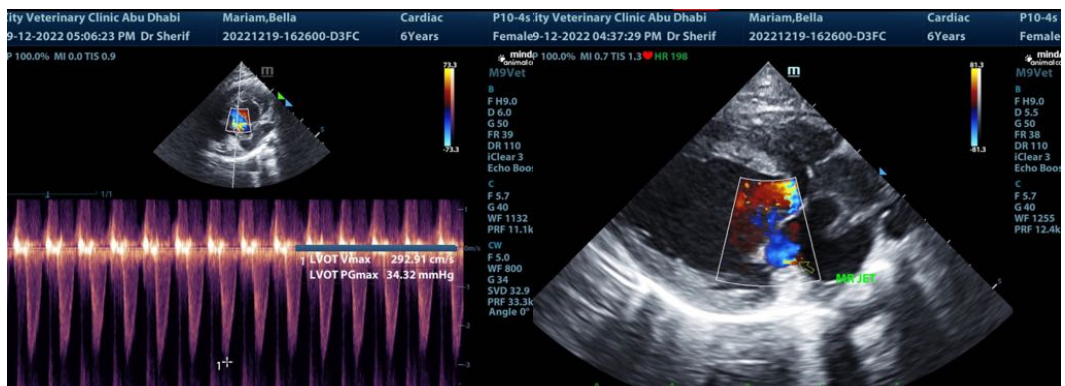
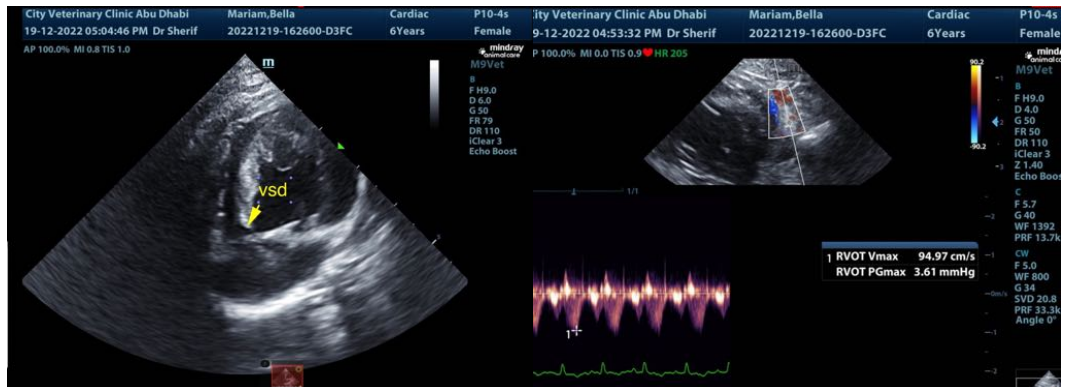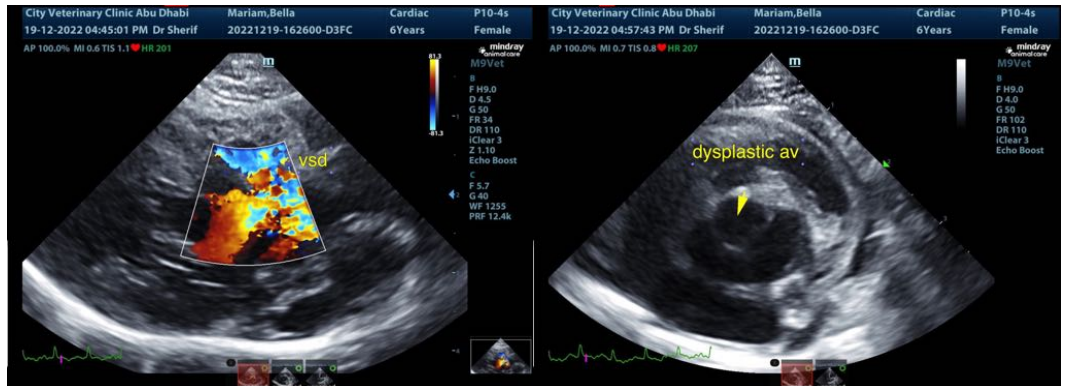
Dr. Inam ul haq

INVOICE

43206

DATE

12/19/22





PATIENT

Bella Mariam

The information and recommendations provided are based on the images presented by the referring veterinarian/sonographer. No evaluation can be communicated regarding pathology that was not visible in the image/video clips provided.

SPECIES

Feline

Thank you for this referral. If the clinical or image interpretation does not parallel your findings or if I can be of any further assistance please contact me.

BREED

Domestic Shorthair

Eric Lindquist, DMV, DABVP, Cert. IVUSS, CEO of SonoPath.com
info@SonoPath.com

SEX

Female

AGE

6 years

WEIGHT

3.37 kg

INTERPRETED BY

Eric Lindquist, DMV
DABVP, Cert. IVUSS

**IMAGING
PERFORMED BY**

Dr. Inam ul haq

HOSPITAL NAME

City Veterinary Clinic
Abu Dhabi Khalifa City

REFERRING VET

Dr. Inam ul haq

INVOICE

43206

DATE

12/19/22