



PATIENT

Tiller Stover

SPECIES

Canine

BREED

Border Collie

SEX

Spayed Female

AGE

11

WEIGHT

39

INTERPRETED BY

Eric Lindquist, DMV,
DABVP (CFM), Cert.
IVUSS

IMAGING PERFORMED BY

Dr. James Hornbuckle

HOSPITAL NAME

Golden Isles Animal
Hospital

REFERRING VET

Dr. James Hornbuckle

INVOICE

72704

DATE

12/18/25

PRESENTING CLINICAL SIGNS

Tiller has had a heart murmur for some time and until recently was asymptomatic. Within the last 2 to 3 weeks she's had 1 or 2 episodes of falling over and an occasional cough. Neurologically she is within normal limits there doesn't appear to be neurologic disease peripherally. To this point she is not medicated with respect to her heart murmur, and as such an echocardiogram was ordered to evaluate further.

ULTRASONOGRAPHIC EXAMINATION OF THE HEART

CANINE CARDIAC PARAMETERS	MR VMAX (m/s)	TR VMAX (m/s)	LA/AO (M-Mode)	LA/AO (Heart Base; Swe)	FS (%)	EF (%)	EPSS (cm)
NORMAL PARAMETER	4.5-5.5	<2.7	1.3	Up to 1.6	28-40	40-100	<0.6
PATIENT	--	--	1.8	>3.0	32	60	0.6
CANINE CARDIAC PARAMETERS	HR (BPM)	AV VMAX (m/s)	PV MAX (m/s)	BODY WEIGHT	LAD LA MAX 4 Chamber	LVIDd Avg; 2D and m-mode short axis (cm)	LVIDs Avg; 2D and m-mode short axis (cm)
NORMAL PARAMETER	50-100	0.7-1.7	0.7-1.6				
PATIENT	--	1.5	0.60	39	6.2	5.4	--

Cardiac Presentation

The cardiac presentation revealed severe volume overload of the left atrium and left ventriculi. Mild right atrial enlargement noted. Mitral and tricuspid insufficiency noted. Prolapse of the anterior mitral valve leaflet noted. Contractility was poor for this amount of volume overload. Slight pericardial effusion noted owing to chronic volume overload. No evidence of masses. Pulmonic and aortic outflow tracts were unremarkable.

ULTRASONOGRAPHIC FINDINGS

- Stage C1 valvular disease with myocardial insufficiency.

INTERPRETATION OF THE FINDINGS & FURTHER RECOMMENDATIONS

Recommend quadrotherapy in this patient with Pimobendan at 0.3 mg/kg BID, ACE inhibitor 0.5 mg/kg SID progressing to BID, Lasix at 2-3 mg/kg BID, and Spironolactone at 1-2 mg/kg SID. Monitoring BUN, creatinine, blood pressures, EKG, and radiographs indicated. Thyroid assessment indicated as well as taurine levels. Nutraceuticals and heart based diet all indicated. Causes of myocarditis should be considered yet not overtly suspected in this case. Note that the criteria for DCM is not present even though myocardial insufficiency is evident. EPSS was within normal limits.



PATIENT

Tiller Stover

SPECIES

Canine

BREED

Border Collie

SEX

Spayed Female

AGE

11

WEIGHT

39

INTERPRETED BY

Eric Lindquist, DMV,
DABVP (CFM), Cert.
IVUSS

IMAGING PERFORMED BY

Dr. James Hornbuckle

HOSPITAL NAME

Golden Isles Animal
Hospital

REFERRING VET

Dr. James Hornbuckle

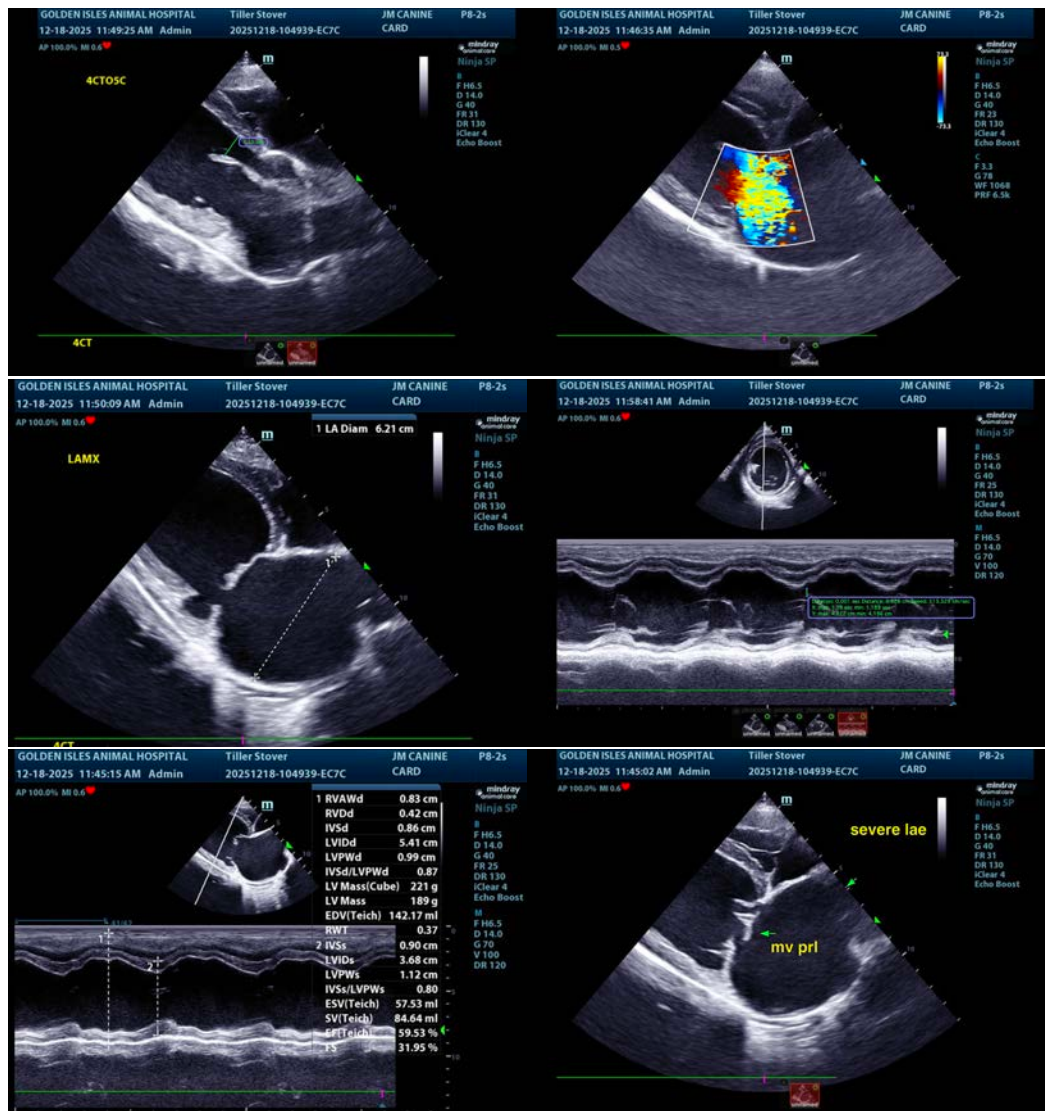
INVOICE

72704

DATE

12/18/25

The heart is in a somewhat precarious state with volume overload and a heart that is working to compensate for the valvular insufficiency. Target respiratory rate is < 20 resp/minute after therapy. After initiating therapy, I recommend recheck on the clinical exam, BUN, Creatinine, USG, Chest radiographs & Blood pressure in 5-7 days. Recheck echo in 1 month. Earlier if clinical decompensation is occurring. I do not recommend anesthesia at this time until stabilization has occurred on the recommended medications. Repeat preanesthetic echo is ideal if anesthesia is eventually necessary. There is severe anesthetic risk for this patient. Light dose opioids may be used to calm but I do not recommend anesthesia.





PATIENT

Tiller Stover

SPECIES

Canine

BREED

Border Collie

SEX

Spayed Female

AGE

11

WEIGHT

39

INTERPRETED BY

Eric Lindquist, DMV,
DABVP (CFM), Cert.
IVUSS

IMAGING PERFORMED BY

Dr. James Hornbuckle

HOSPITAL NAME

Golden Isles Animal
Hospital

REFERRING VET

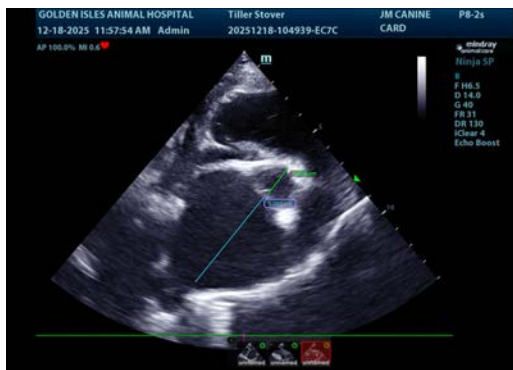Dr. James Hornbuckle

INVOICE

72704

DATE

12/18/25



The information and recommendations provided are based on the images presented by the referring veterinarian/sonographer. No evaluation can be communicated regarding pathology that was not visible in the image/video clips provided.

Thank you for this referral. If the clinical or image interpretation does not parallel your findings or if I can be of any further assistance please contact me.

Eric Lindquist, DMV, DABVP(CFM), Cert. IVUSS,
CEO, Owner, Founder -- SonoPath.com
info@SonoPath.com