



PATIENT

Coco Dassule

SPECIES

Feline

BREED

Russian Blue

SEX

Spayed Female

AGE

6 Years

WEIGHT

10

INTERPRETED BY

Eric Lindquist, DMV,
DABVP (CFM), Cert.
IVUSS

IMAGING PERFORMED BY

Dr. Michele
Pffannenstiel

HOSPITAL NAME

Mill Brook Animal
Clinic

REFERRING VET

Dr. Michele
Pffannenstiel

INVOICE

72707

DATE

12/18/25

PRESENTING CLINICAL SIGNS

Pt presented for annual exam. Screening UA came back abnormal; suspect CKD IRIS stage 1 but she seems young.

Abnormal PE/Chem/CBC/UA Results: Low USG on serial UA with borderline hypertension and no proteinuria;

ULTRASONOGRAPHIC EXAMINATION OF THE ABDOMEN

Urinary System

The **urinary bladder**, trigone, and pelvic urethra presented normal thicknesses and normal tone. The ureters were not visible which is normal. No uroliths or sediment were visualized and anechoic urine was present. No evidence of inflammatory or neoplastic changes were noted. Ureteral papillae were normal. The pelvic urethra was imaged 1.0 cm beyond the cystourethral junction.

The **kidneys** revealed normal size and structure, corticomedullary definition and ratio for this age. The cortices presented largely uniform texture with normal echogenic relationship to liver and spleen. Medullary structure differed distinctly from the cortex and no evidence of pelvic dilation was present. The capsules were acceptably uniform without significant irregularities. Left kidney measured 3.7 cm. Right kidney measured 4.0 cm.

Adrenal Glands

Both **adrenal glands** were visualized and recognized as having normal shape, size, position and echogenicity for this breed. The phrenic vasculature, glandular echogenicity and detail were unremarkable. Capsule, cortex, and medullary definition were normal for this age patient. Right measured 0.50 cm. Left measured 0.50 cm.

Spleen

The **spleen** measured 0.98 cm. It presented a smooth homogeneous parenchyma hyperechoic to liver and renal cortical parenchyma. The capsule was smooth without noticeable expansion or deviation from within the spleen or adjacent pathology. The splenic vasculature demonstrated normal volume without signs of congestion or thrombosis. No sonographic evidence of acute or chronic inflammatory, neoplastic, or infarctual changes were noted.

Liver

The **liver** images submitted revealed subjectively normal liver size, contour, and structure. Parenchymal echogenicity was naturally coarse and hypoechoic to the spleen. Vascular and biliary tracts were of normal volume with no evidence of congestion. The gallbladder presented acceptably thin walls with primarily anechoic content. The cystic and common bile ducts were normal. No pathological hepatic lymphadenopathy was evident. No overt structural evidence of inflammatory, infiltrative or regenerative pathology was evident.

Gastrointestinal

The **stomach** revealed progressively shadowing material consistent with hairball accumulation, assuming the patient was NPO at the time of the sonogram. Transit of chyme was normal in the small intestine.



PATIENT

Coco Dassule

SPECIES

Feline

BREED

Russian Blue

SEX

Spayed Female

AGE

6 Years

WEIGHT

10

INTERPRETED BY

Eric Lindquist, DMV,
DABVP (CFM), Cert.
IVUSS

IMAGING PERFORMED BY

Dr. Michele
Pfannenstiel

HOSPITAL NAME

Mill Brook Animal
Clinic

REFERRING VET

Dr. Michele
Pfannenstiel

INVOICE

72707

DATE

12/18/25

Pancreas

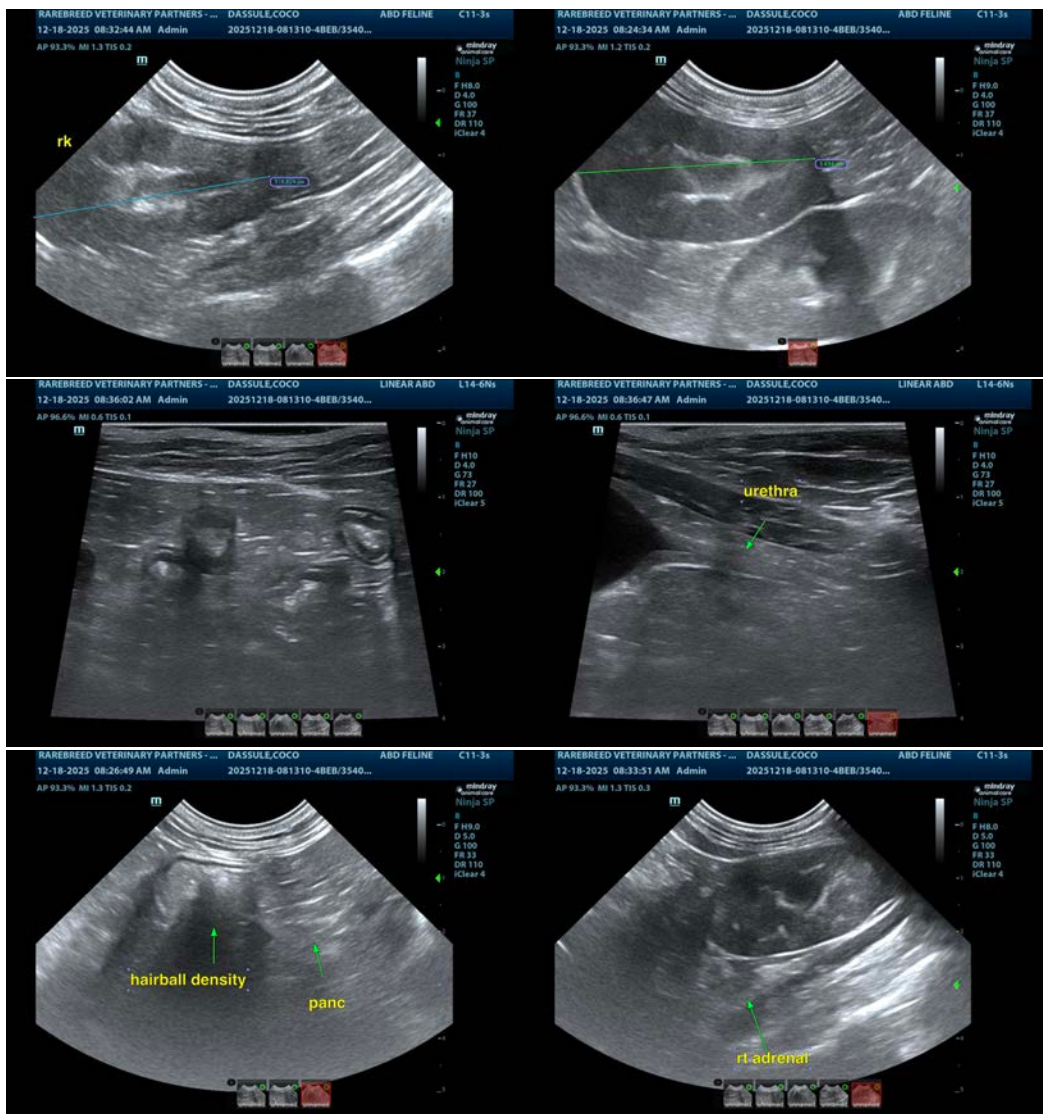
The base and limbs of the **pancreas** were observed to be largely isoechoic to surrounding omental fat. Pancreatic duct and capsular contour were acceptably normal and parenchyma respected normal curvilinear patterns. No overt evidence of active inflammatory or neoplastic disease was noted.

ULTRASONOGRAPHIC FINDINGS

- Structurally unremarkable abdomen with hairball density in the stomach.

INTERPRETATION OF THE FINDINGS & FURTHER RECOMMENDATIONS

No evidence of significant clinical disease.





PATIENT

Coco Dassule

SPECIES

Feline

BREED

Russian Blue

SEX

Spayed Female

AGE

6 Years

WEIGHT

10

INTERPRETED BY

Eric Lindquist, DMV,
DABVP (CFM), Cert.
IVUSS

IMAGING PERFORMED BY

Dr. Michele
Pffannenstiel

HOSPITAL NAME

Mill Brook Animal
Clinic

REFERRING VET

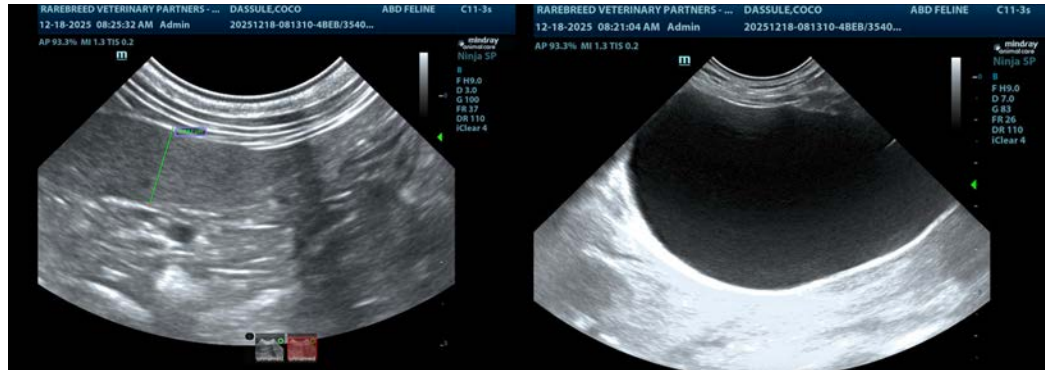
Dr. Michele
Pffannenstiel

INVOICE

72707

DATE

12/18/25



The information and recommendations provided are based on the images presented by the referring veterinarian/sonographer. No evaluation can be communicated regarding pathology that was not visible in the image/video clips provided.

Thank you for this referral. If the clinical or image interpretation does not parallel your findings or if I can be of any further assistance please contact me.

Eric Lindquist, DMV, DABVP(CFM), Cert. IVUSS,
CEO, Owner, Founder -- SonoPath.com
info@SonoPath.com