



PATIENT

Willow Brandsetter

SPECIES

Canine

BREED

Mix

SEX

Female

AGE

25 weeks

WEIGHT

32.5 lbs

INTERPRETED BY

Eric Lindquist, DMV
DABVP, Cert. IVUSS

IMAGING PERFORMED BY

Shane Stafford

HOSPITAL NAME

West Newton Animal
Clinic

REFERRING VET

Dr. Brandon Holmes

INVOICE

69393

DATE

12/17/25

PRESENTING CLINICAL SIGNS

History: She has experienced two episodes of Stranguria, indicative of a urinary tract infection (UTI). - Initially treated with antibiotics in October, which were effective for about five weeks. - In late November, she showed signs of another UTI with mixed bacteria. - Treatment with cefpodoxime had limited success, with symptoms returning quickly. - A urine culture isolated *Staph warneri*, considered environmental or commensal, not likely the pathogen, so no susceptibility testing was done. - Switched to doxycycline on December 2, but no improvement was observed. - An abdominal ultrasound was recommended to check the kidneys, bladder, urethra, and for signs of patent urachus.

ULTRASONOGRAPHIC EXAMINATION OF THE ABDOMEN

Urinary System

The **urinary bladder**, trigone, and pelvic urethra presented normal thicknesses and normal tone. The pelvic urethra was imaged 2.0 cm beyond the cystourethral junction and appeared normal. The ureters were not visible which is normal. No uroliths or sediment were visualized and anechoic urine was present. No evidence of inflammatory or neoplastic changes was noted. Ureteral papillae were normal.

The **kidneys** revealed normal size and structure, corticomedullary definition and ratio for this age. The cortices presented largely uniform texture with normal echogenic relationship to liver and spleen. Medullary structure differed distinctly from the cortex and no evidence of pelvic dilation was present. The capsules were acceptably uniform without significant irregularities. The left kidney measured 6.0 cm. The right kidney measured 6.5 cm.

Adrenal Glands

Both **adrenal glands** were visualized and recognized as having normal shape, size, position and echogenicity for this breed. The phrenic vasculature, glandular echogenicity and detail were unremarkable. Capsule, cortex, and medullary definition were normal for this age patient. The left adrenal gland measured 1.71 x 0.41 cm at the cranial pole and 0.43 cm at the caudal pole.

Spleen

The **spleen** presented a smooth homogeneous parenchyma hyperechoic to liver and renal cortical parenchyma. The capsule was smooth without noticeable expansion or deviation from within the spleen or adjacent pathology. The splenic vasculature demonstrated normal volume without signs of congestion or thrombosis. No sonographic evidence of acute or chronic inflammatory, neoplastic, or infarctual changes was noted.

Liver

The **liver** images submitted revealed subjectively normal liver size, contour, and structure. Parenchymal echogenicity was naturally coarse and hypoechoic to the spleen. Vascular and biliary tracts were of normal volume with no evidence of congestion. The gallbladder presented acceptably thin walls with



PATIENT

Willow Brandsetter

primarily anechoic content. The cystic and common bile ducts were normal. No pathological hepatic lymphadenopathy was evident. No overt structural evidence of inflammatory, infiltrative or regenerative pathology was evident.

SPECIES

Canine

Gastrointestinal

BREED

Mix

Examination of the **gastrointestinal tract** revealed a stomach and intestine free of stasis, of normal wall thickness, acceptable curvilinear mural detail, and peristaltic activity. Small and large intestine demonstrated normal luminal chyme and stool consistency respectively. No obstructive or overt infiltrative disease was noted. No associated abnormal lymphatic activity was noted.

SEX

Female

Pancreas

AGE

25 weeks

The base and limbs of the **pancreas** were observed to be largely isoechoic to surrounding omental fat. Pancreatic duct and capsular contour were acceptably normal and parenchyma respected normal curvilinear patterns. No overt evidence of active inflammatory or neoplastic disease was noted.

WEIGHT

32.5 lbs

ULTRASONOGRAPHIC FINDINGS

INTERPRETED BY

Eric Lindquist, DMV
DABVP, Cert. IVUSS

Structurally unremarkable abdomen.

IMAGING PERFORMED BY

Shane Stafford

INTERPRETATION OF THE FINDINGS & FURTHER RECOMMENDATIONS

There was no evidence of structural disease in the urinary tract or elsewhere in the abdomen. Examination of the vaginal vestibule is recommended for underlying pathology. There was no evidence of persistent urachocele or ectopic ureters.

HOSPITAL NAME

West Newton Animal
Clinic

REFERRING VET

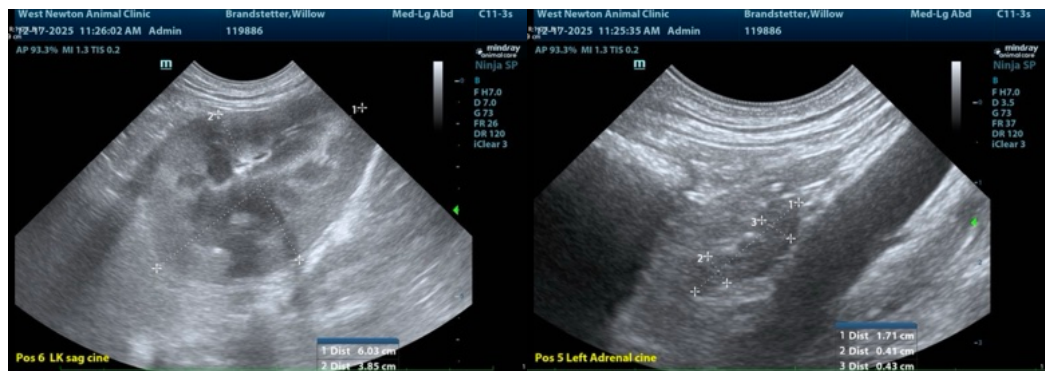
Dr. Brandon Holmes

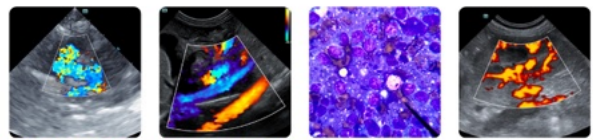
INVOICE

69393

DATE

12/17/25





PATIENT

Willow Brandsetter

SPECIES

Canine

BREED

Mix

SEX

Female

AGE

25 weeks

WEIGHT

32.5 lbs

INTERPRETED BY

Eric Lindquist, DMV
DABVP, Cert. IVUSS

IMAGING PERFORMED BY

Shane Stafford

HOSPITAL NAME

West Newton Animal
Clinic

REFERRING VET

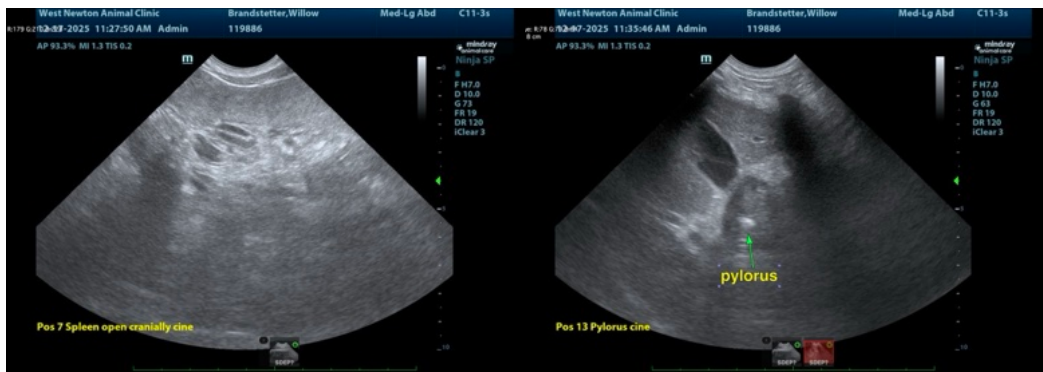
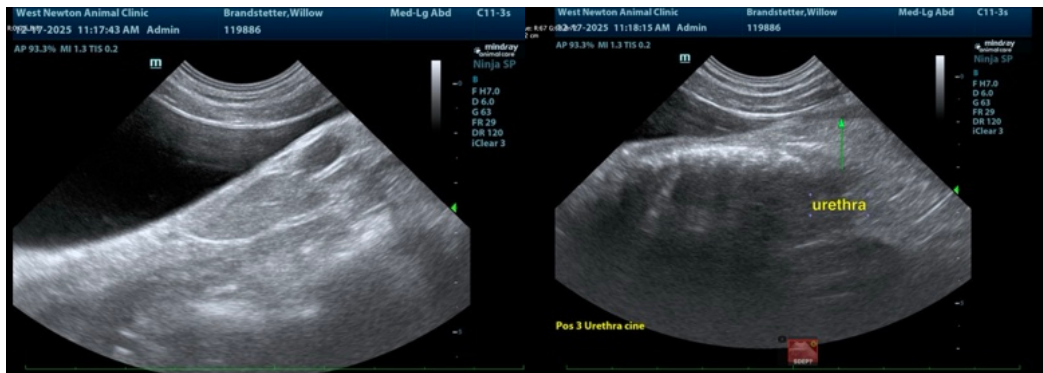
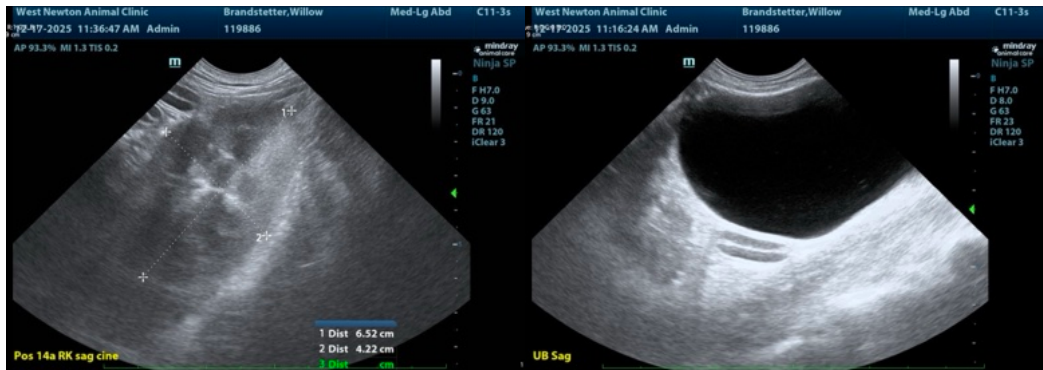
Dr. Brandon Holmes

INVOICE

69393

DATE

12/17/25



The information and recommendations provided are based on the images presented by the referring veterinarian/sonographer. No evaluation can be communicated regarding pathology that was not visible in the image/video clips provided.

Thank you for this referral. If the clinical or image interpretation does not parallel your findings or if I can be of any further assistance please contact me.

Eric Lindquist, DMV, DABVP (CFM), Cert. IVUSS, CEO of SonoPath.com

info@SonoPath.com