



## PATIENT

Volley Contis

## SPECIES

Canine

## BREED

Golden Retriever

## SEX

Spayed female

## AGE

6 years

## WEIGHT

67.8 lbs

## INTERPRETED BY

Eric Lindquist, DMV  
DABVP, Cert. IVUSS

## IMAGING PERFORMED BY

Susan Lincoski VMD

## HOSPITAL NAME

University Drive VH

## REFERRING VET

Dr. Lincoski

## INVOICE

69379

## DATE

12/17/25

## PRESENTING CLINICAL SIGNS

History: SEE 12/11 scan

## ULTRASONOGRAPHIC EXAMINATION

The stomach in this patient was free of evident pathology with a largely empty lumen other than minor gastric fluid accumulation. Some level of irritability is likely/low-grade gastritis. There was no evidence of neoplasia or foreign bodies. Some echogenic remodeling was noted in the pyloric mucosa.

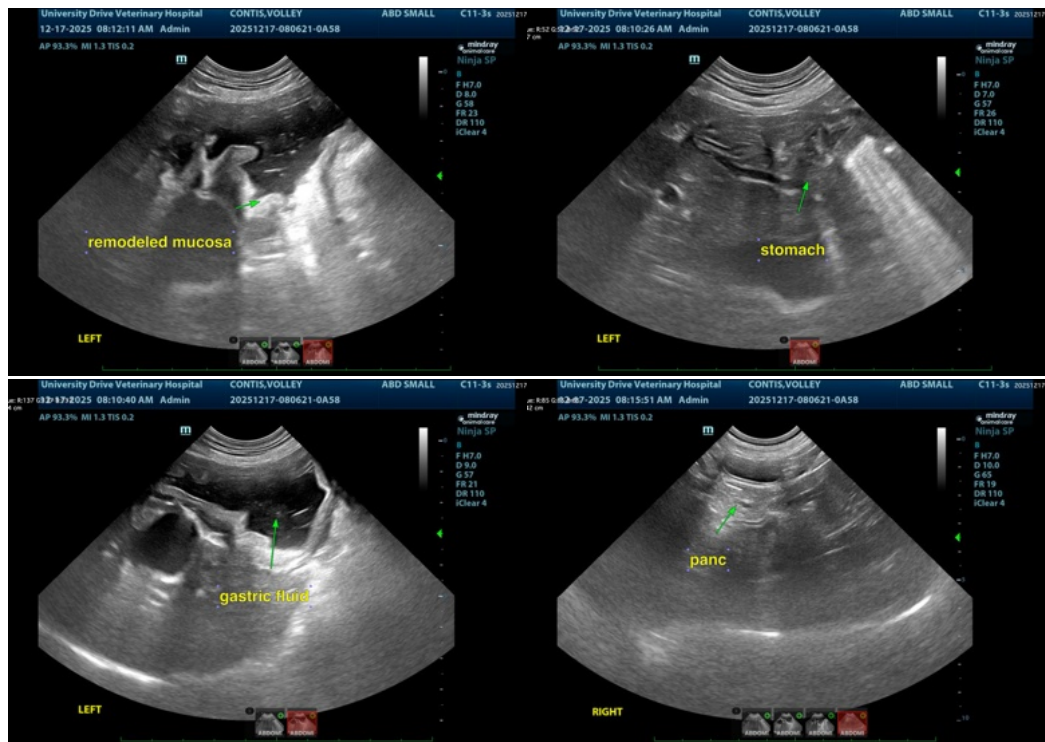
The right limb of the visible pancreas was normal.

## ULTRASONOGRAPHIC FINDINGS

Gastric fluid and mild residual gastritis pattern without evidence of foreign body.

## INTERPRETATION OF THE FINDINGS & FURTHER RECOMMENDATIONS

Management for GI irritability, Helicobacter and gastritis in general is indicated.



The information and recommendations provided are based on the images presented by the



## PATIENT

Volley Contis

## SPECIES

Canine

## BREED

Golden Retriever

## SEX

Spayed female

## AGE

6 years

## WEIGHT

67.8 lbs

## INTERPRETED BY

Eric Lindquist, DMV  
DABVP, Cert. IVUSS

## IMAGING PERFORMED BY

Susan Lincoski VMD

## HOSPITAL NAME

University Drive VH

## REFERRING VET

Dr. Lincoski

## INVOICE

69379

## DATE

12/17/25

referring veterinarian/sonographer. No evaluation can be communicated regarding pathology that was not visible in the image/video clips provided.

Thank you for this referral. If the clinical or image interpretation does not parallel your findings or if I can be of any further assistance please contact me.

Eric Lindquist, DMV, DABVP (CFM), Cert. IVUSS, CEO of SonoPath.com

[info@SonoPath.com](mailto:info@SonoPath.com)