



PATIENT

Lucy Belle Sadler

SPECIES

Canine

BREED

Havanese

SEX

Spayed female

AGE

7 years

WEIGHT

14.2 lbs

INTERPRETED BY

Eric Lindquist, DMV
DABVP, Cert. IVUSS

IMAGING PERFORMED BY

Dr. Betsy LaCroix

HOSPITAL NAME

Inspire Animal Hospital
Highlands Ranch

REFERRING VET

Dr. Betsy LaCroix

INVOICE

69385

DATE

12/17/25

PRESENTING CLINICAL SIGNS

History: Patient had a grade 3 STS that came up abruptly on L lateral thorax. It was surgically removed two weeks ago and had incomplete margins. Thoracic rads-unremarkable CBC today was wnl (she had a small petechia on her abdomen from rough housing with other dog in household, was ruling out any thrombocytopenia). No medications supplements. CBC/comprehensive/ua- unremarkable two weeks ago

Abnormal PE/Chem/CBC/UA Results: Healing incision on left lateral thorax. CBC was wnl today. Grade 3 soft tissue sarcoma on L lateral thorax with incomplete margins- met check/staging

ULTRASONOGRAPHIC EXAMINATION OF THE ABDOMEN

Urinary System

The **urinary bladder**, trigone, and pelvic urethra presented normal thicknesses and normal tone. The ureters were not visible which is normal. No uroliths or sediment were visualized and anechoic urine was present. No evidence of inflammatory or neoplastic changes was noted. Ureteral papillae were normal.

The **kidneys** revealed normal size and structure, corticomedullary definition and ratio for this age. The cortices presented largely uniform texture with normal echogenic relationship to liver and spleen. Medullary structure differed distinctly from the cortex and no evidence of pelvic dilation was present. The capsules were acceptably uniform without significant irregularities. The left kidney measured 4.4 cm. The right kidney measured 4.1 cm.

Adrenal Glands

Both **adrenal glands** were visualized and recognized as having normal shape, size, position and echogenicity for this breed. The phrenic vasculature, glandular echogenicity and detail were unremarkable. Capsule, cortex, and medullary definition were normal for this age patient. The left adrenal gland measured 0.37 cm at the caudal pole and 0.31 cm at the cranial pole. The right adrenal gland measured 0.47 cm at the caudal pole and 0.45 cm at the cranial pole.

Spleen

The **spleen** presented a smooth homogeneous parenchyma hyperechoic to liver and renal cortical parenchyma. The capsule was smooth without noticeable expansion or deviation from within the spleen or adjacent pathology. The splenic vasculature demonstrated normal volume without signs of congestion or thrombosis. No sonographic evidence of acute or chronic inflammatory, neoplastic, or infarctual changes was noted.

Liver

The **liver** images submitted revealed subjectively normal liver size, contour, and structure. Parenchymal echogenicity was naturally coarse and hypoechoic to the spleen. Vascular and biliary tracts were of



PATIENT

Lucy Belle Sadler

SPECIES

Canine

BREED

Havanese

SEX

Spayed female

AGE

7 years

WEIGHT

14.2 lbs

INTERPRETED BY

Eric Lindquist, DMV
DABVP, Cert. IVUSS

IMAGING PERFORMED BY

Dr. Betsy LaCroix

HOSPITAL NAME

Inspire Animal Hospital
Highlands Ranch

REFERRING VET

Dr. Betsy LaCroix

INVOICE

69385

DATE

12/17/25

normal volume with no evidence of congestion. The gallbladder presented acceptably thin walls with primarily anechoic content. The cystic and common bile ducts were normal. No pathological hepatic lymphadenopathy was evident. No overt structural evidence of inflammatory, infiltrative or regenerative pathology was evident.

Gastrointestinal

There was some residual chyme and gas was noted in the **stomach**, yet not pathological. This is consistent with post prandial presentation. Transit of chyme into the small intestine was normal. Curvilinear patterns were maintained throughout the GI tract. No evidence of pathology. Small and large intestine demonstrated normal luminal chyme and stool consistency respectively. No obstructive or overt infiltrative disease was noted. No associated abnormal lymphatic activity was noted.

Pancreas

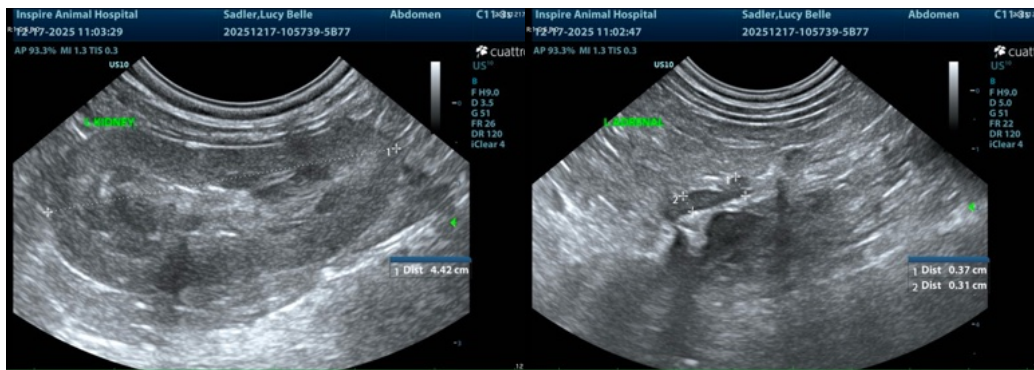
The base and limbs of the **pancreas** were observed to be largely isoechoic to surrounding omental fat. Pancreatic duct and capsular contour were acceptably normal and parenchyma respected normal curvilinear patterns. No overt evidence of active inflammatory or neoplastic disease was noted.

ULTRASONOGRAPHIC FINDINGS

Structurally unremarkable abdomen.
Post prandial type GI presentation.

INTERPRETATION OF THE FINDINGS & FURTHER RECOMMENDATIONS

There was no evidence of primary or metastatic disease.





PATIENT

Lucy Belle Sadler

SPECIES

Canine

BREED

Havanese

SEX

Spayed female

AGE

7 years

WEIGHT

14.2 lbs

INTERPRETED BY

Eric Lindquist, DMV
DABVP, Cert. IVUSS

IMAGING PERFORMED BY

Dr. Betsy LaCroix

HOSPITAL NAME

Inspire Animal Hospital
Highlands Ranch

REFERRING VET

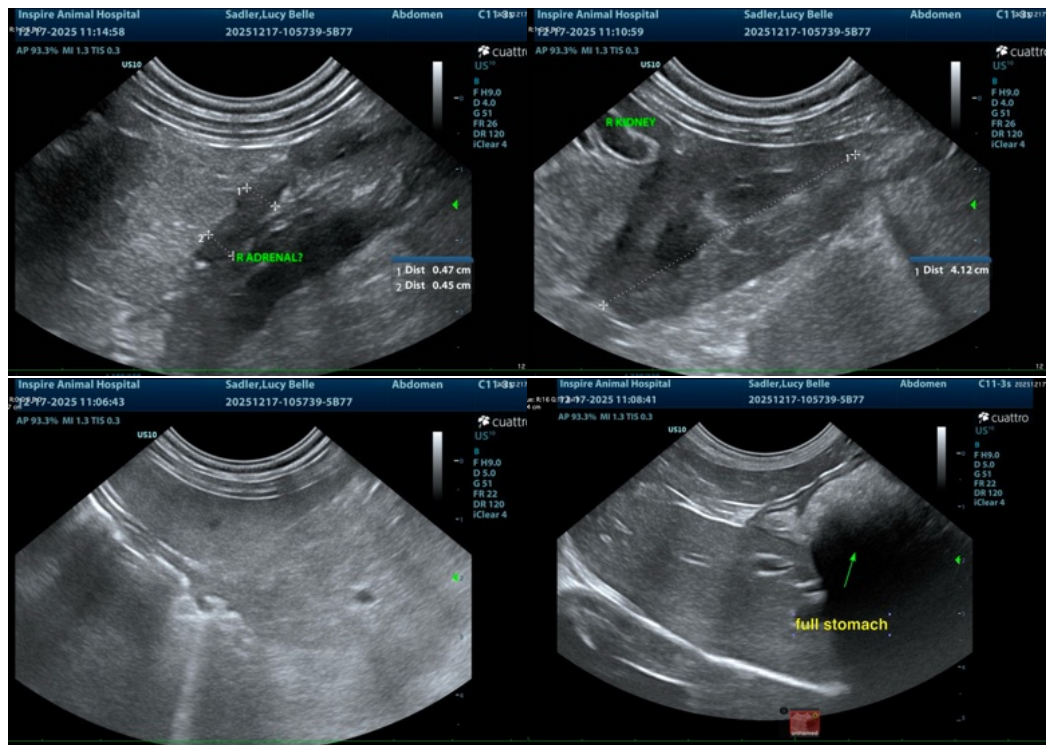
Dr. Betsy LaCroix

INVOICE

69385

DATE

12/17/25



The information and recommendations provided are based on the images presented by the referring veterinarian/sonographer. No evaluation can be communicated regarding pathology that was not visible in the image/video clips provided.

Thank you for this referral. If the clinical or image interpretation does not parallel your findings or if I can be of any further assistance please contact me.

Eric Lindquist, DMV, DABVP (CFM), Cert. IVUSS, CEO of SonoPath.com

info@SonoPath.com