



## PATIENT

Finn Jezyk

## SPECIES

Canine

## BREED

Norfolk Terrier

## SEX

Neutered male

## AGE

8 years

## WEIGHT

13.4 lbs

## INTERPRETED BY

Eric Lindquist, DMV  
DABVP, Cert. IVUSS

## IMAGING PERFORMED BY

Dr. Betsy LaCroix

## HOSPITAL NAME

Inspire AH Highlands

## REFERRING VET

Dr. Wolsky

## INVOICE

69391

## DATE

12/17/25

## PRESENTING CLINICAL SIGNS

History: Patient is being worked up for possible IBD. Chronic intermittent GI issues- gurgly stomach and intermitted soft stool Had ACTH stim test today because his resting cortisol was <2. on rx diet Previous u/s by different colleague showed duodenitis  
Abnormal PE/Chem/CBC/UA Results: BCS 4/9 Folate is slightly low on Texas GI profile O also reports possible UTI signs- u/a pending

## ULTRASONOGRAPHIC EXAMINATION OF THE ABDOMEN

### Urinary System

The **urinary bladder**, trigone, and pelvic urethra presented normal thicknesses and normal tone. The ureters were not visible which is normal. No uroliths or sediment were visualized and anechoic urine was present. No evidence of inflammatory or neoplastic changes was noted. Ureteral papillae were normal.

The **kidneys** revealed normal size and structure, corticomedullary definition and ratio for this age. The cortices presented largely uniform texture with normal echogenic relationship to liver and spleen. Medullary structure differed distinctly from the cortex and no evidence of pelvic dilation was present. The capsules were acceptably uniform without significant irregularities. Slight pinpoint mineralization was noted. The left kidney measured 3.5 cm. The right kidney measured 3.6 cm.

### Adrenal Glands

Both **adrenal glands** were visualized and recognized as having normal shape, size, position and echogenicity for this breed. The phrenic vasculature, glandular echogenicity and detail were unremarkable. Capsule, cortex, and medullary definition were normal for this age patient. The left adrenal gland measured 0.47 cm at the caudal pole and 0.38 cm at the cranial pole. The right adrenal gland measured 0.51 cm at the caudal pole and 0.48 cm at the cranial pole.

### Spleen

The **spleen** presented a smooth homogeneous parenchyma hyperechoic to liver and renal cortical parenchyma. The capsule was smooth without noticeable expansion or deviation from within the spleen or adjacent pathology. The splenic vasculature demonstrated normal volume without signs of congestion or thrombosis. No sonographic evidence of acute or chronic inflammatory, neoplastic, or infarctual changes was noted.

### Liver

The **liver** images submitted revealed subjectively normal liver size, contour, and structure. Parenchymal echogenicity was naturally coarse and hypoechoic to the spleen. Vascular and biliary tracts were of normal volume with no evidence of congestion. The gallbladder presented acceptably thin walls with primarily anechoic content. The cystic and common bile ducts were normal. No pathological hepatic



**PATIENT**

lymphadenopathy was evident. No overt structural evidence of inflammatory, infiltrative or regenerative pathology was evident.

Finn Jezyk

**SPECIES**

**Gastrointestinal**

Canine

Examination of the **gastrointestinal tract** revealed a stomach and intestine free of stasis, of normal wall thickness, acceptable curvilinear mural detail, and peristaltic activity. Small and large intestine demonstrated normal luminal chyme and stool consistency respectively. No obstructive or overt infiltrative disease was noted. No associated abnormal lymphatic activity was noted.

**BREED**

Norfolk Terrier

**SEX**

**Pancreas**

Neutered male

The base and limbs of the **pancreas** were observed to be largely isoechoic to surrounding omental fat. Pancreatic duct and capsular contour were acceptably normal and parenchyma respected normal curvilinear patterns. No overt evidence of active inflammatory or neoplastic disease was noted.

**AGE**

8 years

**WEIGHT**

**ULTRASONOGRAPHIC FINDINGS**

13.4 lbs

Structurally unremarkable abdomen.

**INTERPRETED BY**

**INTERPRETATION OF THE FINDINGS & FURTHER RECOMMENDATIONS**

Eric Lindquist, DMV  
DABVP, Cert. IVUSS

Given the subnormal baseline cortisol, full ACTH stimulation is warranted, yet there was no evidence of structural disease. Occasionally absence can occur with measurably normal adrenal glands. Hydrolyzed diet is indicated in this patient as well as parasite management. Underlying food intolerance is likely an issue.

**IMAGING PERFORMED BY**

Dr. Betsy LaCroix

**HOSPITAL NAME**

Inspire AH Highlands

**REFERRING VET**

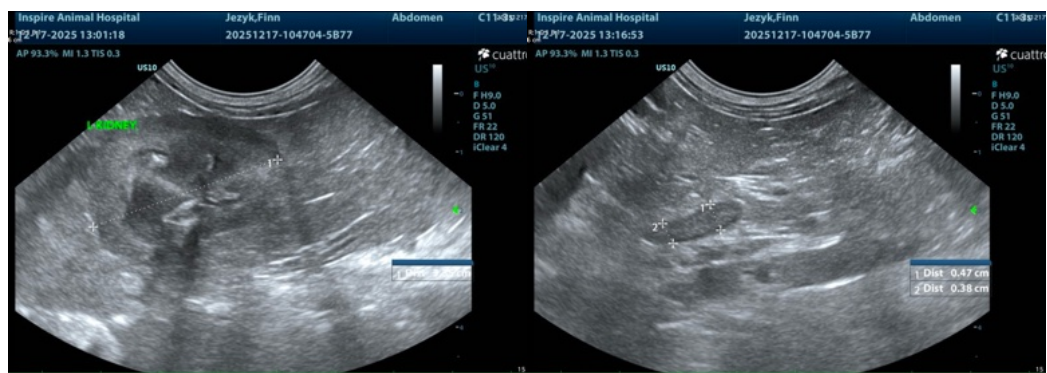
Dr. Wolsky

**INVOICE**

69391

**DATE**

12/17/25





## PATIENT

Finn Jezyk

## SPECIES

Canine

## BREED

Norfolk Terrier

## SEX

Neutered male

## AGE

8 years

## WEIGHT

13.4 lbs

## INTERPRETED BY

Eric Lindquist, DMV  
DABVP, Cert. IVUSS

## IMAGING PERFORMED BY

Dr. Betsy LaCroix

## HOSPITAL NAME

Inspire AH Highlands

## REFERRING VET

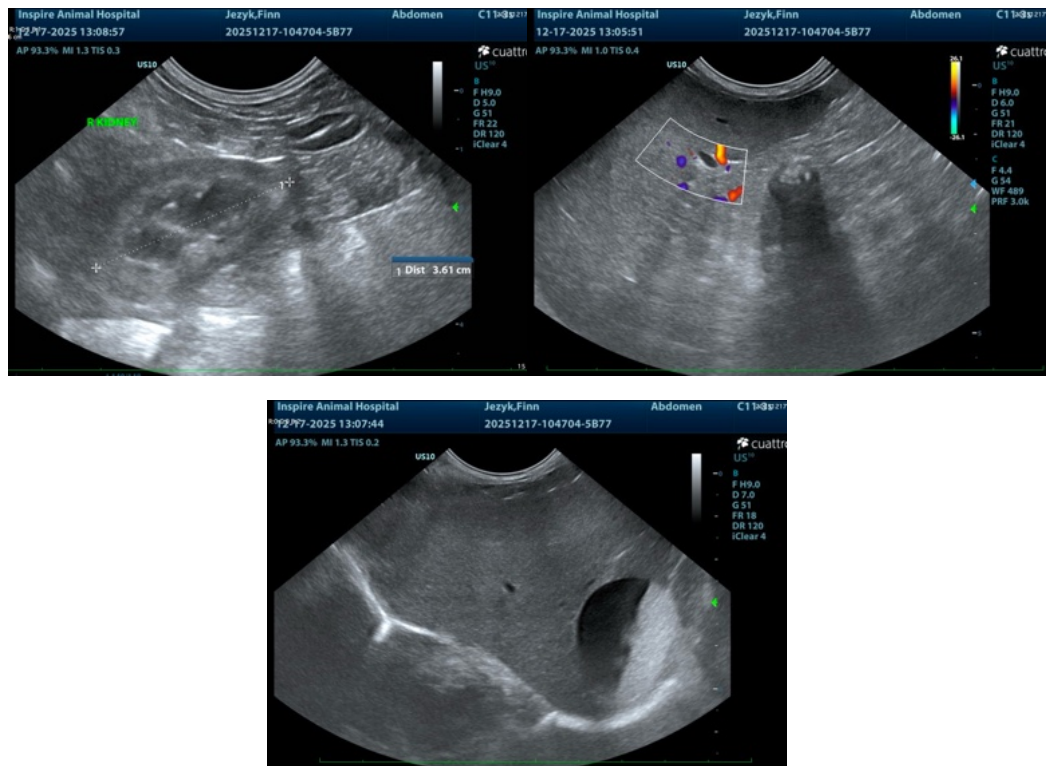
Dr. Wolsky

## INVOICE

69391

## DATE

12/17/25



The information and recommendations provided are based on the images presented by the referring veterinarian/sonographer. No evaluation can be communicated regarding pathology that was not visible in the image/video clips provided.

Thank you for this referral. If the clinical or image interpretation does not parallel your findings or if I can be of any further assistance please contact me.

Eric Lindquist, DMV, DABVP (CFM), Cert. IVUSS, CEO of SonoPath.com

[info@SonoPath.com](mailto:info@SonoPath.com)