



PATIENT

Cheddar Wei

SPECIES

Canine

BREED

Dachshund

SEX

Intact male

AGE

1 year

WEIGHT

13.4 lbs

PRESENTING CLINICAL SIGNS

History: General pre-surgical bloodwork for neuter found elevation to liver values. No symptoms or concerns at home, physical exam unremarkable. Plan to perform pre and post prandial bile acids test. Abnormal PE/Chem/CBC/UA Results: 11/25/25 CBC/Chem: ALT 194 U/L (18-121), AST 57 U/L (16-55) -T.bili and ALP within normal range

ULTRASONOGRAPHIC EXAMINATION OF THE ABDOMEN

Urinary System

The **urinary bladder**, trigone, and pelvic urethra presented normal thicknesses and normal tone. The ureters were not visible which is normal. No uroliths or sediment were visualized and anechoic urine was present. No evidence of inflammatory or neoplastic changes was noted. Ureteral papillae were normal.

The **kidneys** revealed normal size and structure, corticomedullary definition and ratio for this age. The cortices presented largely uniform texture with normal echogenic relationship to liver and spleen. Medullary structure differed distinctly from the cortex and no evidence of pelvic dilation was present. The capsules were acceptably uniform without significant irregularities. The left kidney measured 3.9 cm. The right kidney measured 4.8 cm.

INTERPRETED BY

Eric Lindquist, DMV
DABVP, Cert. IVUSS

Adrenal Glands

Both **adrenal glands** were visualized and recognized as having normal shape, size, position and echogenicity for this breed. The phrenic vasculature, glandular echogenicity and detail were unremarkable. Capsule, cortex, and medullary definition were normal for this age patient. The right adrenal gland measured 0.5 cm. The left adrenal gland measured 0.5 cm.

IMAGING PERFORMED BY

Sandra Jimenez

Spleen

HOSPITAL NAME

Bramer AH

The **spleen** in this patient was mildly enlarged with uniform parenchyma and was folded upon itself cranially. This is a positional variant and is not pathological. There was no evidence of significant disease.

REFERRING VET

Dr. Jimenez

Liver

INVOICE

69384

The **liver** images submitted revealed subjectively normal liver size, contour, and structure. Parenchymal echogenicity was naturally coarse and hypoechoic to the spleen. Vascular and biliary tracts were of normal volume with no evidence of congestion. The gallbladder presented acceptably thin walls with primarily anechoic content. The cystic and common bile ducts were normal. No pathological hepatic lymphadenopathy was evident. No overt structural evidence of inflammatory, infiltrative or regenerative pathology was evident.

DATE

12/17/25



PATIENT

Cheddar Wei

SPECIES

Canine

BREED

Dachshund

SEX

Intact male

AGE

1 year

WEIGHT

13.4 lbs

INTERPRETED BY

Eric Lindquist, DMV
DABVP, Cert. IVUSS

IMAGING PERFORMED BY

Sandra Jimenez

HOSPITAL NAME

Bramer AH

REFERRING VET

Dr. Jimenez

INVOICE

69384

DATE

12/17/25

Gastrointestinal

There was some residual chyme and gas was noted in the **stomach**, yet not pathological. This is consistent with post prandial presentation. Transit of chyme into the small intestine was normal. Curvilinear patterns were maintained throughout the GI tract. No evidence of pathology. Small and large intestine demonstrated normal luminal chyme and stool consistency respectively. No obstructive or overt infiltrative disease was noted. No associated abnormal lymphatic activity was noted.

Pancreas

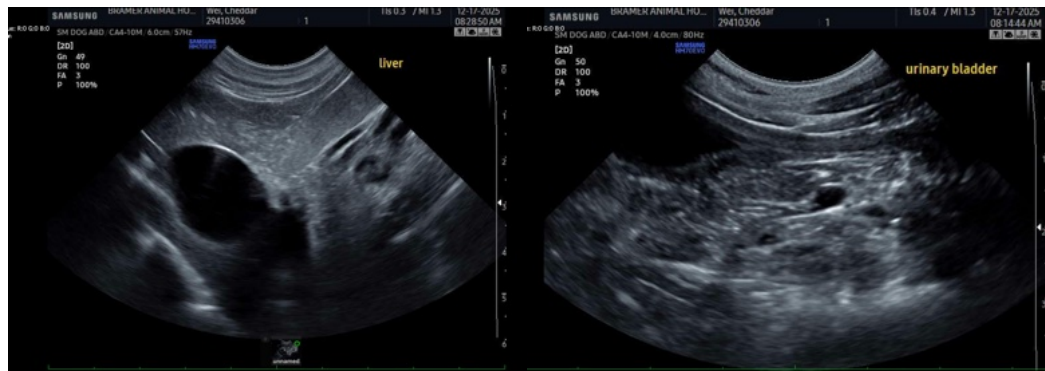
The base and limbs of the **pancreas** were observed to be largely isoechoic to surrounding omental fat. Pancreatic duct and capsular contour were acceptably normal and parenchyma respected normal curvilinear patterns. No overt evidence of active inflammatory or neoplastic disease was noted.

ULTRASONOGRAPHIC FINDINGS

Structurally unremarkable liver, no evidence of pathology.

INTERPRETATION OF THE FINDINGS & FURTHER RECOMMENDATIONS

The patient likely has mild reactive hepatopathy. No contraindication to anesthetic procedure based on the abdominal presentation.





PATIENT

Cheddar Wei

SPECIES

Canine

BREED

Dachshund

SEX

Intact male

AGE

1 year

WEIGHT

13.4 lbs

INTERPRETED BY

Eric Lindquist, DMV
DABVP, Cert. IVUSS

IMAGING PERFORMED BY

Sandra Jimenez

HOSPITAL NAME

Bramer AH

REFERRING VET

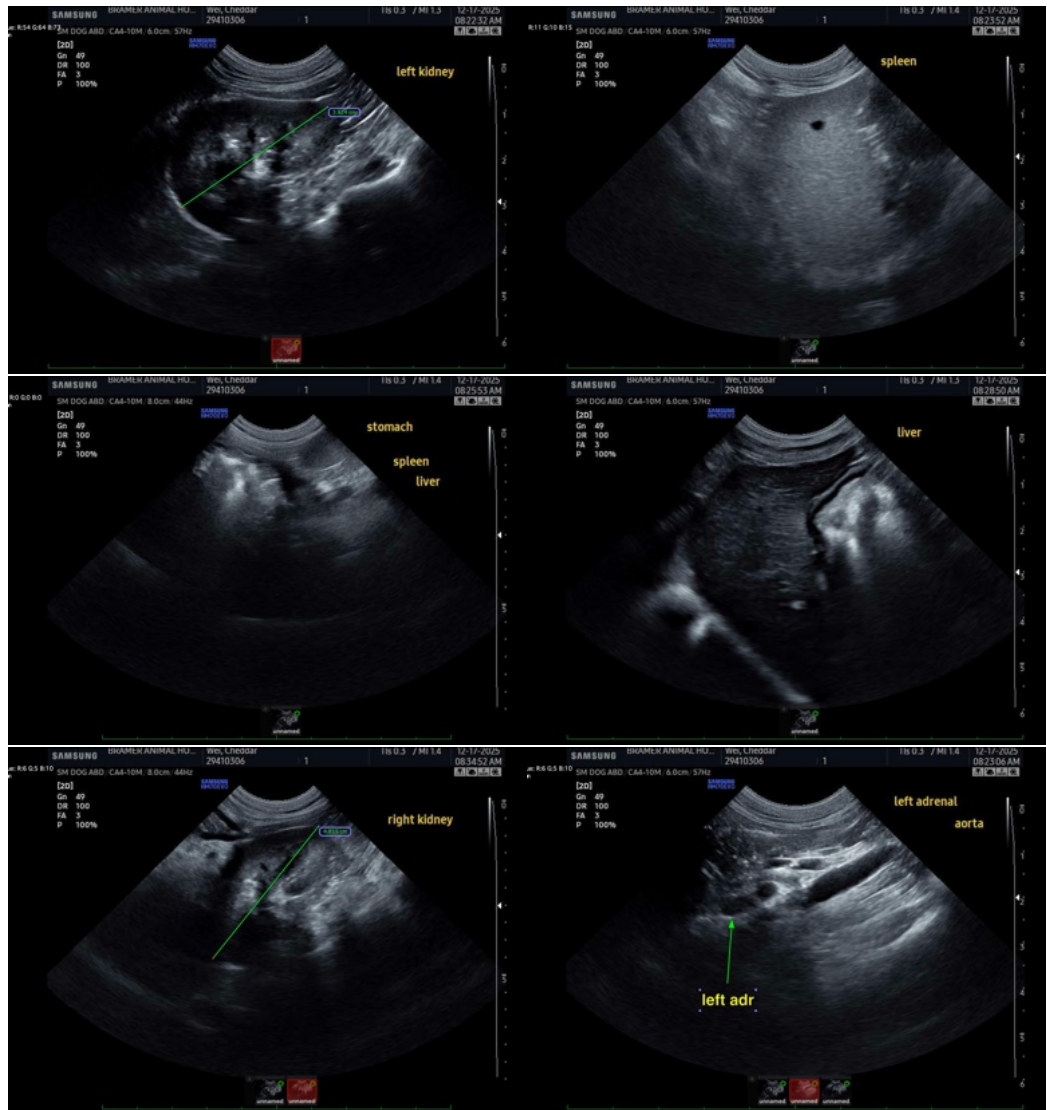
Dr. Jimenez

INVOICE

69384

DATE

12/17/25



The information and recommendations provided are based on the images presented by the referring veterinarian/sonographer. No evaluation can be communicated regarding pathology that was not visible in the image/video clips provided.

Thank you for this referral. If the clinical or image interpretation does not parallel your findings or if I can be of any further assistance please contact me.

Eric Lindquist, DMV, DABVP (CFM), Cert. IVUSS, CEO of SonoPath.com

info@SonoPath.com