



PATIENT

Big Foot Harris

SPECIES

Feline

BREED

Domestic Longhair

SEX

Neutered male

AGE

12 years

WEIGHT

10 lbs

INTERPRETED BY

Eric Lindquist, DMV
DABVP, Cert. IVUSS

IMAGING PERFORMED BY

Dr. Goodman

HOSPITAL NAME

Evendale Blue Ash Pet
Hospital

REFERRING VET

Dr. Wehmer

INVOICE

69398

DATE

12/17/25

PRESENTING CLINICAL SIGNS

History: Chronic diarrhea Wt. loss Inappetence anemia of chronic dz Current meds: Prednisolone 2.5mg SID transdermal Benazapril 2.5mg SID transdermal Mirtazapine transdermal PRN Hx of doxycycline (12/2024 - 6 week course) and marbofloxacin (9/2025 - 2 week course)
Abnormal PE/Chem/CBC/UA Results: BW 12/2024 - anemic, mycoplasma haemofelis, mycoplasma haemominutum, and candidatus mycoplasma turicensis positive 8/2025 - mycoplasma haemofelis and candidatus mycoplasma turicensis- negative Mycoplasma haemominutum positive Anemia resolved 12/2025 - RBC dropped but stable, low calcium and albumin, Drew sample and have it stored for possible TAMU GI panel pending us report. Patient is FIV positive

ULTRASONOGRAPHIC EXAMINATION OF THE ABDOMEN

Urinary System

The **urinary bladder**, trigone, and pelvic urethra presented normal thicknesses and normal tone. The pelvic urethra was imaged 1.0 cm beyond the cystourethral junction and appeared normal. The ureters were not visible which is normal. A minor amount of suspended debris was noted. No evidence of inflammatory or neoplastic changes was noted. Ureteral papillae were normal.

The **kidneys** revealed normal size and structure, corticomedullary definition and ratio for this age. The cortices presented largely uniform texture with normal echogenic relationship to liver and spleen. Medullary structure differed distinctly from the cortex and no evidence of pelvic dilation was present. The capsules were acceptably uniform without significant irregularities. The left kidney measured 4.42 cm. The right kidney measured 4.04 cm.

Adrenal Glands

Both **adrenal glands** were visualized and recognized as having normal shape, size, position and echogenicity for this breed. The phrenic vasculature, glandular echogenicity and detail were unremarkable. Capsule, cortex, and medullary definition were normal for this age patient. The left and right adrenal gland measured 0.4 cm.

Spleen

The **spleen** was enlarged with scalloping contour and uniform parenchyma measuring up to 1.7 cm in width. Ultrasound-guided FNA is strongly recommended. Micronodular changes were noted in the spleen.

Liver

The **liver** images submitted revealed subjectively normal liver size, contour, and structure. Parenchymal echogenicity was naturally coarse and hypoechoic to the spleen. Vascular and biliary tracts were of normal volume with no evidence of congestion. The gallbladder presented acceptably thin walls with



PATIENT

Big Foot Harris

primarily anechoic content. The cystic and common bile ducts were normal. No pathological hepatic lymphadenopathy was evident. No overt structural evidence of inflammatory, infiltrative or regenerative pathology was evident.

SPECIES

Feline

Gastrointestinal

BREED

Domestic Longhair

The **stomach** was filled with progressively shadowing material. This is consistent with hairball density. The small intestines and colon were unremarkable with normal curvilinear mural patterns and content.

SEX

Neutered male

Pancreas

AGE

12 years

The base and limbs of the **pancreas** were observed to be largely isoechoic to surrounding omental fat. Some parenchymal remodeling, however, with mild deviation from curvilinear normalcy was observed. Pancreatic duct and capsular irregularities were present consistent with age related changes. If pain upon imaging (+ Murphy sign) was present or if the patient is focally painful in subxiphoid palpation then low-grade smoldering chronic pancreatitis should be suspected.

WEIGHT

10 lbs

ULTRASONOGRAPHIC FINDINGS

INTERPRETED BY

Eric Lindquist, DMV
DABVP, Cert. IVUSS

Micronodular splenomegaly, concern for round cell neoplasia versus splenitis.

IMAGING PERFORMED BY

Dr. Goodman

INTERPRETATION OF THE FINDINGS & FURTHER RECOMMENDATIONS

Ultrasound-guided 25-gauge FNA cytology and culture of the spleen is indicated. I am most concerned about the spleen in this patient. Hairball management would be warranted. There was no overt evidence of neoplasia other than potentially the spleen. Prednisone may be suppressing a more significant presentation. I strongly recommend 25-gauge FNA cytology and culture of the spleen. Hairball management is warranted in the meantime. CBC path review +/- bone marrow aspirate would be appropriate given the anemia. Prognosis is guarded depending upon further diagnostic results.

HOSPITAL NAME

Evendale Blue Ash Pet
Hospital

REFERRING VET

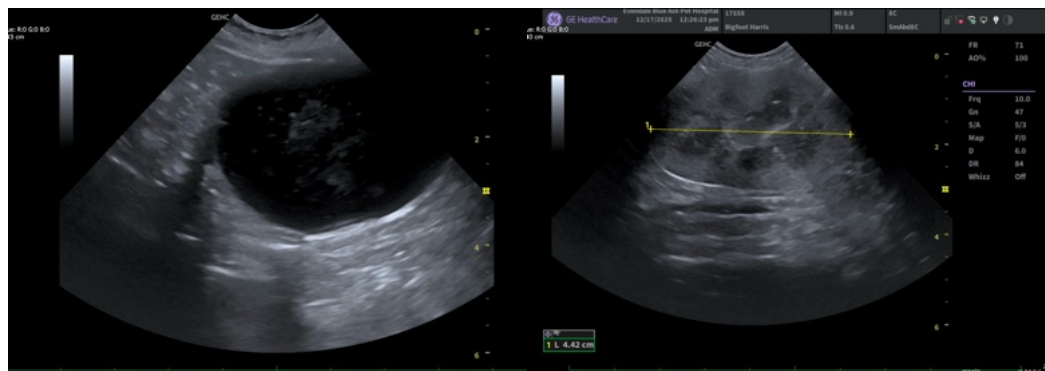
Dr. Wehmer

INVOICE

69398

DATE

12/17/25





PATIENT

Big Foot Harris

SPECIES

Feline

BREED

Domestic Longhair

SEX

Neutered male

AGE

12 years

WEIGHT

10 lbs

INTERPRETED BY

Eric Lindquist, DMV
DABVP, Cert. IVUSS

IMAGING PERFORMED BY

Dr. Goodman

HOSPITAL NAME

Evendale Blue Ash Pet
Hospital

REFERRING VET

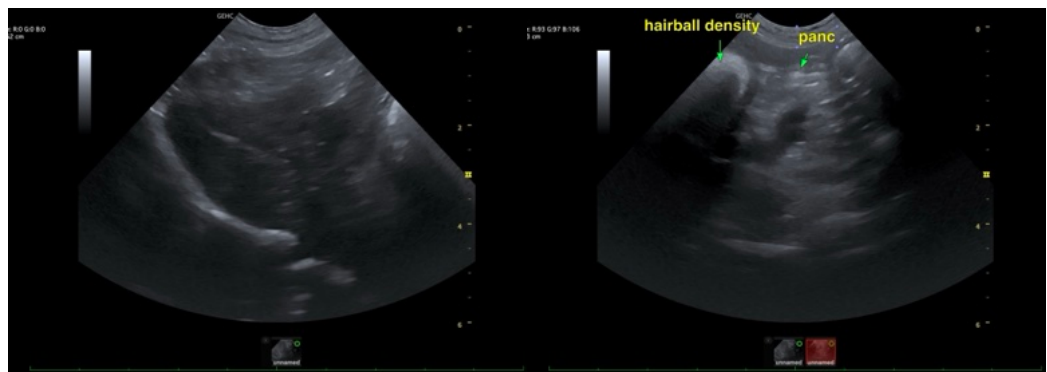
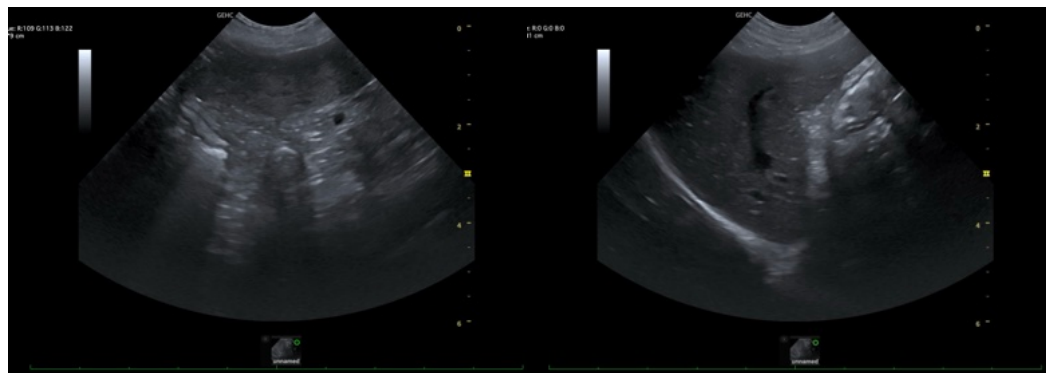
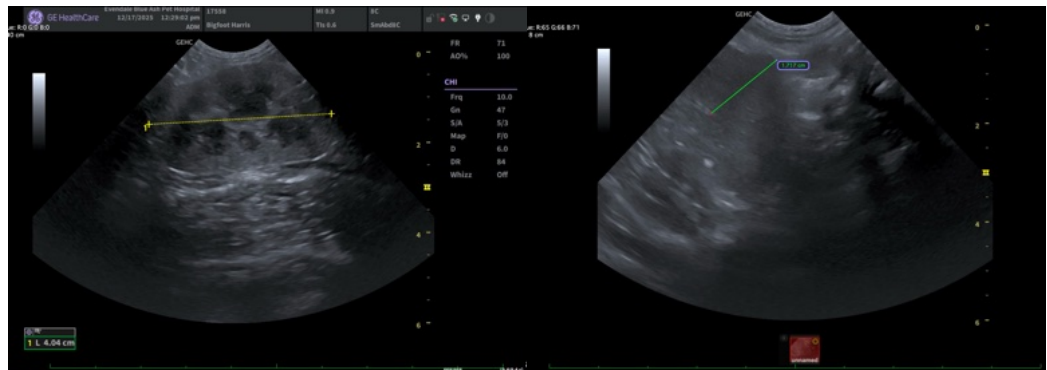
Dr. Wehmer

INVOICE

69398

DATE

12/17/25



The information and recommendations provided are based on the images presented by the referring veterinarian/sonographer. No evaluation can be communicated regarding pathology that was not visible in the image/video clips provided.

Thank you for this referral. If the clinical or image interpretation does not parallel your findings or if I can be of any further assistance please contact me.

Eric Lindquist, DMV, DABVP (CFM), Cert. IVUSS, CEO of SonoPath.com

info@SonoPath.com