


PATIENT

Wormie Impell

PRESENTING CLINICAL SIGNS

 concern for cardiomegaly and interstitial edema. Furosemide 12.5 mg sid started yesterday
 Abnormal PE/Chem/CBC/UA Results: WBC 20.6 with elevated neuts 16892; glucose 215, Mg 1.1

SPECIES

Feline

ULTRASONOGRAPHIC EXAMINATION OF THE HEART
BREED

DSH

SEX

Spayed Female

AGE

14 Years

WEIGHT

N/A

FELINE CARDIAC PARAMETERS	BODY WEIGHT (kg)	HR (BPM)	IVSd (cm)	LVIDd (cm)	LVWd (cm)	FS (%)	EF (%)
NORMAL PARAMETER	-----	150-240	0.3-0.6	1.0-2.1	0.25-0.6	35-67	80-100
PATIENT		175	0.38	1.49	0.39	41	76
FELINE CARDIAC PARAMETERS	LA/AO (Boon)	LA/AO HEART BASE (Sisson)	LA 2D 4-chamber long axis AS to FW (Sisson) (cm)		LVOT VEL. (m/s)	RVOT VEL. (m/s)	IVRT (m/)
NORMAL PARAMETER	<1.5	0.88-1.79	0.7-1.7		<1.6	<1.3	40-60
PATIENT	1.76	1.8	1.93			0.7	NM

 Adapted from June Boon, Veterinary Echocardiography, 1998
 Sisson D et al. JVIM 1991; 5: 232, Jacobs et al. Am J Vet Res 1985; 46:1705

Cardiac Presentation

The cardiac presentation revealed severe volume overload in the left atrium and left ventricle with hypocontractility and arrhythmogenic disease. Pericardial effusion noted. The echocardiogram was performed rapidly owing to the precarious nature of the presentation and respiratory distress of the patient. Mitral insufficiency noted. Tricuspid insufficiency noted at 2.6 m/sec. Normal septal and free wall thicknesses. Hepatic veins were dilated. Lung fields presented B-lines.

INTERPRETED BY

 Eric Lindquist, DMV
 DABVP, Cert. IVUSS

IMAGING PERFORMED BY

Diane McFadden

HOSPITAL NAME

Newton Vet Hospital

REFERRING VET

Dr. Barron

ULTRASONOGRAPHIC FINDINGS

- Unclassified cardiomyopathy with left- and right-sided heart failure

INTERPRETATION OF THE FINDINGS & FURTHER RECOMMENDATIONS

Recommend triple therapy in this patient. Lasix 12.5 mg BID, ACE inhibitor 0.5 mg/kg SID, and Pimobendan 0.3 mg/kg BID, off-label Plavix therapy also indicated. 48-72 hour cage rest. Oxygen as necessary. This patient is at risk for sudden death, yet may be stabilized under the prescribed protocol. Recheck echo in 7-10 days if the patient survives the current event. BUN, creatinine, blood pressures, body temperature should all be monitored carefully over the next 48-72 hours.

INVOICE

33525

DATE

12/17/21



PATIENT

Wormie Impell

SPECIES

Feline

BREED

DSH

SEX

Spayed Female

AGE

14 Years

WEIGHT

N/A

INTERPRETED BY

Eric Lindquist, DMV
DABVP, Cert. IVUSS

IMAGING PERFORMED BY

Diane McFadden

HOSPITAL NAME

Newton Vet Hospital

REFERRING VET

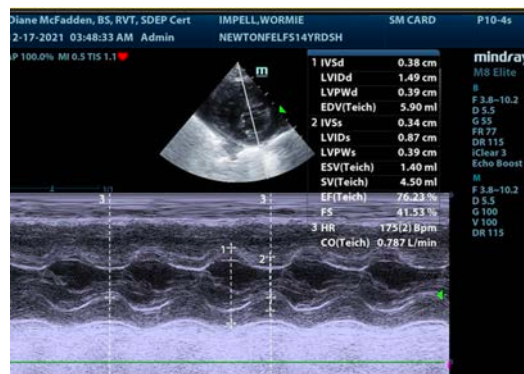
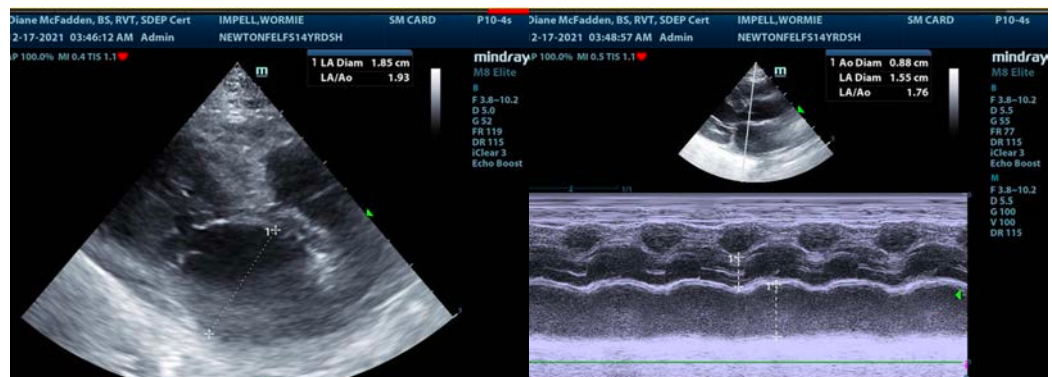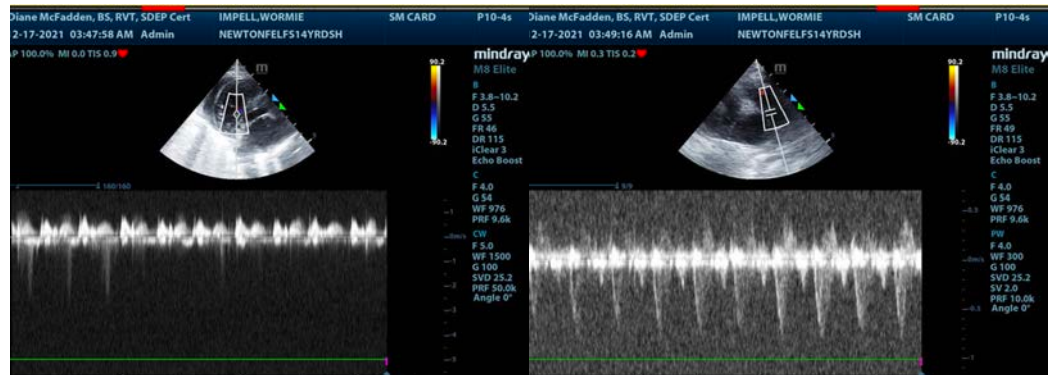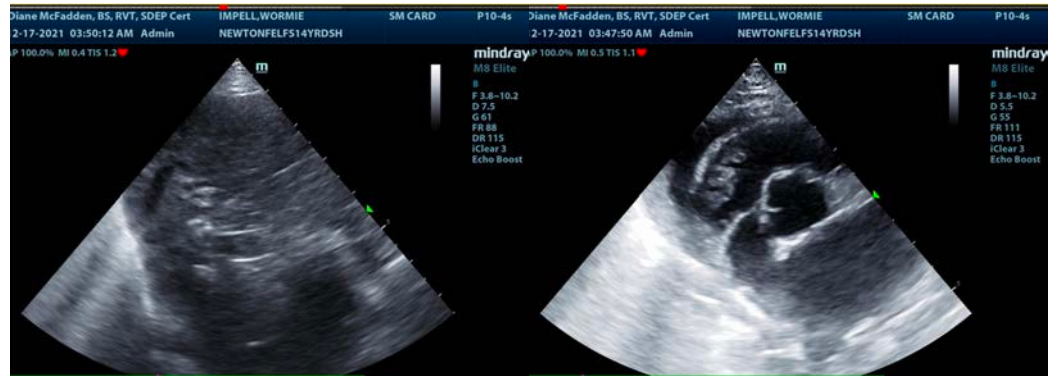
Dr. Barron

INVOICE

33525

DATE

12/17/21





PATIENT

Wormie Impell

The information and recommendations provided are based on the images presented by the referring veterinarian. No evaluation can be communicated regarding pathology that was not visible in the image/video clips provided.

SPECIES

Feline

Thank you for this referral. If the clinical or image interpretation does not parallel your findings or if I can be of any further assistance please contact me.

BREED

DSH

Eric Lindquist, DMV, DABVP, Cert. IVUSS, CEO of SonoPath.com

info@SonoPath.com

SEX

Spayed Female

AGE

14 Years

WEIGHT

N/A

INTERPRETED BY

Eric Lindquist, DMV
DABVP, Cert. IVUSS

**IMAGING
PERFORMED BY**

Diane McFadden

HOSPITAL NAME

Newton Vet Hospital

REFERRING VET

Dr. Barron

INVOICE

33525

DATE

12/17/21