



PATIENT

Belle Morris

PRESENTING CLINICAL SIGNS

Not eating. Hx of vomiting hairballs daily. Dental disease.
Abnormal PE/Chem/CBC/UA Results: CBC okay, Chemistry WNL, UA bacteria PMNs. Treated for UTI with Convenia and Cerenia. Cleaned teeth and extracted two bad ones.

SPECIES

Feline

ULTRASONOGRAPHIC EXAMINATION OF THE ABDOMEN

Urinary System

The **urinary bladder**, trigone, and pelvic urethra presented normal thicknesses and normal tone. The ureters were not visible which is normal. No uroliths or sediment were visualized and anechoic urine was present. No evidence of inflammatory or neoplastic changes was noted. Ureteral papillae were normal.

BREED

Domestic Shorthair

SEX

Spayed Female

The **kidneys** revealed normal size and structure, corticomedullary definition and ratio for this age. The cortices presented largely uniform texture with normal echogenic relationship to liver and spleen. Medullary structure differed distinctly from the cortex and no evidence of pelvic dilation was present. The capsules were acceptably uniform without significant irregularities. The left kidney measured 4.0 cm. The right kidney measured 4.0 cm.

AGE

8 years

WEIGHT

7 lbs

Adrenal Glands

Both **adrenal glands** were visualized and recognized as having normal shape, size, position and echogenicity for this breed. The phrenic vasculature, glandular echogenicity and detail were unremarkable. Capsule, cortex, and medullary definition were normal for this age patient.

INTERPRETED BY

Eric Lindquist, DMV
DABVP, Cert. IVUSS

Spleen

The **spleen** presented a smooth homogeneous parenchyma hyperechoic to liver and renal cortical parenchyma. The capsule was smooth without noticeable expansion or deviation from within the spleen or adjacent pathology. The splenic vasculature demonstrated normal volume without signs of congestion or thrombosis. No sonographic evidence of acute or chronic inflammatory, neoplastic, or infarctual changes was noted.

IMAGING PERFORMED BY

Dr. Beard

HOSPITAL NAME

West Prince AH

Liver

The **liver** images submitted revealed subjectively normal liver size, contour, and structure. Parenchymal echogenicity was naturally coarse and hypoechoic to the spleen. Vascular and biliary tracts were of normal volume with no evidence of congestion. The gallbladder presented acceptably thin walls with primarily anechoic content. The cystic and common bile ducts were normal. No pathological hepatic lymphadenopathy was evident. No overt structural evidence of inflammatory, infiltrative or regenerative pathology was evident.

REFERRING VET

Dr. Beard

INVOICE

94716

DATE

12/17/21



PATIENT

Gastrointestinal

Belle Morris

The **stomach** was empty other than a minor amount of fluid accumulation. Curvilinear mural patterns were maintained. Minor small intestinal thickening was noted with increased submucosal echogenicity and muscularis hypertrophy. The changes were exceedingly minor.

SPECIES

Feline

Pancreas

BREED

Domestic Shorthair

The base and limbs of the **pancreas** were observed to be largely isoechoic to surrounding omental fat. Pancreatic duct and capsular contour were acceptably normal and parenchyma respected normal curvilinear patterns. No overt evidence of active inflammatory or neoplastic disease was noted.

SEX

Spayed Female

ULTRASONOGRAPHIC FINDINGS

Structurally unremarkable abdomen.

AGE

8 years

Minor IBD GI pattern.

WEIGHT

7 lbs

INTERPRETATION OF THE FINDINGS & FURTHER RECOMMENDATIONS

There was no evidence of significant disease. Pain management could be considered given the patient's history. The clinical relevance to this current presentation is unclear.

INTERPRETED BY

Eric Lindquist, DMV
DABVP, Cert. IVUSS

IMAGING PERFORMED BY

Dr. Beard

HOSPITAL NAME

West Prince AH

REFERRING VET

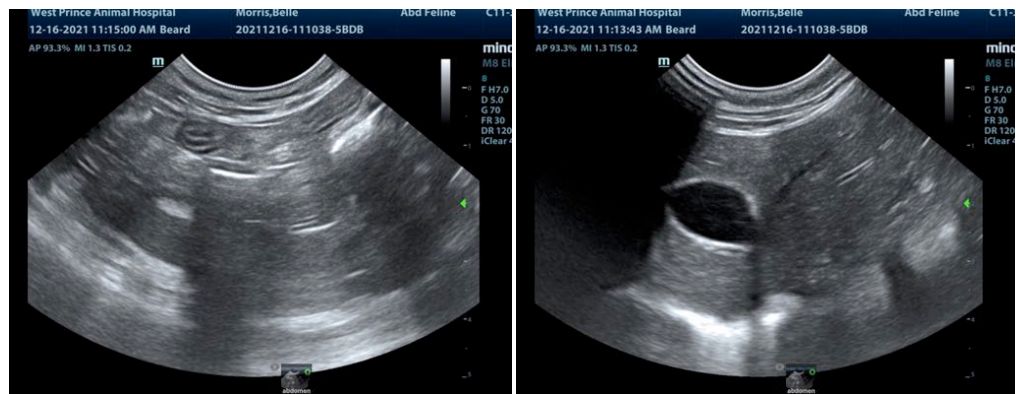
Dr. Beard

INVOICE

94716

DATE

12/17/21





PATIENT

Belle Morris

SPECIES

Feline

BREED

Domestic Shorthair

SEX

Spayed Female

AGE

8 years

WEIGHT

7 lbs

INTERPRETED BY

Eric Lindquist, DMV
DABVP, Cert. IVUS

IMAGING PERFORMED BY

Dr. Beard

HOSPITAL NAME

West Prince AH

REFERRING VET

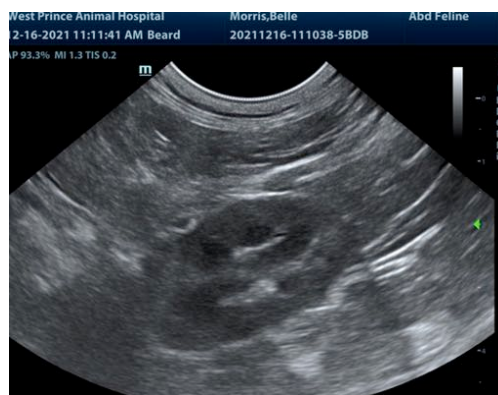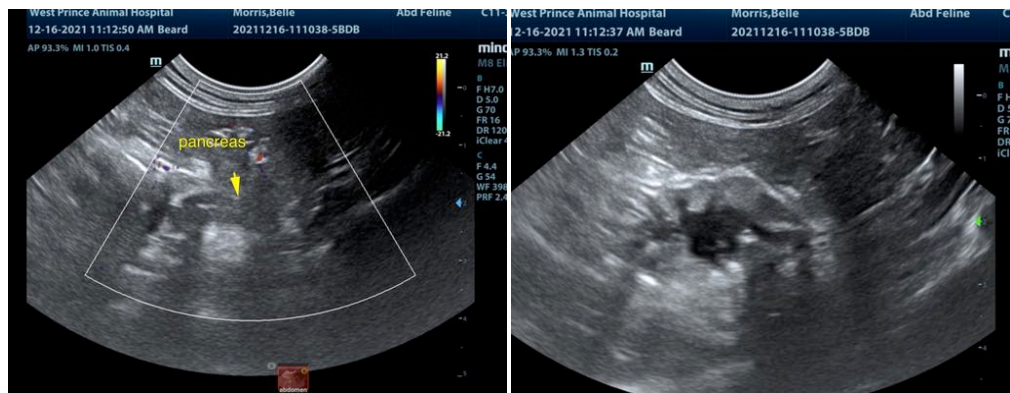
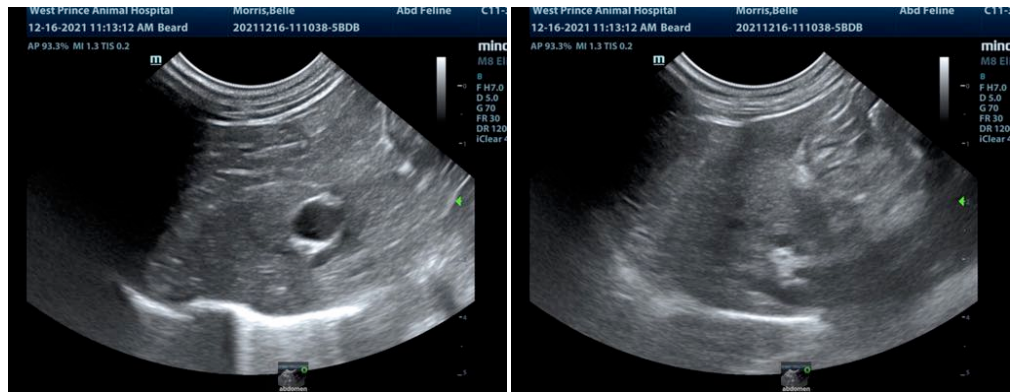
Dr. Beard

INVOICE

94716

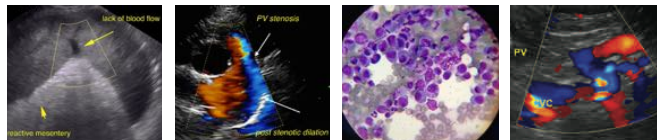
DATE

12/17/21



The information and recommendations provided are based on the images presented by the referring veterinarian. No evaluation can be communicated regarding pathology that was not visible in the image/video clips provided.

Thank you for this referral. If the clinical or image interpretation does not parallel your findings or if I can be of any further assistance please contact me.



PATIENT

Eric Lindquist, DMV, DABVP, Cert. IVUSS, CEO of SonoPath.com
info@SonoPath.com

Belle Morris

SPECIES

Feline

BREED

Domestic Shorthair

SEX

Spayed Female

AGE

8 years

WEIGHT

7 lbs

INTERPRETED BY

Eric Lindquist, DMV
DABVP, Cert. IVUSS

**IMAGING
PERFORMED BY**

Dr. Beard

HOSPITAL NAME

West Prince AH

REFERRING VET

Dr. Beard

INVOICE

94716

DATE

12/17/21