



PATIENT

Ginger Mae Levin

PRESENTING CLINICAL SIGNS

History: Possible foreign body, may have eaten the outside leather from a baseball. Eating and drinking, fine, no reported vomiting.

SPECIES

Canine

ULTRASONOGRAPHIC EXAMINATION OF THE ABDOMEN

Urinary System

The **urinary bladder**, trigone, and pelvic urethra presented normal thicknesses and normal tone. The ureters were not visible which is normal. No uroliths or sediment were visualized and anechoic urine was present. No evidence of inflammatory or neoplastic changes was noted. Ureteral papillae were normal.

BREED

Coonhound Mix

SEX

Spayed Female

The **kidneys** revealed normal size and structure, corticomedullary definition and ratio for this age. The cortices presented largely uniform texture with normal echogenic relationship to liver and spleen. Medullary structure differed distinctly from the cortex and no evidence of pelvic dilation was present. The capsules were acceptably uniform without significant irregularities. The left kidney measured 6.82 cm.

AGE

3 years

WEIGHT

75 lbs

Adrenal Glands

Both **adrenal glands** were visualized and recognized as having normal shape, size, position and echogenicity for this breed. The phrenic vasculature, glandular echogenicity and detail were unremarkable. Capsule, cortex, and medullary definition were normal for this age patient. The left adrenal gland measured 1.46 x 0.46 cm at the caudal pole and 0.39 cm at the cranial pole.

INTERPRETED BY

Eric Lindquist, DMV
DABVP, Cert. IVUSS

Spleen

The **spleen** presented a smooth homogeneous parenchyma hyperechoic to liver and renal cortical parenchyma. The capsule was smooth without noticeable expansion or deviation from within the spleen or adjacent pathology. The splenic vasculature demonstrated normal volume without signs of congestion or thrombosis. No sonographic evidence of acute or chronic inflammatory, neoplastic, or infarctual changes was noted.

IMAGING PERFORMED BY

Kelly Vazquez, CVT

HOSPITAL NAME

New Bridge VH

Liver

The **liver** images submitted revealed subjectively normal liver size, contour, and structure. Parenchymal echogenicity was naturally coarse and hypoechoic to the spleen. Vascular and biliary tracts were of normal volume with no evidence of congestion. The gallbladder presented acceptably thin walls with primarily anechoic content. The cystic and common bile ducts were normal. No pathological hepatic lymphadenopathy was evident. No overt structural evidence of inflammatory, infiltrative or regenerative pathology was evident.

REFERRING VET

Dr. Glennon

INVOICE

94684

DATE

12/17/21



PATIENT

Gastrointestinal

Ginger Mae Levin

The **stomach** was filled with progressively shadowing material. This is consistent with ingesta. Transit of chyme into the small intestine appeared to be normal. There was no evidence of obstruction and no obstructive pattern. The ileocecal junction was free of evident pathology.

SPECIES

Canine

Pancreas

BREED

Coonhound Mix

The base and limbs of the **pancreas** were observed to be largely isoechoic to surrounding omental fat. Pancreatic duct and capsular contour were acceptably normal and parenchyma respected normal curvilinear patterns. No overt evidence of active inflammatory or neoplastic disease was noted.

SEX

Spayed Female

ULTRASONOGRAPHIC FINDINGS

Post prandial presentation with normal transit into the small intestine.

AGE

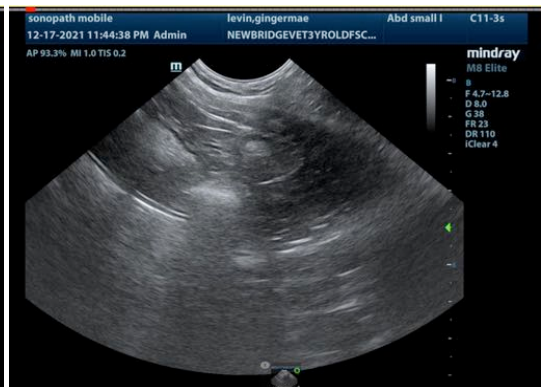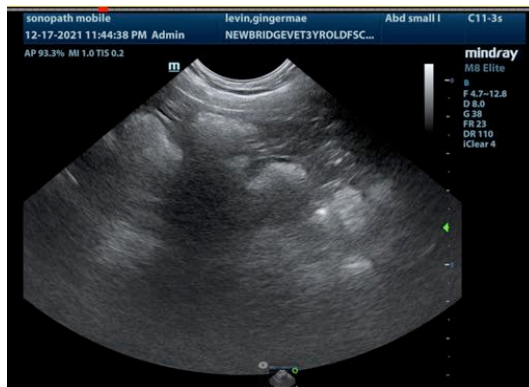
3 years

INTERPRETATION OF THE FINDINGS & FURTHER RECOMMENDATIONS

There is no evidence of foreign body. Supportive care is warranted. I am presuming that this patient was post prandial at the time of the sonogram. No empty small intestine was noted; therefore, an obstructive pattern is not present.

INTERPRETED BY

Eric Lindquist, DMV
DABVP, Cert. IVUSS

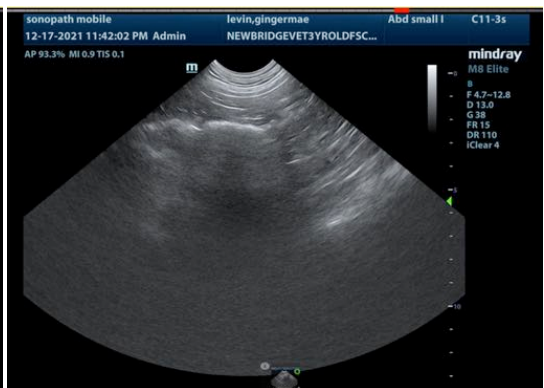
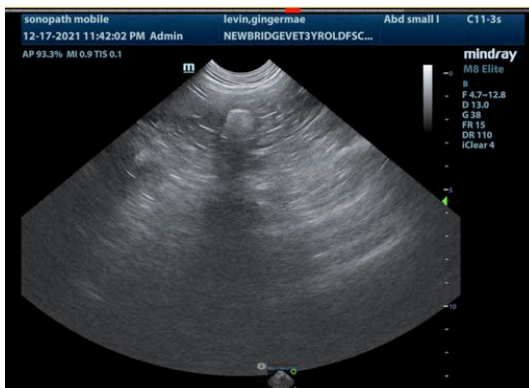


IMAGING PERFORMED BY

Kelly Vazquez, CVT

HOSPITAL NAME

New Bridge VH



REFERRING VET

Dr. Glennon

INVOICE

94684

DATE

12/17/21



PATIENT

Ginger Mae Levin

SPECIES

Canine

BREED

Coonhound Mix

SEX

Spayed Female

AGE

3 years

WEIGHT

75 lbs

INTERPRETED BY

Eric Lindquist, DMV
DABVP, Cert. IVUSS

IMAGING PERFORMED BY

Kelly Vazquez, CVT

HOSPITAL NAME

New Bridge VH

REFERRING VET

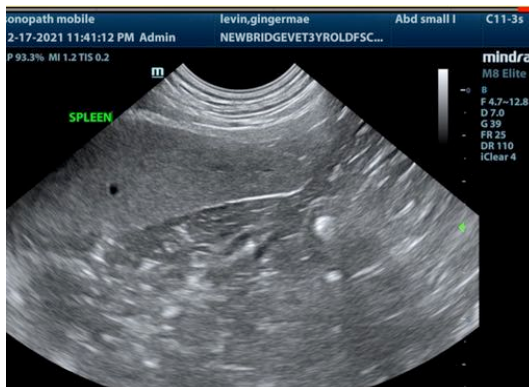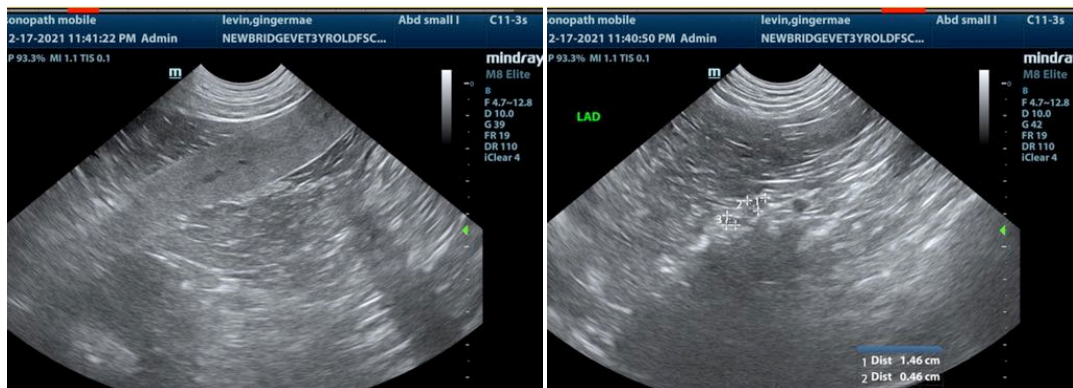
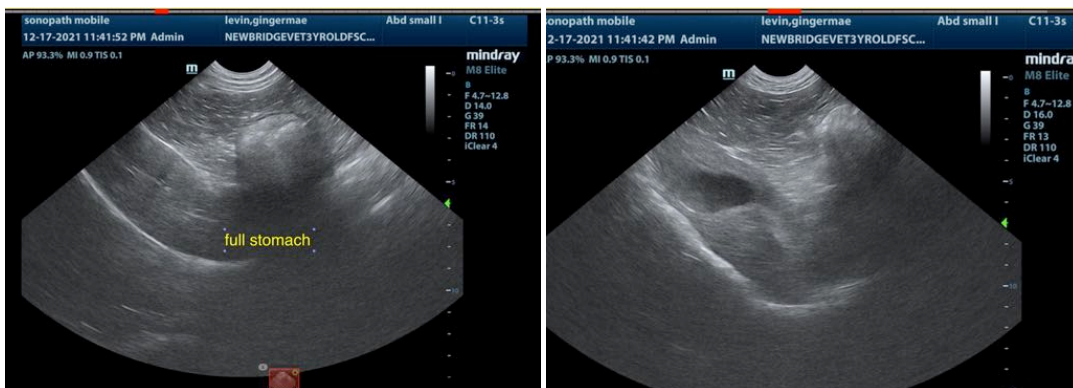
Dr. Glennon

INVOICE

94684

DATE

12/17/21



The information and recommendations provided are based on the images presented by the referring veterinarian. No evaluation can be communicated regarding pathology that was not visible in the image/video clips provided.

Thank you for this referral. If the clinical or image interpretation does not parallel your findings or if I can be of any further assistance please contact me.

Eric Lindquist, DMV, DABVP, Cert. IVUSS, CEO of SonoPath.com
info@SonoPath.com