

PATIENT

Ella Yang

SPECIES

Canine

BREED

Golden Retriever

SEX

Spayed Female

AGE

5 years

WEIGHT

73 lbs

INTERPRETED BY

Eric Lindquist, DMV
DABVP, Cert. IVUSS

IMAGING PERFORMED BY

Shari Reffi, CVT

HOSPITAL NAME

Morris Hills VC

REFERRING VET

Dr. Hirshenson

INVOICE

94686

DATE

12/17/21

PRESENTING CLINICAL SIGNS

Follow-up pericardial effusion and pericardial tap. Prev tap done on 7/2/21 and 7/13/21. Current meds: Pred 20mg sid, Clavamox 500mg bid. MCH 26.8, Retics 142, WBC 22.4, Neuts 20.272, Lymph 0.896, Monos 1.187, Eos 0, BUN 46, Cl 105, ALT 232, AST 60, CK 255

ULTRASONOGRAPHIC EXAMINATION OF THE HEART

The echocardiogram in this patient presented severe pericardial effusion and tamponade effect without evidence of thoracic neoplasia. 2+ liters of hemopericardial fluid was removed from the from pericardial sac. Full dilation of the right atrium and right auricle was present eliminating the tamponade effect. Minor heterogenous tissue was noted in the right auricle and pericardial space. However, this may represent simple blood clot and not necessarily a mass.

Rapid view of the liver and abdomen prior to the pericardiocentesis revealed ascites and passive effusion.

The values reflect post pericardiocentesis values*

CANINE CARDIAC PARAMETERS	MR VMAX (m/s)	TR VMAX (m/s)	LA/AO (Boon method)	LA/AO (Heart Base; Swe)	FS (%)	EF (%)	EPSS (cm)
NORMAL PARAMETER	4.5-5.5	<2.7	1.3	<1.6	28-40	40-100	<0.6
PATIENT			1.1		30		0.1
CANINE CARDIAC PARAMETERS	HR (BPM)	AV VMAX (m/s)	PV MAX (m/s)	BODY WEIGHT (kg)	LA 2D short axis Base view (cm)	LVIDd Avg; 2D and m-mode short axis (cm)	LVIDs Avg; 2D and m-mode short axis (cm)
NORMAL PARAMETER	50-100	0.7-1.7	0.7-1.6				
PATIENT			1.2	73 lbs		3.5	

ULTRASONOGRAPHIC FINDINGS

Idiopathic pericardial effusion.

INTERPRETATION OF THE FINDINGS & FURTHER RECOMMENDATIONS

Referral for pericardectomy is recommended. Cardiac function was restored post pericardiocentesis.



PATIENT

Ella Yang

SPECIES

Canine

BREED

Golden Retriever

SEX

Spayed Female

AGE

5 years

WEIGHT

73 lbs

INTERPRETED BY

Eric Lindquist, DMV
DABVP, Cert. IVUSS

**IMAGING
PERFORMED BY**

Shari Reffi, CVT

HOSPITAL NAME

Morris Hills VC

REFERRING VET

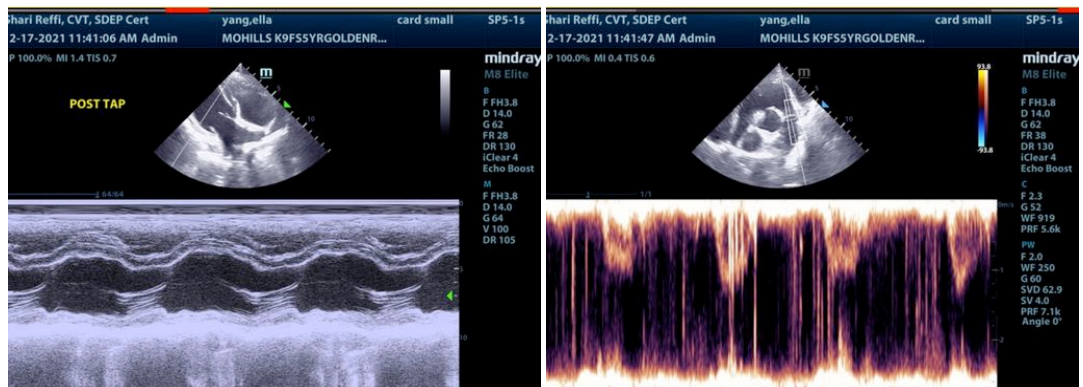
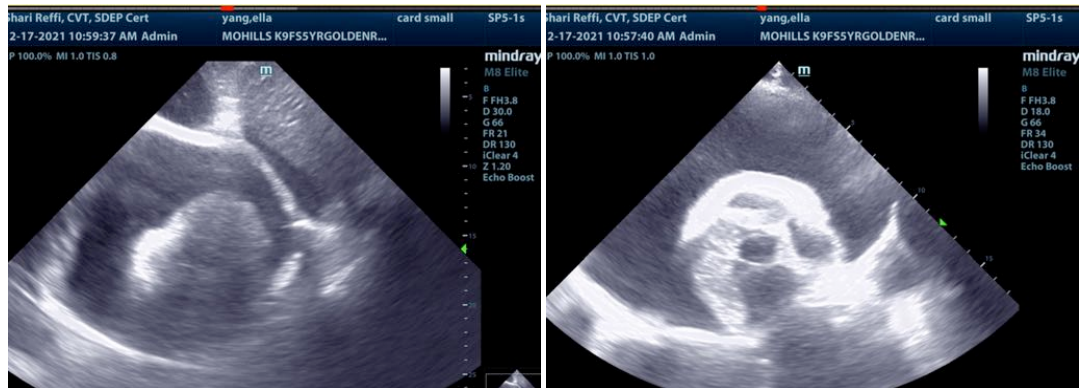
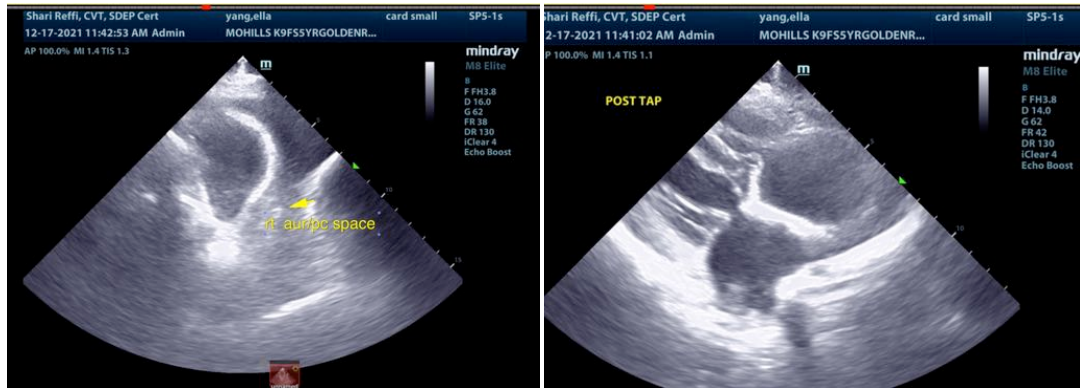
Dr. Hirshenson

INVOICE

94686

DATE

12/17/21



The information and recommendations provided are based on the images presented by the referring veterinarian. No evaluation can be communicated regarding pathology that was not visible in the image/video clips provided.

Thank you for this referral. If the clinical or image interpretation does not parallel your findings or if I can be of any further assistance please contact me.

Eric Lindquist, DMV, DABVP, Cert. IVUSS, CEO of SonoPath.com
Info@SonoPath.com