



PATIENT PRESENTING CLINICAL SIGNS

Coco Denker Check liver, possible Cushing's.

SPECIES ULTRASONOGRAPHIC EXAMINATION OF THE ABDOMEN

Canine **Urinary System**

BREED The **urinary bladder**, trigone, and pelvic urethra presented normal thicknesses and normal tone. The ureters were not visible which is normal. No uroliths or sediment were visualized and anechoic urine was present. No evidence of inflammatory or neoplastic changes was noted. Ureteral papillae were normal.

Maltese

SEX

Spayed Female The **kidneys** revealed largely normal size and structure, corticomedullary definition and ratio (cortex 1/3 of medulla) were essentially maintained with some age-related loss of curvilinear patterns regarding the capsule and C/M junction. The cortices presented largely uniform texture with some increased echogenicity expected for this age patient. Medullary structure differed distinctly from that of the cortex and no evidence of pelvic dilation was present. The right kidney measured 3.22 cm. The left kidney measured 3.25 cm.

AGE

13 years

WEIGHT

Adrenal Glands

Both **adrenal glands** were visualized and recognized as having normal shape, size, position and echogenicity for this breed. The phrenic vasculature, glandular echogenicity and detail were unremarkable. Capsule, cortex, and medullary definition were normal for this age patient. The right adrenal gland measured 1.09 x 0.55 cm at the caudal pole and 0.69 cm at the cranial pole. The left adrenal gland measured 1.19 x 0.43 cm at the caudal pole and 0.38 cm at the cranial pole.

INTERPRETED BY

Eric Lindquist, DMV
DABVP, Cert. IVUSS

IMAGING PERFORMED BY

Kelly Vazquez, CVT

HOSPITAL NAME

New Bridge VP

Spleen

The **spleen** was mildly enlarged with uniform, but subtly micronodular parenchyma, and undulating capsular contour. This is consistent with reactive spleen owing to immune stimulus or early infiltrative disease such as mast cell disease or lymphoma. 25-gauge FNA would be ideal if weight loss is an issue to differentiate early round cell neoplasia versus splenitis or reactive spleen all of which can present in this manner.

REFERRING VET

Glennon

Liver

The **liver** revealed multi-focal, expansive, isoechoic nodular changes that measured up to 2.5 cm with increased portal markings with remodeling. Hyperechoic nodules were also noted. This is consistent with lipogranulomas. Gallbladder polyps are present. Excessive gallbladder debris was also noted.

INVOICE

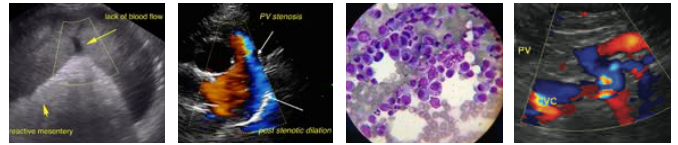
94696

Gastrointestinal

DATE

12/17/21

Examination of the **gastrointestinal tract** revealed a stomach and intestine free of stasis, of normal wall thickness, acceptable curvilinear mural detail, and peristaltic activity. Small and large intestine



PATIENT

demonstrated normal luminal chyme and stool consistency respectively. No obstructive or overt infiltrative disease was noted. No associated abnormal lymphatic activity was noted.

Coco Denker

SPECIES

Pancreas

Canine

The base and limbs of the **pancreas** were observed to be largely isoechoic to surrounding omental fat. Pancreatic duct and capsular contour were acceptably normal and parenchyma respected normal curvilinear patterns. No overt evidence of active inflammatory or neoplastic disease was noted.

BREED

Maltese

ULTRASONOGRAPHIC FINDINGS

SEX

Pronounced nodular hyperplasia hepatic remodeling pattern likely with a mild potential for underlying hepatic neoplasia.

Spayed Female

Scalloping splenic contour.

AGE

Structurally the adrenal glands appear normal.

13 years

INTERPRETATION OF THE FINDINGS & FURTHER RECOMMENDATIONS

WEIGHT

I recommend bile acid profile. Ultrasound-guided FNA of the spleen and liver nodules, particularly the left cranial nodule is recommended. Ursodiol therapy is warranted. Early PDH is a potential as a small percentage of PDH patient's can have normal adrenal glands. However, I recommend to ensure that persistent PU/PD is present i.e. urine specific gravity less than 1.020. If this is the case the following work-up can be considered. However, I recommend sampling the spleen and liver prior to Cushing's work up.

INTERPRETED BY

Eric Lindquist, DMV
DABVP, Cert. IVUSS

Efficient & Accurate Cushing's Work up-Lindquist

Notes regarding Cushing's Clinical Presentations:

Nearly all Cushing's dogs have SAP elevations and true PU/PD (USG < 1.025) and most are polyphagic. Cushing's dogs are > 6 years and usually > 9 years old, usually have poor skin coats, body scores > 3/5, and are usually sedentary animals.

Its important to remember that Cushing's dogs usually look and play the part and other diseases cause false + stress related cortisol spikes. On rare occasion a Cushing's dog will not follow the rules but this is truly an exception.

Potential Cushing's patient workups can be costly and frustrating if not definitive and, in my experience, the non-definitive patient usually has something else going on that may be contributing to some of the clinical signs a Cushing's dog will have, especially SAP elevations or PU/PD. Based on this prelude of information I came up with the following algorithm in the spirit of diagnostic efficiency.

The following suggested protocol is based on current available literature on Cushing's disease and extensive clinical-sonographic experience evaluation + Cushing's and False + LDDST & ACTH stim. cases in order to maximize the efficiency of a Cushing's workup in practice.

IMAGING PERFORMED BY

Kelly Vazquez, CVT

HOSPITAL NAME

New Bridge VP

REFERRING VET

Glennon

INVOICE

94696

Screen first, workup second

1) **UA:** Repeatable (2-3 urine samples) Urine specific gravity & urine cortisol/creatinine ratio (UCCR): If **repeatable USG< 10.20 and + UCCR** move to next step 2.

DATE

12/17/21



PATIENT

Coco Denker

Note: UA is inexpensive and easy to obtain and if UA criteria is not met for Cushing's then resources can be spent into other more pertinent diagnostics or left on hold until the UA criteria is met in emerging Cushing's cases.

SPECIES

Canine

2) **Sonogram:** Does the patient **have concurrent disease** clinically or sonographically as non-Cushing's illness will influence the potential false + LDDST or even ACTH stim. The sonogram gives a global perspective of the internal health of the patient to be considered in the Cushing's workup as an assessment of concurrent disease. Is there a concurrent neoplastic process, UTI pancreatitis, mucocele....? Are the adrenals enlarged (Cushing's-PDH, stress, age related or breed variant), or atrophied (iatrogenic Cushing's or adrenal burnout), have asymmetric enlargement (Adrenal tumor, hyperplasia, adenoma, age related variant), or is there vascular invasion (Invasive pheo with false + UA criteria or adenocarcinoma or phrenic thrombosis)? The sonogram answers these questions proactively.

BREED

Maltese

SEX

Spayed Female

3) **LDDST** (0.01 D-Sodium phosphate mg/kg IV) (Better screening test but plagued with false +) Use if there is potential early Cushing's or if adrenal asymmetry present on sonogram suspecting tumor. Use LDDST in cats at a higher dose (0.1 mg/kg IV).

OR

AGE

13 years

4) **ACTH stim.** (Better confirming test but can have false +) Use if the patient "looks" Cushingoid or if bilateral adrenal enlargement is present, or high normal width on sonogram, or if iatrogenic Cushing's suspected (Cortisone Tx in past).

WEIGHT

5) If **diabetic** then run both LDDST & ACTH stim.

5) Run a **serial blood pressure** in a BP friendly non "white coat effect" atmosphere. Run at least 3 at different times over a few hours or when eating as the patient tends to be calm when eating or give Torbutrol when entering the facility.

INTERPRETED BY

Eric Lindquist, DMV
DABVP, Cert. IVUSS

6) **Perform CT** of the pituitary to identify macro adenoma expansion if any lethargy or dullness or other central clinical CNS signs are minimally present.

Suggested reading:

IMAGING PERFORMED BY

Kelly Vazquez, CVT

Behrend EN, Kooistra HS, Nelson R, et al. Diagnosis of Spontaneous Canine Hyperadrenocorticism: 2012 ACVIM Consensus Statement (Small Animal). J Vet Intern Med 2013;27:1292-1304.

HOSPITAL NAME

New Bridge VP

REFERRING VET

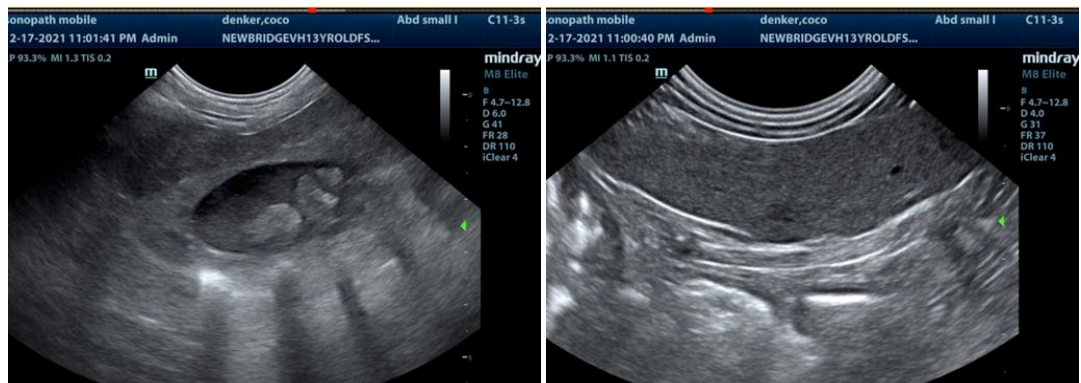
Glennon

INVOICE

94696

DATE

12/17/21





PATIENT

Coco Denker

SPECIES

Canine

BREED

Maltese

SEX

Spayed Female

AGE

13 years

WEIGHT

INTERPRETED BY

Eric Lindquist, DMV
DABVP, Cert. IVUSS

IMAGING PERFORMED BY

Kelly Vazquez, CVT

HOSPITAL NAME

New Bridge VP

REFERRING VET

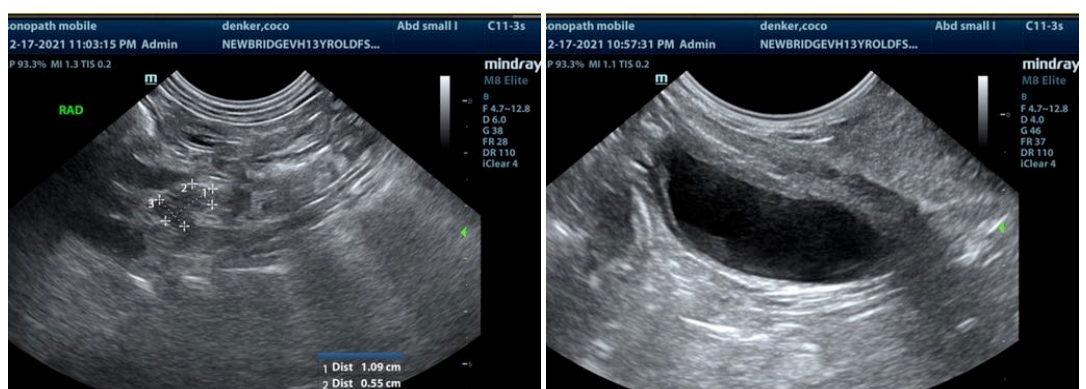
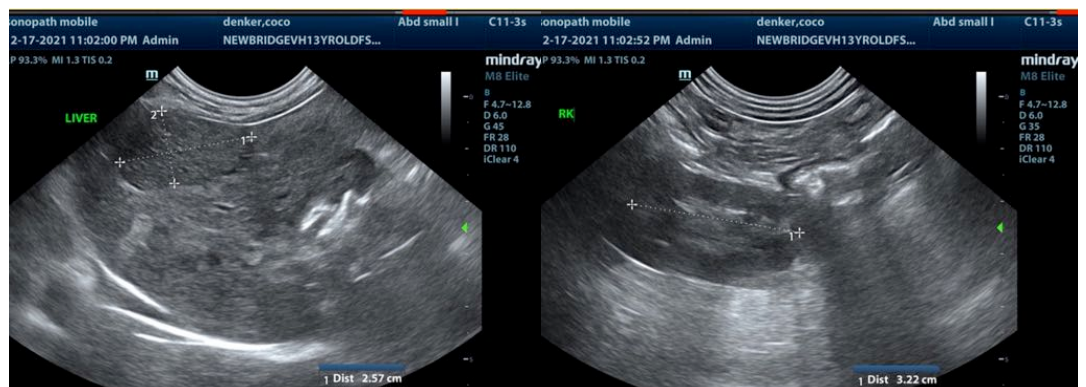
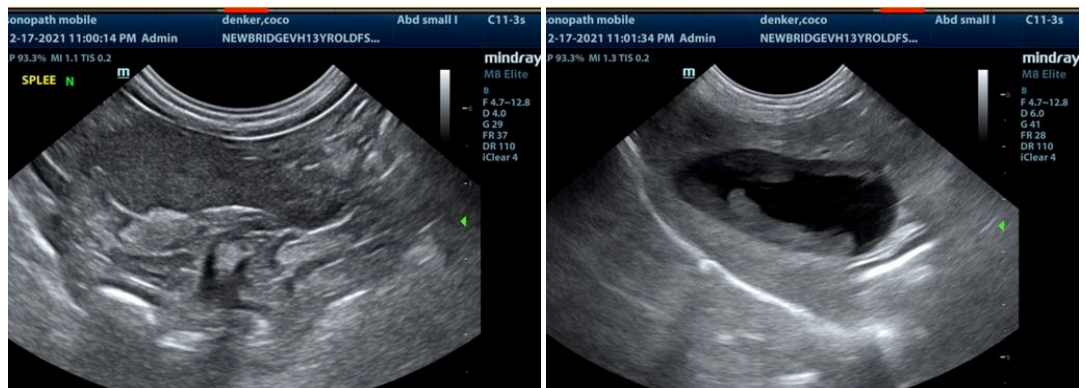
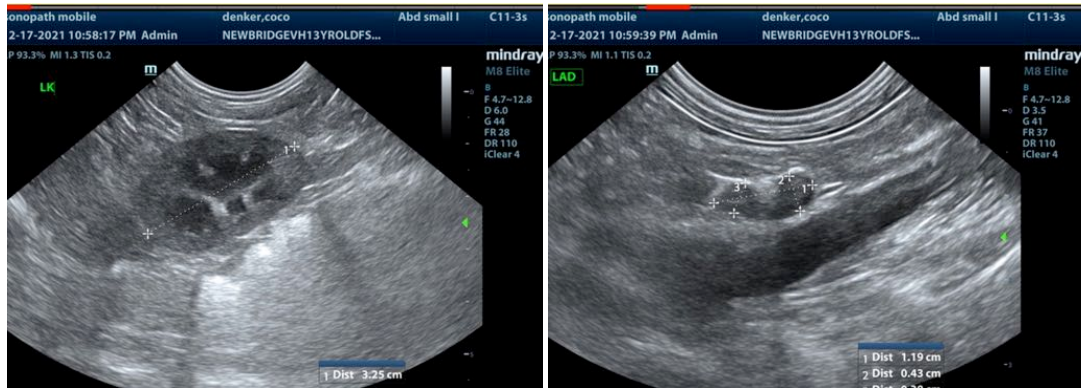
Glennon

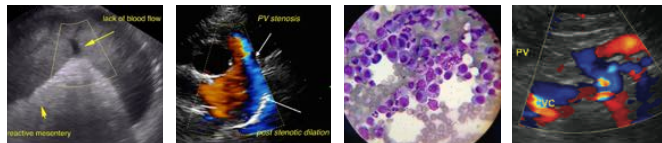
INVOICE

94696

DATE

12/17/21





PATIENT

Coco Denker

The information and recommendations provided are based on the images presented by the referring veterinarian. No evaluation can be communicated regarding pathology that was not visible in the image/video clips provided.

SPECIES

Canine

Thank you for this referral. If the clinical or image interpretation does not parallel your findings or if I can be of any further assistance please contact me.

Eric Lindquist, DMV, DABVP, Cert. IVUSS, CEO of SonoPath.com
info@SonoPath.com

BREED

Maltese

SEX

Spayed Female

AGE

13 years

WEIGHT

INTERPRETED BY

Eric Lindquist, DMV
DABVP, Cert. IVUSS

**IMAGING
PERFORMED BY**

Kelly Vazquez, CVT

HOSPITAL NAME

New Bridge VP

REFERRING VET

Glennon

INVOICE

94696

DATE

12/17/21