



PATIENT

Sparkle Lambros

SPECIES

Canine

BREED

Shih Tzu

SEX

Spayed Female

AGE

11 Years

WEIGHT

8.5 lbs

INTERPRETED BY

Eric Lindquist, DMV,
DABVP (CFM), Cert.
IVUSS

IMAGING PERFORMED BY

Meghan Morse, LVT,
CVT

HOSPITAL NAME

Animal Hospital of
Sussex County

REFERRING VET

Dr. Lovell

INVOICE

72632

DATE

12/16/25

PRESENTING CLINICAL SIGNS

Recheck echo- MR and TR. Left sided volume overload Current meds: Benazepril 2.5mg SID, Lasix 6.25mg BID, Spironolactone 5mg BID, Vetmedin 1.25mg BID
Abnormal PE/Chem/CBC/UA Results: WNL

ULTRASONOGRAPHIC EXAMINATION OF THE HEART

CANINE CARDIAC PARAMETERS	MR VMAX (m/s)	TR VMAX (m/s)	LA/AO (M-Mode)	LA/AO (Heart Base; Swe)	FS (%)	EF (%)	EPSS (cm)
NORMAL PARAMETER	4.5-5.5	<2.7	1.3	Up to 1.6	28-40	40-100	<0.6
PATIENT	6.0	3.0	1.1	1.6	55	87	0.1
CANINE CARDIAC PARAMETERS	HR (BPM)	AV VMAX (m/s)	PV MAX (m/s)	BODY WEIGHT (lbs)	LAD LA MAX 4 Chamber	LVIDd Avg; 2D and m-mode short axis (cm)	LVIDs Avg; 2D and m-mode short axis (cm)
NORMAL PARAMETER	50-100	0.7-1.7	0.7-1.6				
PATIENT	90	1.2	0.7	8.5	3.1	3.01	--

Cardiac Presentation

The cardiac presentation revealed persistent mitral and tricuspid insufficiency. Relatively contained to slightly enlarged left atrium. Contractility appeared adequate. Left ventricular internal volume appeared normal. No pericardial or pleural effusion. No evidence of volume overload in the right heart either. Hepatic veins were not dilated.

ULTRASONOGRAPHIC FINDINGS

- Fairly compensated valvular disease on current protocol.

INTERPRETATION OF THE FINDINGS & FURTHER RECOMMENDATIONS

Recommend maintaining current protocol and recheck sonogram in 6 months, earlier if clinical signs initiate.



PATIENT

Sparkle Lambros

SPECIES

Canine

BREED

Shih Tzu

SEX

Spayed Female

AGE

11 Years

WEIGHT

8.5 lbs

INTERPRETED BY

Eric Lindquist, DMV,
 DABVP (CFM), Cert.
 IVUSS

IMAGING PERFORMED BY

Meghan Morse, LVT,
 CVT

HOSPITAL NAME

Animal Hospital of
 Sussex County

REFERRING VET

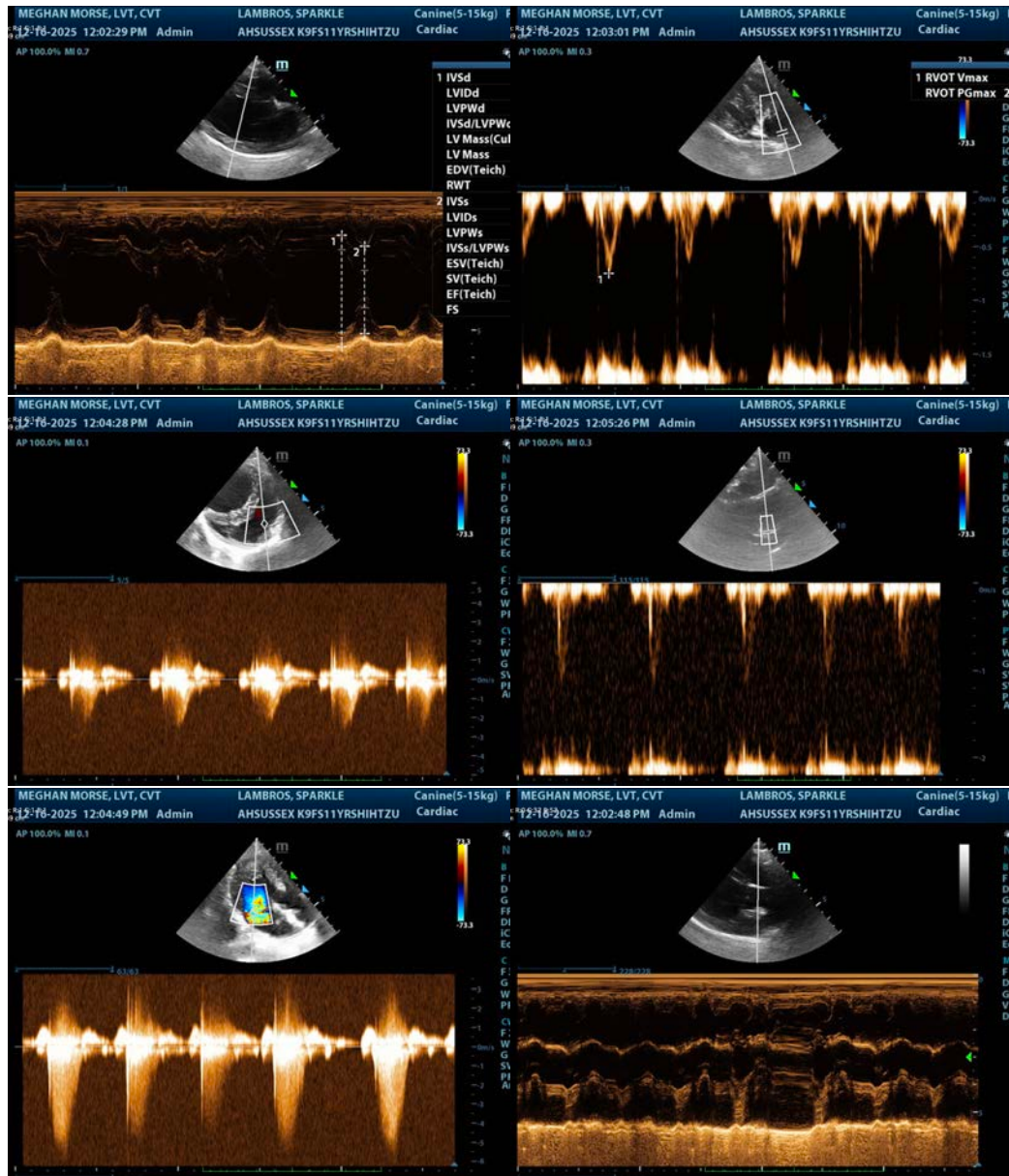
Dr. Lovell

INVOICE

72632

DATE

12/16/25





PATIENT

Sparkle Lambros

SPECIES

Canine

BREED

Shih Tzu

SEX

Spayed Female

AGE

11 Years

WEIGHT

8.5 lbs

INTERPRETED BY

Eric Lindquist, DMV,
 DABVP (CFM), Cert.
 IVUSS

IMAGING PERFORMED BY

Meghan Morse, LVT,
 CVT

HOSPITAL NAME

Animal Hospital of
 Sussex County

REFERRING VET

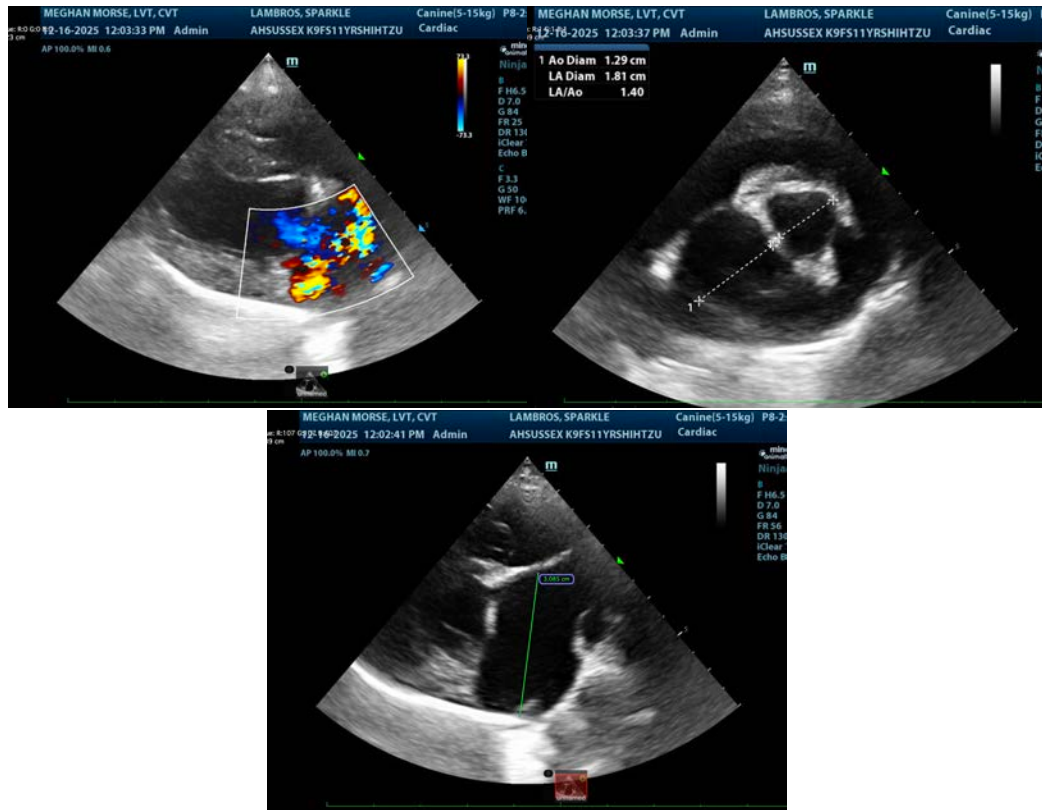
Dr. Lovell

INVOICE

72632

DATE

12/16/25



The information and recommendations provided are based on the images presented by the referring veterinarian/sonographer. No evaluation can be communicated regarding pathology that was not visible in the image/video clips provided.

Thank you for this referral. If the clinical or image interpretation does not parallel your findings or if I can be of any further assistance please contact me.

Eric Lindquist, DMV, DABVP(CFM), Cert. IVUSS,
 CEO, Owner, Founder -- SonoPath.com
info@SonoPath.com