



## PATIENT

Lucky Blaszk

## SPECIES

Canine

## BREED

Havanese

## SEX

Neutered male

## AGE

16 years

## WEIGHT

13 lbs

## INTERPRETED BY

Eric Lindquist, DMV  
DABVP, Cert. IVUSS

## IMAGING PERFORMED BY

Jeremiah Gabriel

## HOSPITAL NAME

Central Jersey AH

## REFERRING VET

Dr. Gabriel

## INVOICE

69327

## DATE

12/16/25

## PRESENTING CLINICAL SIGNS

History: vomiting otherwise normal  
Abnormal PE/Chem/CBC/UA Results: CBC/CHEM mild anemia, high alt, BUN, creatinine 2.0  
BUN 55 ALT 162

## ULTRASONOGRAPHIC EXAMINATION OF THE ABDOMEN

### Urinary System

The **urinary bladder**, trigone, and pelvic urethra presented normal thicknesses and normal tone. The ureters were not visible which is normal. No uroliths or sediment were visualized and anechoic urine was present. No evidence of inflammatory or neoplastic changes was noted. Ureteral papillae were normal.

The **kidneys** revealed largely normal size and structure, corticomedullary definition and ratio (cortex 1/3 of medulla) were essentially maintained with some age-related loss of curvilinear patterns regarding the capsule and C/M junction. The cortices presented largely uniform texture with some increased echogenicity expected for this age patient. Medullary structure differed distinctly from that of the cortex. The left kidney measured 4.05 cm with slight pyelectasia. The right kidney measured 3.8 cm.

The residual prostate measured 1.4 cm.

### Adrenal Glands

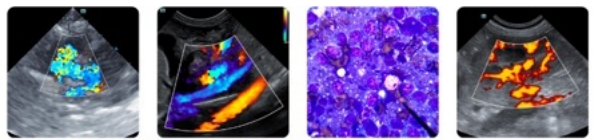
Both **adrenal glands** were visualized and recognized as having normal shape, size, position and echogenicity for this breed. The phrenic vasculature, glandular echogenicity and detail were unremarkable. Capsule, cortex, and medullary definition were normal for this age patient. The left adrenal gland measured 1.32 x 0.62 cm. The right adrenal gland measured 0.8 cm at the cranial pole and 0.7 cm at the caudal pole.

### Spleen

The **spleen** presented a smooth homogeneous parenchyma hyperechoic to liver and renal cortical parenchyma. The capsule was smooth without noticeable expansion or deviation from within the spleen or adjacent pathology. The splenic vasculature demonstrated normal volume without signs of congestion or thrombosis. No sonographic evidence of acute or chronic inflammatory, neoplastic, or infarctual changes was noted.

### Liver

The **liver** images from right and left intercostal as well as subcostal views revealed subjectively normal liver size, contour, and structure. Slight increased portal markings were noted. This is suggestive for inflammatory hepatopathy. Some age-related parenchymal remodeling was noted but likely not clinically significant at this time. Vascular and biliary tracts were of normal volume and no evidence of



## PATIENT

Lucky Blaszk

## SPECIES

Canine

## BREED

Havanese

## SEX

Neutered male

## AGE

16 years

## WEIGHT

13 lbs

## INTERPRETED BY

Eric Lindquist, DMV  
DABVP, Cert. IVUSS

## IMAGING PERFORMED BY

Jeremiah Gabriel

## HOSPITAL NAME

Central Jersey AH

## REFERRING VET

Dr. Gabriel

## INVOICE

69327

## DATE

12/16/25

congestion was noted. The gallbladder presented some dependent debris with essentially normal contour. The cystic and common bile ducts were normal. No overt evidence of active inflammatory, infiltrative or regenerative pathology was noted but should be paired with current or past LE elevations regarding any clinical significance to this presentation. The hepatic lymph nodes were unremarkable.

## Gastrointestinal

There was some residual chyme and gas was noted in the **stomach**, yet not pathological. This is consistent with post prandial presentation. Transit of chyme into the small intestine was normal. Curvilinear patterns were maintained throughout the GI tract. No evidence of pathology. Small and large intestine demonstrated normal luminal chyme and stool consistency respectively. No obstructive or overt infiltrative disease was noted. No associated abnormal lymphatic activity was noted.

## Pancreas

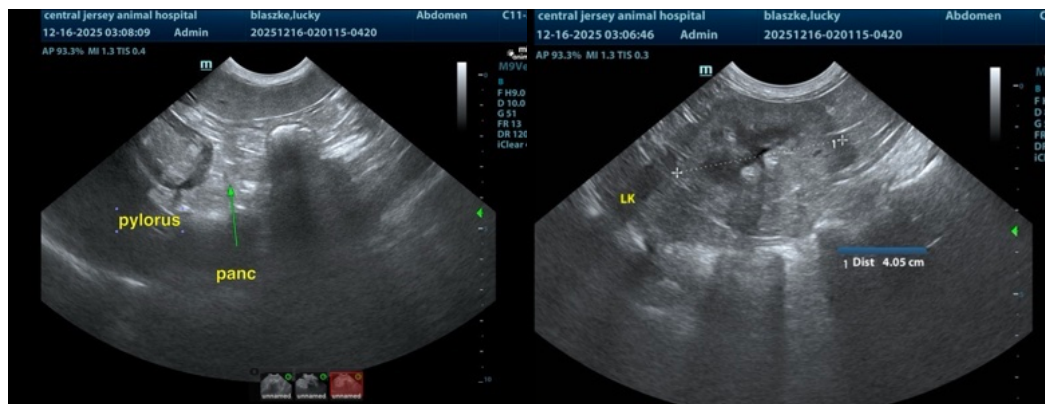
The base and limbs of the **pancreas** were observed to be largely isoechoic to surrounding omental fat. Pancreatic duct and capsular contour were acceptably normal and parenchyma respected normal curvilinear patterns. No overt evidence of active inflammatory or neoplastic disease was noted.

## ULTRASONOGRAPHIC FINDINGS

Non-specific, geriatric abdomen with moderate degenerative renal changes.

## INTERPRETATION OF THE FINDINGS & FURTHER RECOMMENDATIONS

A potential underlying UTI should be ruled out in this patient. 72-hour IV fluid protocol is warranted along with GI protectants, urine culture and blood pressure measurements are all indicated. FNA of the liver would be appropriate and Leptospirosis titers. There was no evidence of neoplasia. The patient should respond readily to appropriate therapy.





### PATIENT

Lucky Blaszka

### SPECIES

Canine

### BREED

Havanese

### SEX

Neutered male

### AGE

16 years

### WEIGHT

13 lbs

### INTERPRETED BY

Eric Lindquist, DMV  
DABVP, Cert. IVUSS

### IMAGING PERFORMED BY

Jeremiah Gabriel

### HOSPITAL NAME

Central Jersey AH

### REFERRING VET

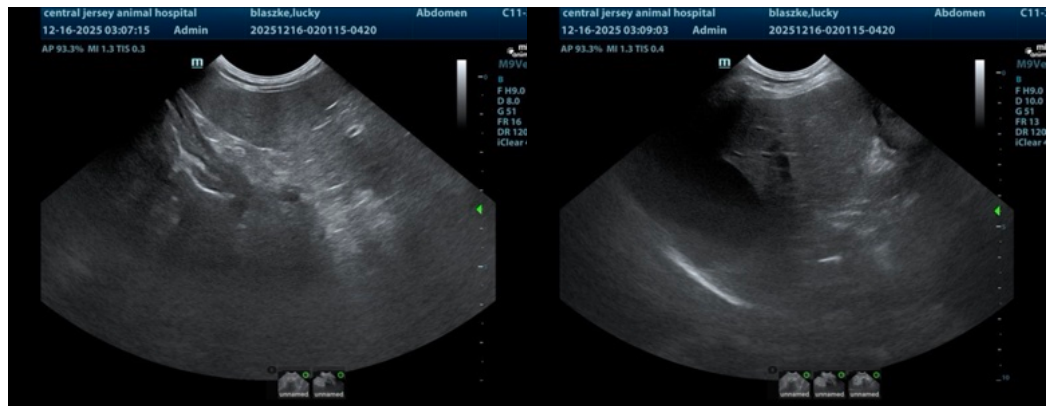
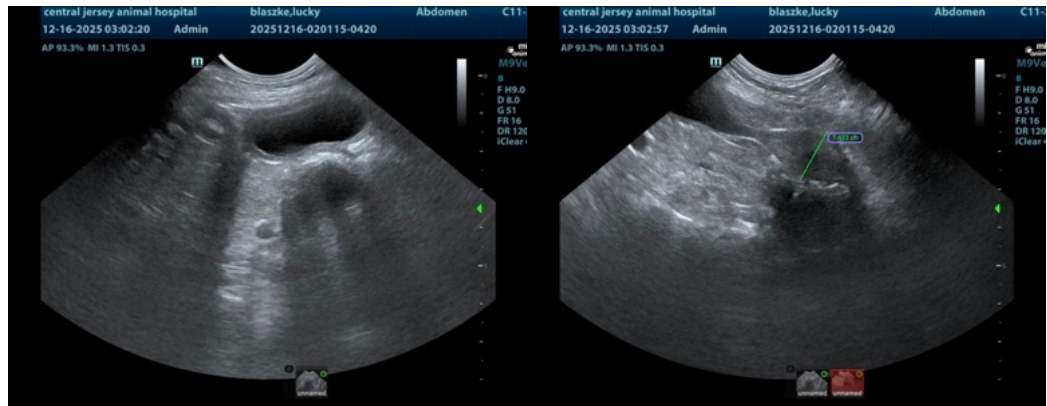
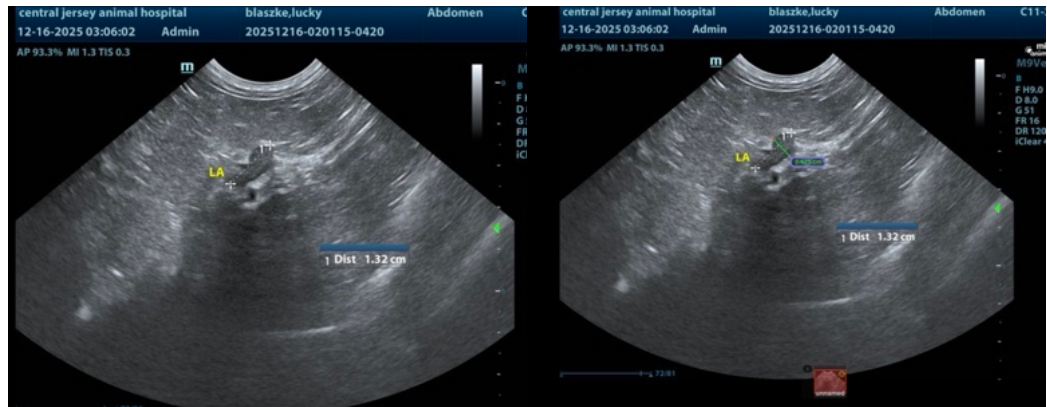
Dr. Gabriel

### INVOICE

69327

### DATE

12/16/25





## PATIENT

Lucky Blaszk

## SPECIES

Canine

## BREED

Havanese

## SEX

Neutered male

## AGE

16 years

## WEIGHT

13 lbs

## INTERPRETED BY

Eric Lindquist, DMV  
DABVP, Cert. IVUSS

## IMAGING PERFORMED BY

Jeremiah Gabriel

## HOSPITAL NAME

Central Jersey AH

## REFERRING VET

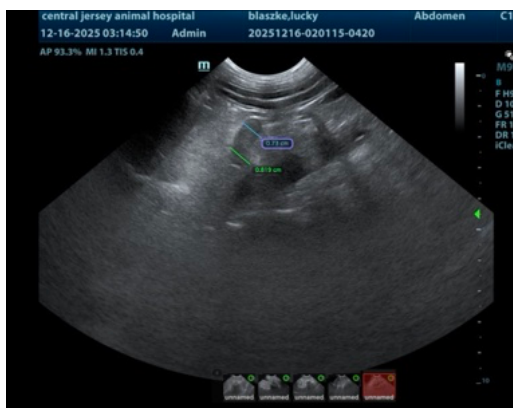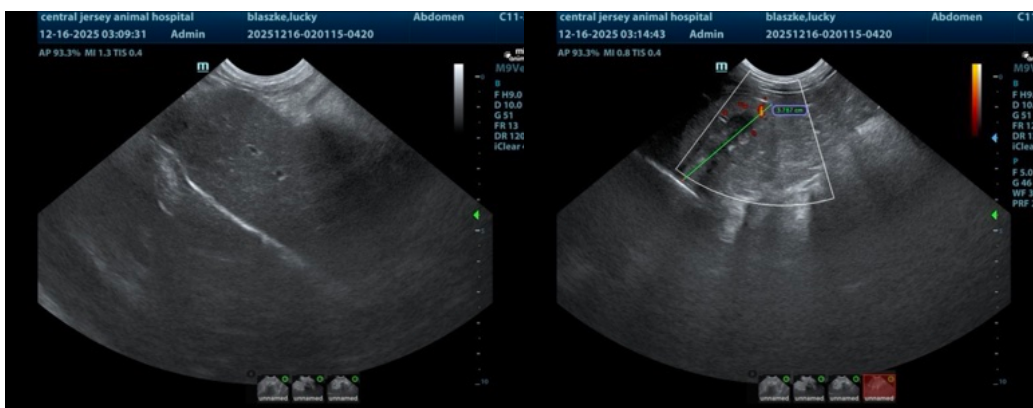
Dr. Gabriel

## INVOICE

69327

## DATE

12/16/25



The information and recommendations provided are based on the images presented by the referring veterinarian/sonographer. No evaluation can be communicated regarding pathology that was not visible in the image/video clips provided.

Thank you for this referral. If the clinical or image interpretation does not parallel your findings or if I can be of any further assistance please contact me.

Eric Lindquist, DMV, DABVP (CFM), Cert. IVUSS, CEO of SonoPath.com

[info@SonoPath.com](mailto:info@SonoPath.com)