



PATIENT

Hazel Mangano

SPECIES

Canine

BREED

Mixed

SEX

Spayed Female

AGE

13 Years

WEIGHT

20 lbs

PRESENTING CLINICAL SIGNS

Recheck echo. MEDS: Enalapril 5 mg BID, Vetmedin 2.5 mg BID

ULTRASONOGRAPHIC EXAMINATION OF THE HEART

CANINE CARDIAC PARAMETERS	MR VMAX (m/s)	TR VMAX (m/s)	LA/AO (M-Mode)	LA/AO (Heart Base; Swe)	FS (%)	EF (%)	EPSS (cm)
NORMAL PARAMETER	4.5-5.5	<2.7	1.3	Up to 1.6	28-40	40-100	<0.6
PATIENT	5.8	--	1.7	1.6	47	79	0.1
CANINE CARDIAC PARAMETERS	HR (BPM)	AV VMAX (m/s)	PV MAX (m/s)	BODY WEIGHT (lbs)	LAD LA MAX 4 Chamber	LVIDd Avg; 2D and m-mode short axis (cm)	LVIDs Avg; 2D and m-mode short axis (cm)
NORMAL PARAMETER	50-100	0.7-1.7	0.7-1.6				
PATIENT	188	1.8	0.71	20	--	3.77	--

INTERPRETED BY

Eric Lindquist, DMV, DABVP (CFM), Cert. IVUSS

IMAGING PERFORMED BY

Rebecca Hamilton

HOSPITAL NAME

Companion Animal Hospital Parsippany

REFERRING VET

Dr. Tsai

INVOICE

72624

DATE

12/16/25

Cardiac Presentation

The cardiac presentation revealed persistent left atrial enlargement. However, left ventricular internal volume has improved. Contractility is adequate. Mitral, tricuspid, and aortic insufficiency all present. No pericardial or pleural effusion. No right-sided overload. The patient was mildly tachycardic.

ULTRASONOGRAPHIC FINDINGS

- B2+ valvular disease, given the progressive/persistent left atrial enlargement.

INTERPRETATION OF THE FINDINGS & FURTHER RECOMMENDATIONS

Given the left atrial enlargement, recommend adding Spironolactone at 1-2 mg/kg SID. Monitoring for emerging heart failure warranted with radiographs, blood pressure, and clinical signs of any coughing or exercise intolerance. If coughing is an issue, additional diuretic such as Lasix would be appropriate. Recheck echo in 6 months, earlier if clinical signs initiate. Note the left atrial size evaluation is best assessed in LA Max position.



PATIENT

Hazel Mangano

SPECIES

Canine

BREED

Mixed

SEX

Spayed Female

AGE

13 Years

WEIGHT

20 lbs

INTERPRETED BY

Eric Lindquist, DMV,
 DABVP (CFM), Cert.
 IVUSS

IMAGING PERFORMED BY

Rebecca Hamilton

HOSPITAL NAME

Companion Animal
 Hospital Parsippany

REFERRING VET

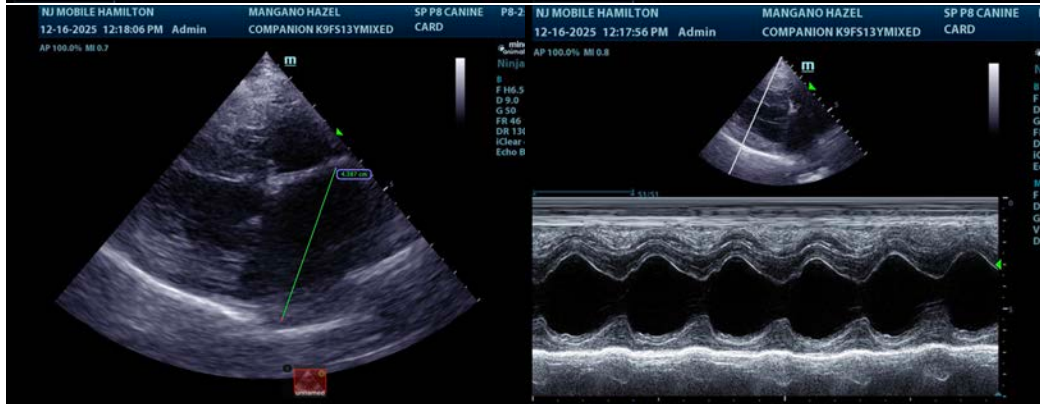
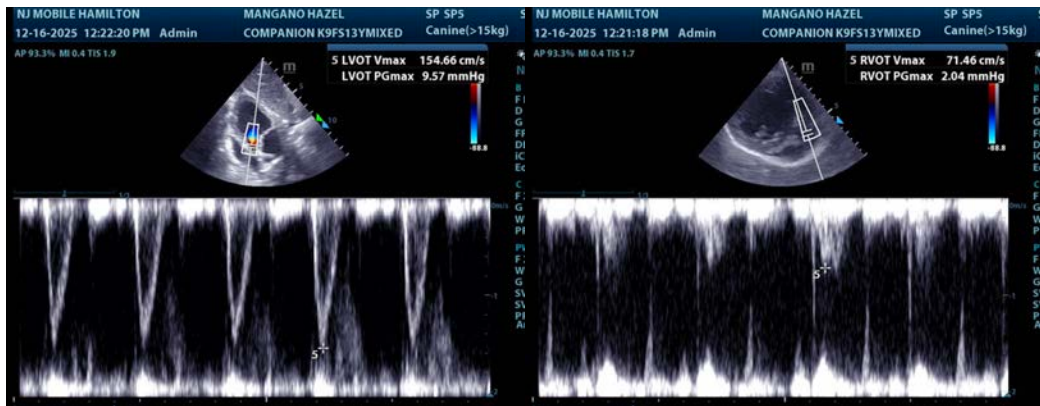
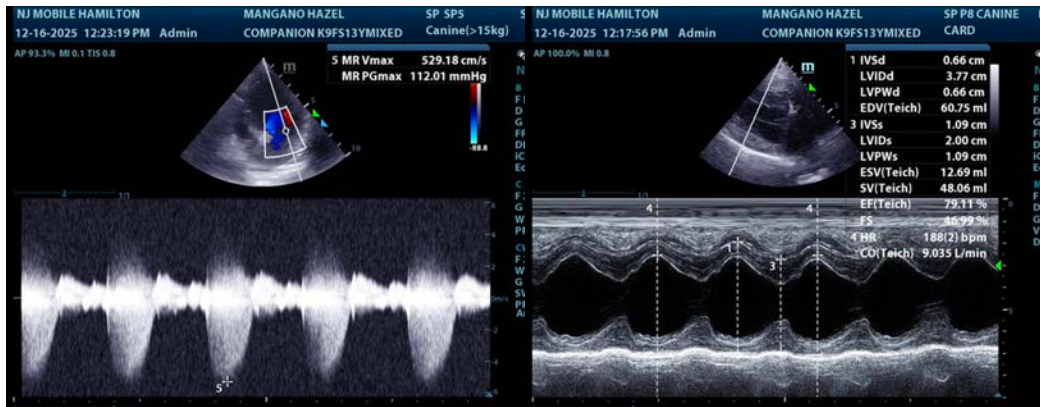
Dr. Tsai

INVOICE

72624

DATE

12/16/25





PATIENT

Hazel Mangano

SPECIES

Canine

BREED

Mixed

SEX

Spayed Female

AGE

13 Years

WEIGHT

20 lbs

INTERPRETED BY

Eric Lindquist, DMV,
DABVP (CFM), Cert. IVUSS

IMAGING PERFORMED BY

Rebecca Hamilton

HOSPITAL NAME

Companion Animal
Hospital Parsippany

REFERRING VET

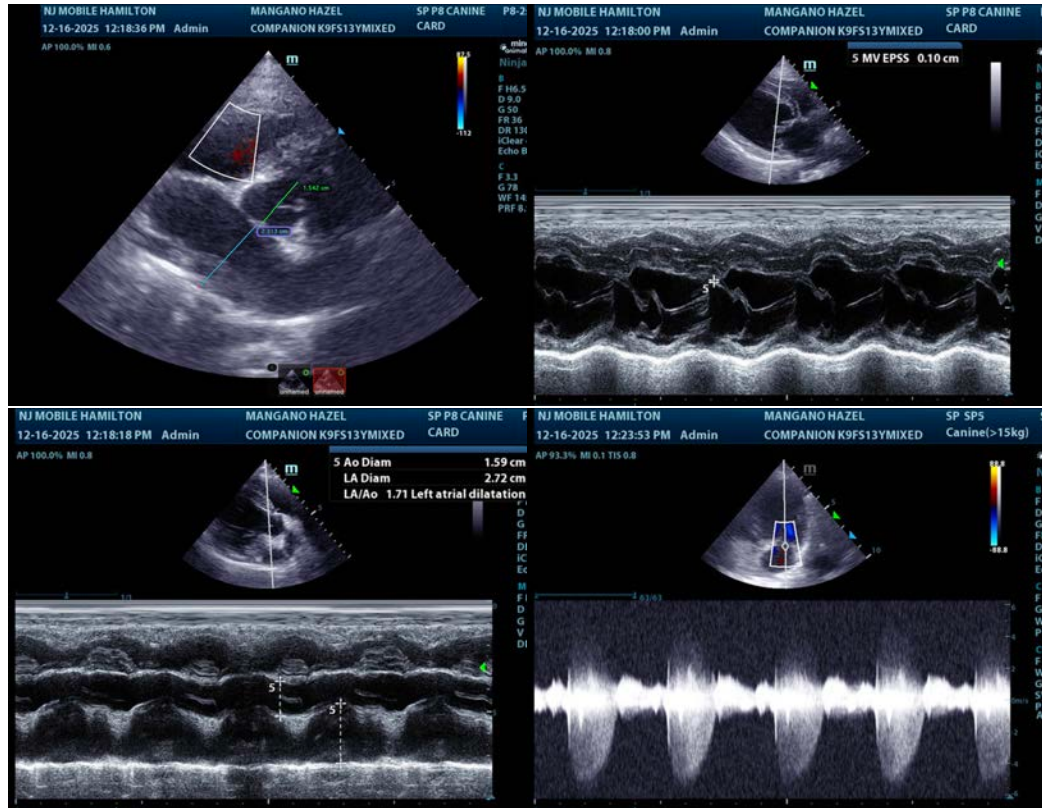
Dr. Tsai

INVOICE

72624

DATE

12/16/25



The information and recommendations provided are based on the images presented by the referring veterinarian/sonographer. No evaluation can be communicated regarding pathology that was not visible in the image/video clips provided.

Thank you for this referral. If the clinical or image interpretation does not parallel your findings or if I can be of any further assistance please contact me.

Eric Lindquist, DMV, DABVP(CFM), Cert. IVUSS,
CEO, Owner, Founder -- SonoPath.com
info@SonoPath.com