

**DATE PRESENTING CLINICAL SIGNS**

12/16/22

History: Increased blood levels since initial routine bloodwork.
(incidental finding)

PATIENT

Poppi Park

Current Medications: Denamarin.

Lab Results: Hepatic Profile: ALB 3.2 (WNL) (Ref 2.2 - 3.9) (Last value 3.2 on 09/12/22 - stable), ALP 274 (H) (Ref 23 - 212) (Last value 111 on 09/12/22 - worse), ALT 162 (H) (Ref 10 - 125) (Last value 126 on 09/12/22 - worse), GGT 11 (WNL) (Ref 0 - 11) (Last value 1 on 09/12/22 - worse), TBili 0.2 (WNL) (Ref 0.0 - 0.9) (Last value 0.2 on 09/12/22 - stable)

SPECIES

Canine

Date of Previous IntraPet Ultrasound: No previous.

BREED

Shih Tzu

Sedation: Not required to complete full diagnostic ultrasound.

Stat Report: Not requested.

Imaging Performed By: Rachel Brilhart, RDMS.

SEX

Spayed Female

ULTRASONOGRAPHIC EXAMINATION OF THE ABDOMEN**AGE**

8/4/19

Urinary System

The **urinary bladder**, trigone, and pelvic urethra presented normal thicknesses and normal tone. The ureters were not visible which is normal. No uroliths or sediment were visualized, and anechoic urine was present. No evidence of inflammatory or neoplastic changes were noted. Ureteral papillae were normal.

WEIGHT

3.95 kg

The **kidneys** revealed normal size and structure, corticomedullary definition and ratio for this age. The cortices presented largely uniform texture with normal echogenic relationship to liver and spleen. Medullary structure differed distinctly from the cortex and no evidence of pelvic dilation was present. The capsules were acceptably uniform without significant irregularities. The left kidney measured 3.6 cm. The right kidney measured 3.36 cm.

INTERPRETED BYEric Lindquist, DMV
DABVP, Cert. IVUSS**Adrenal Glands**

Both **adrenal glands** were visualized and recognized as having normal shape, size, position and echogenicity for this breed. The phrenic vasculature, glandular echogenicity and detail were unremarkable. Capsule, cortex, and medullary definition were normal for this age patient. The left adrenal gland measured 1.6 cm x 0.5 cm at the caudal pole and 0.43 cm at the cranial pole. The right adrenal gland measured 1.83 cm x 0.41 cm at the caudal pole and 0.49 cm at the cranial pole.

HOSPITAL NAME

Banfield Abingdon

Spleen

The **spleen** presented a smooth homogeneous parenchyma hyperechoic to liver and renal cortical parenchyma. The capsule was smooth without noticeable expansion or deviation from within the spleen or adjacent pathology. The splenic vasculature demonstrated normal volume without signs of congestion or thrombosis. No sonographic evidence of acute or chronic inflammatory, neoplastic, or infarctual changes were noted.

REFERRING VET

Dr. Aylward

INVOICE

20150

Liver

The **liver** was subnormal in size with slight coarse architecture. Hepatic width measured 3.14 cm. The gallbladder and common bile duct were unremarkable. Portal vein to vena cava was 1:1, measuring 0.5 mm each.

Gastrointestinal

Examination of the **gastrointestinal tract** revealed a stomach and intestine free of stasis, of normal wall thickness, acceptable curvilinear mural detail, and peristaltic activity. Small and large intestine demonstrated normal luminal chyme and stool consistency respectively. No obstructive or overt infiltrative disease was noted. No associated abnormal lymphatic activity was noted.

Pancreas

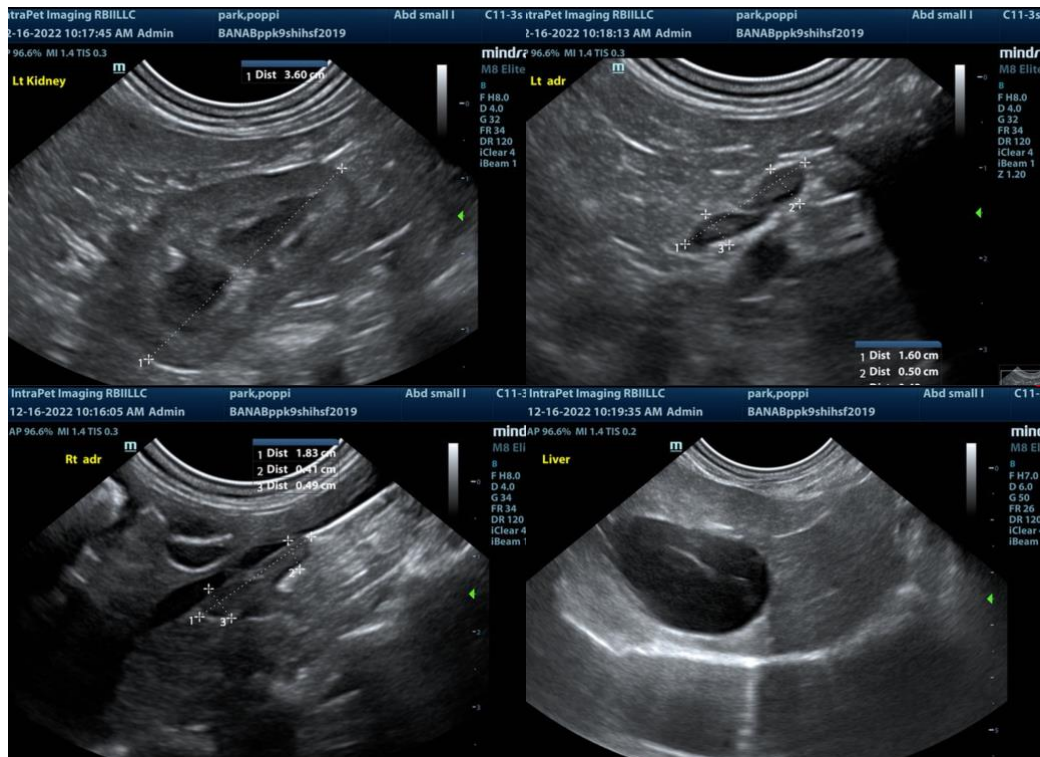
The base and limbs of the **pancreas** were observed to be largely isoechoic to surrounding omental fat. Pancreatic duct and capsular contour were acceptably normal and parenchyma respected normal curvilinear patterns. No overt evidence of active inflammatory or neoplastic disease was noted.

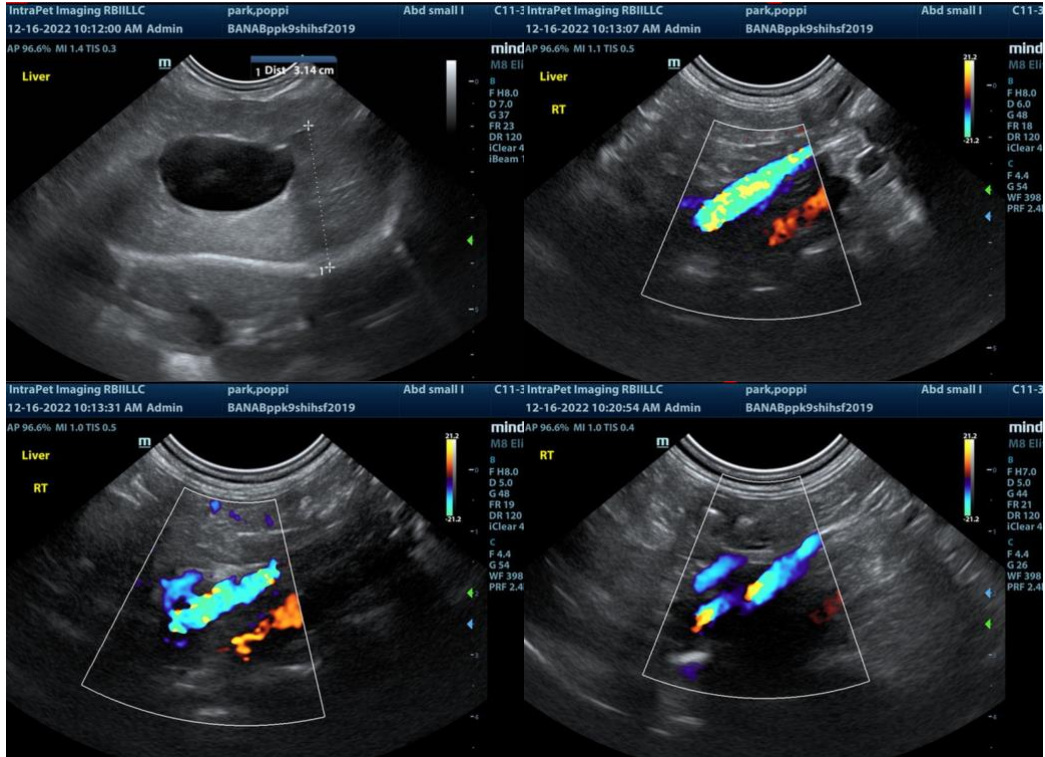
ULTRASONOGRAPHIC FINDINGS

- Structurally unremarkable abdomen with mild microhepatica

INTERPRETATION OF THE FINDINGS & FURTHER RECOMMENDATIONS

No evidence of intrahepatic shunting, however, portohypoplasia/microvascular dysplasia is suspected, especially if bile acid elevations are present.





The information and recommendations provided are based on the images presented by the referring veterinarian. No evaluation can be communicated regarding pathology that was not visible in the image/video clips provided.

Thank you for this referral. If the clinical or image interpretation does not parallel your findings or if I can be of any further assistance please contact me.

Eric Lindquist, DMV, DABVP, Cert. IVUSS, CEO of SonoPath.com
info@SonoPath.com