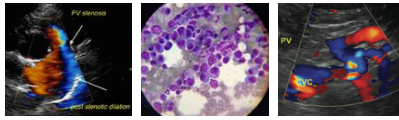


IMAGING PERFORMED BY

IntraPet.com



**SonoPath**

Clinical Sonography & Telectology

EDUCATIONAL TELECONSULTATION SERVICES™

1-800-838-4268 info@sonopath.com SonoPath.com

**DATE**

12/16/22

**PATIENT**

Phoenix Karr

**SPECIES**

Canine

**BREED**

Golden Retriever

**SEX**

Neutered male

**AGE**

10/6/12

**WEIGHT**

97 lbs

**INTERPRETED BY**

Eric Lindquist, DMV  
DABVP, Cert. IVUSS

**HOSPITAL NAME**

Banfield Abingdon

**REFERRING VET**

Dr. Simpson

**INVOICE**

43178

**PRESENTING CLINICAL SIGNS**

Suspect bladder stones- abnormally felt during palpation, however not observed on radiographs.

Current Medications: None listed.

Date of Previous IntraPet Ultrasound: No previous.

Sedation: Not required to complete full diagnostic ultrasound.

Stat Report: Not requested.

Imaging Performed By: Rachel Brillhart, RDMS.

**ULTRASONOGRAPHIC EXAMINATION OF THE ABDOMEN**

**Urinary System**

The **urinary bladder**, trigone, and pelvic urethra presented normal thicknesses and normal tone. The ureters were not visible which is normal. No uroliths or sediment were visualized and anechoic urine was present. No evidence of inflammatory or neoplastic changes was noted. Ureteral papillae were normal.

The **kidneys** revealed normal size and structure, corticomedullary definition and ratio for this age. The cortices presented largely uniform texture with normal echogenic relationship to liver and spleen. Medullary structure differed distinctly from the cortex and no evidence of pelvic dilation was present. The capsules were acceptably uniform without significant irregularities. The right kidney measured 8.17 cm. The left kidney measured 7.18 cm.

**Adrenal Glands**

Both **adrenal glands** were visualized and recognized as having normal shape, size, position and echogenicity for this breed. The phrenic vasculature, glandular echogenicity and detail were unremarkable. Capsule, cortex, and medullary definition were normal for this age patient. The right adrenal gland measured 3.37 x 0.9 cm at the caudal pole and 0.86 cm at the cranial pole.

**Spleen**

The **spleen** revealed slight coarse architecture and was folded upon itself caudally. The spleen was normal in size with fairly normal contour.

**Liver**

The **liver** images from right and left intercostal as well as subcostal views revealed subjectively normal liver size, contour, and structure. Some age-related parenchymal remodeling was noted but likely not clinically significant at this time. Vascular and biliary tracts were of normal volume and no evidence of congestion was noted. The gallbladder presented some dependent debris with essentially normal contour. The cystic and common bile ducts were normal. No overt evidence of active inflammatory, infiltrative or regenerative pathology was noted but should be paired with current or past LE elevations regarding any clinical significance to this presentation. The hepatic lymph nodes were unremarkable.

**Gastrointestinal**

Examination of the **gastrointestinal tract** revealed a stomach and intestine free of stasis, of normal wall thickness, acceptable curvilinear mural detail, and peristaltic activity. Small and large intestine demonstrated normal luminal chyme and stool consistency respectively. No obstructive or overt infiltrative disease was noted. No associated abnormal lymphatic activity was noted.

### **Pancreas**

The base and limbs of the **pancreas** were observed to be largely isoechoic to surrounding omental fat. Pancreatic duct and capsular contour were acceptably normal and parenchyma respected normal curvilinear patterns. No overt evidence of active inflammatory or neoplastic disease was noted.

### **Free Abdomen**

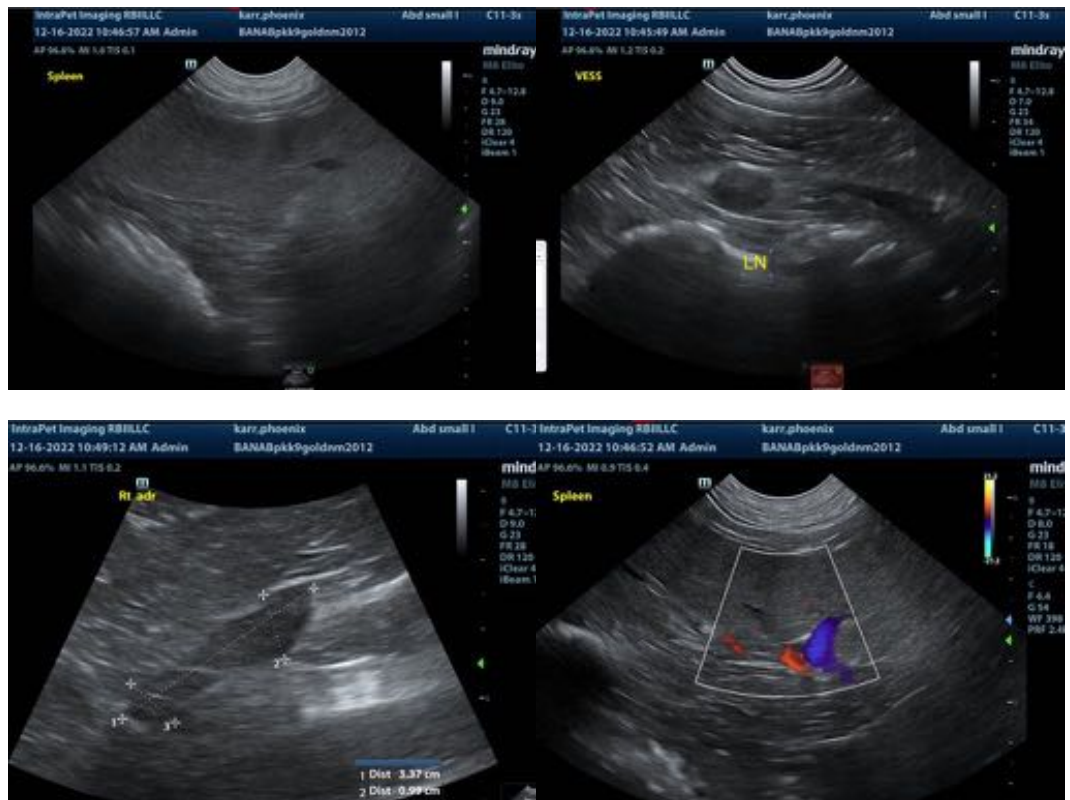
The iliac lymph nodes were slightly enlarged and measured 1.0 cm. This should be monitored or samples. A smaller lymph node was noted.

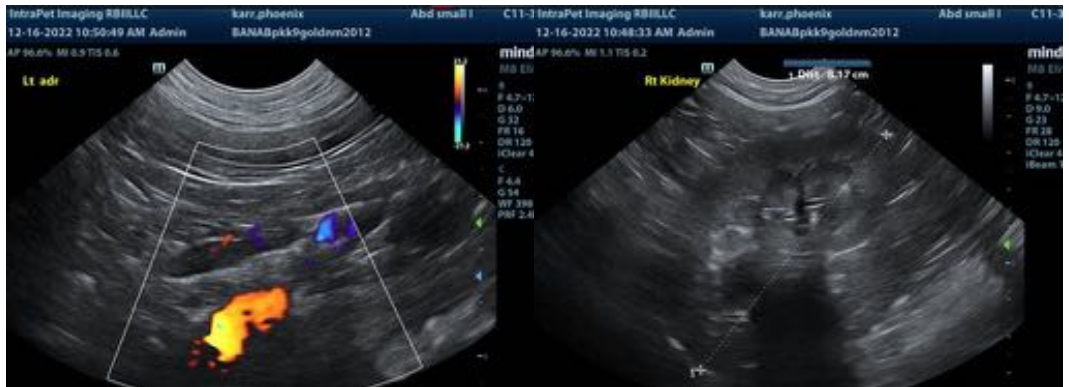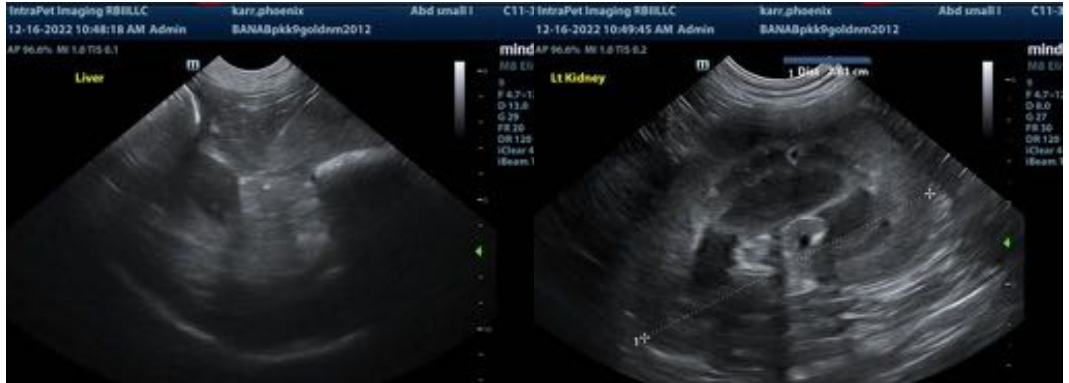### **ULTRASONOGRAPHIC FINDINGS**

Minor iliac lymphadenopathy to be monitored or sampled. Otherwise, structurally unremarkable abdomen.

### **INTERPRETATION OF THE FINDINGS & FURTHER RECOMMENDATIONS**

There was no evidence of bladder calculi. The lymph nodes **should** be monitored for any potential emerging disease.





The information and recommendations provided are based on the images presented by the referring veterinarian. No evaluation can be communicated regarding pathology that was not visible in the image/video clips provided.

Thank you for this referral. If the clinical or image interpretation does not parallel your findings or if I can be of any further assistance please contact me.

**Eric Lindquist**, DMV, DABVP, Cert. IVUSS, CEO of SonoPath.com  
 Eric.Lindquist@SonoPath.com