**DATE PRESENTING CLINICAL SIGNS**

12/16/22

Elevated ALT and Bile Acids.
Current Medications: Denamarin.
Lab Results: ALT = 146 on 12/9/22, ALT = 83 on 5/25/22.

PATIENT

Jenna Rust

Bile Acids: pre = 101, post = 45.
Date of Previous IntraPet Ultrasound: No previous.
Sedation: IV sedation.
Stat Report: Not requested.

SPECIES

Canine

Imaging Performed By: Rachel Brillhart, RDMS.

BREED

Chihuahua

ULTRASONOGRAPHIC EXAMINATION OF THE ABDOMEN**Urinary System**

The **urinary bladder**, trigone, and pelvic urethra presented normal thicknesses and normal tone. The ureters were not visible which is normal. No uroliths or sediment were visualized and anechoic urine was present. No evidence of inflammatory or neoplastic changes was noted. Ureteral papillae were normal.

SEX

Spayed female

The **kidneys** revealed largely normal size and structure, corticomedullary definition and ratio (cortex 1/3 of medulla) were essentially maintained with some age-related loss of curvilinear patterns regarding the capsule and C/M junction. The cortices presented largely uniform texture with some increased echogenicity expected for his age patient. Medullary structure differed distinctly from that of the cortex and no evidence of pelvic dilation was present. Occasional cortical cyst was noted in the kidneys. The left kidney measured 3.7 cm. An anechoic cyst was noted and measured 0.47 cm at the caudal pole. The right kidney measured 3.57 cm.

AGE

12/11/14

WEIGHT

15 lbs

Adrenal Glands

Both **adrenal glands** were visualized and recognized as having normal shape, size, position and echogenicity for this breed. The phrenic vasculature, glandular echogenicity and detail were unremarkable. Capsule, cortex, and medullary definition were normal for this age patient. The left adrenal gland measured 1.79 x 0.71 cm at the caudal pole and 0.62 cm at the cranial pole. The right adrenal gland measured 1.91 x 0.56 cm at the caudal pole and 0.57 cm at the cranial pole.

INTERPRETED BYEric Lindquist, DMV
DABVP, Cert. IVUSS**HOSPITAL NAME**

Banfield Abingdon

Spleen

The **spleen** presented a smooth homogeneous parenchyma hyperechoic to liver and renal cortical parenchyma. The capsule was smooth without noticeable expansion or deviation from within the spleen or adjacent pathology. The splenic vasculature demonstrated normal volume without signs of congestion or thrombosis. No sonographic evidence of acute or chronic inflammatory, neoplastic, or infarctual changes was noted.

REFERRING VET

Dr. Simpson

Liver

The **liver** presented heterogenous parenchyma with increased portal markings and coarse architecture. Slight undulating capsular contour was noted. The gallbladder and common bile duct were unremarkable. This is consistent with chronic inflammatory hepatopathy.

INVOICE

43180

Gastrointestinal

Examination of the **gastrointestinal tract** revealed a stomach and intestine free of stasis, of normal wall thickness, acceptable curvilinear mural detail, and peristaltic activity. Small and large intestine demonstrated normal luminal chyme and stool consistency respectively. No obstructive or overt infiltrative disease was noted. No associated abnormal lymphatic activity was noted.

Pancreas

The base and limbs of the **pancreas** were observed to be largely isoechoic to surrounding omental fat. Some parenchymal remodeling, however, with mild deviation from curvilinear normalcy was observed. Pancreatic duct and capsular irregularities were present consistent with age related changes. If pain upon imaging (+ Murphy sign) was present or if the patient is focally painful in subxiphoid palpation then low-grade smoldering chronic pancreatitis should be suspected.

ULTRASONOGRAPHIC FINDINGS

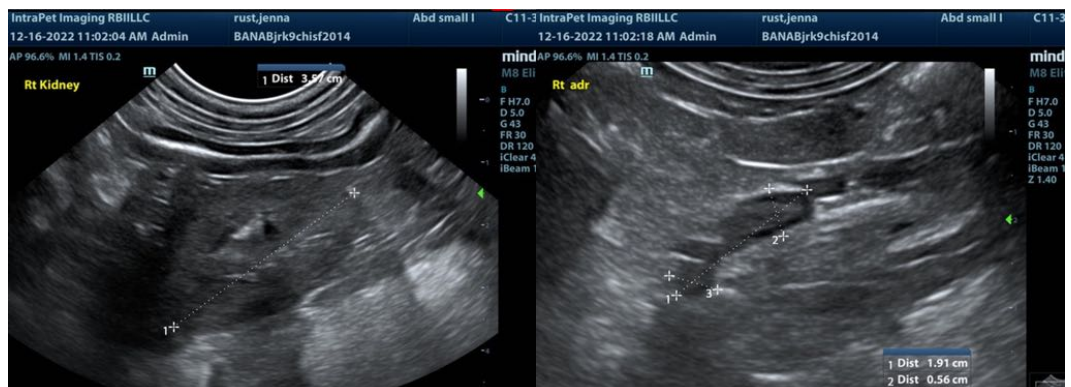
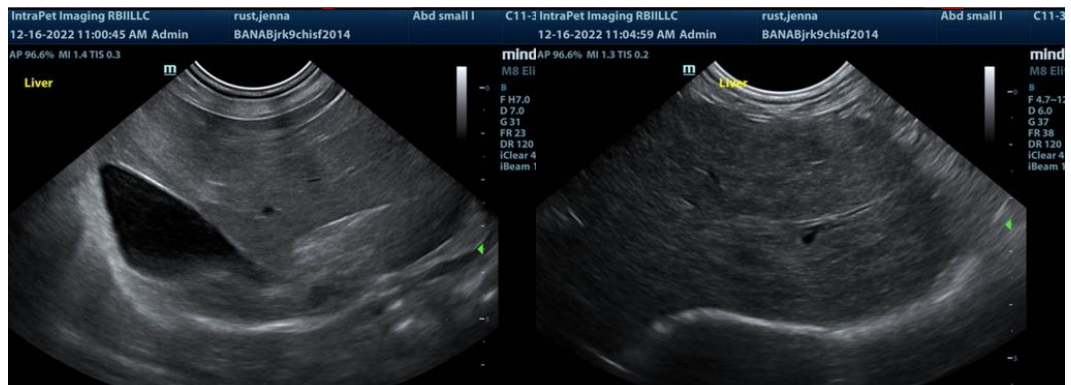Benign hepatopathy with minor remodeling. History of inflammatory component.

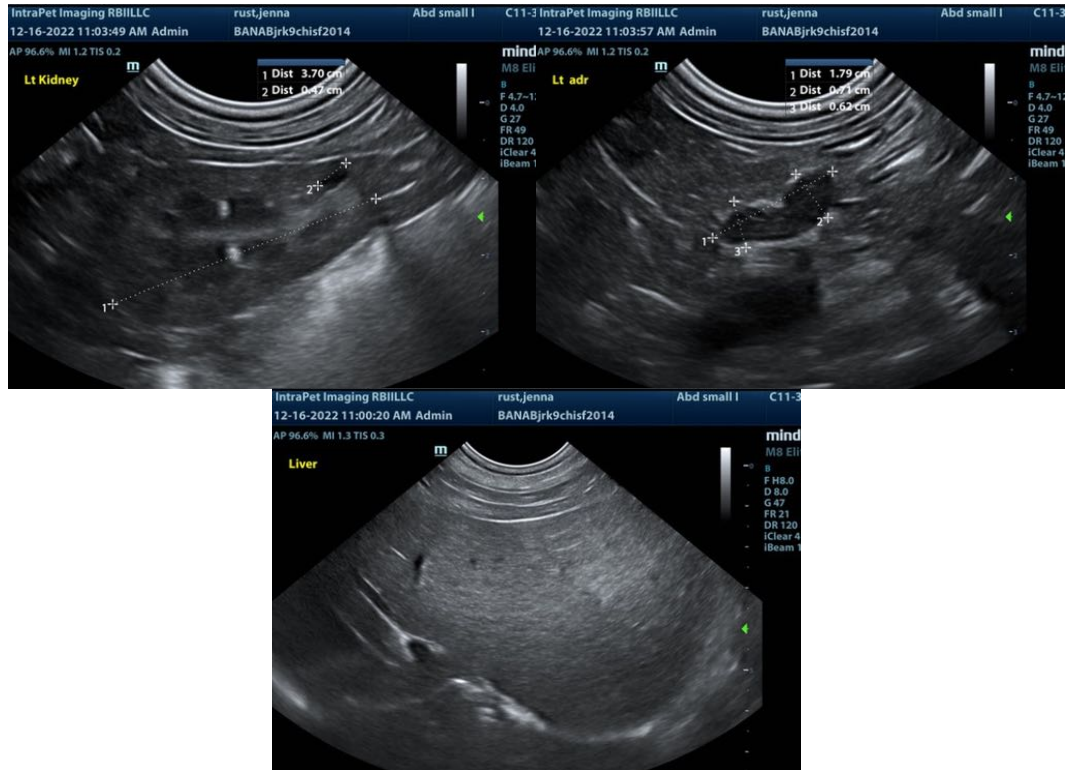
Minor renal mineralization.

Subjectively the abdomen appears benign.

INTERPRETATION OF THE FINDINGS & FURTHER RECOMMENDATIONS

There was no evidence of intrahepatic or extrahepatic shunts. FNA of the liver can be considered for further definition or core biopsy. Diet change to a liver oriented diet, 7-10 days of Metronidazole and reassessment of the bile acids is indicated. Further therapy is recommended based on FNA results.





The information and recommendations provided are based on the images presented by the referring veterinarian. No evaluation can be communicated regarding pathology that was not visible in the image/video clips provided.

Thank you for this referral. If the clinical or image interpretation does not parallel your findings or if I can be of any further assistance please contact me.

Eric Lindquist, DMV, DABVP, Cert. IVUSS, CEO of SonoPath.com
Eric.Lindquist@SonoPath.com