



PATIENT

Chester Southerland

SPECIES

Canine

BREED

Brittany Spaniel

SEX

Male

AGE

5 Years

WEIGHT

38 Pounds

INTERPRETED BY

Eric Lindquist, DMV

DABVP, Cert. IVUSS

IMAGING PERFORMED BY

Dr. James Hornbuckle

HOSPITAL NAME

Golden Isles AH

REFERRING VET

Dr. James Hornbuckle

INVOICE

43506

DATE

12/16/22

PRESENTING CLINICAL SIGNS

Intact Male presented for 2 day h/o persistent fever and malaise, no v/d no c/s, only clinical sign is malaise, fever and inappetence. Px is a traveler on a boat and is rarely in contact with other dogs. Rads were generally unremarkable with only a focal area of distended bowel, not greatly distended but persistent on follow up xrays

Abnormal PE/Chem/CBC/UA Results: WBC 17K, all other labs wnl, Persistent fever btw 103-103.3 over last 2 days

ULTRASONOGRAPHIC EXAMINATION OF THE ABDOMEN

Urinary System

The **urinary bladder**, trigone, and pelvic urethra presented normal thicknesses and normal tone. The ureters were not visible which is normal. No uroliths or sediment were visualized and anechoic urine was present. No evidence of inflammatory or neoplastic changes were noted. Ureteral papillae were normal. The pelvic urethra was imaged 2.0 cm beyond the cystourethral junction.

The **prostate** was uniformly enlarged (2.5 cm) with lobar swelling appeared to impinge upon the urethra and mildly deviate the descending colon. The prostatic tissue was hyperechoic containing focal areas of decreased echogenicity. These changes are suggestive of either chronic inflammatory episodes, benign cystic pathology or both. Underlying neoplasia cannot be completely ruled-out but is lower on the differential list. This presentation is most consistent with benign prostatic hyperplasia with possible active prostatitis. Neutering or off-label Finasteride (Propecia) (0.1-0.5 mg/kg Sid) treatment is indicated +/- FNA or prostatic wash cytology and culture.

The **kidneys** revealed normal size and structure, corticomedullary definition and ratio for this age. The cortices presented largely uniform texture with normal echogenic relationship to liver and spleen. Medullary structure differed distinctly from the cortex and no evidence of pelvic dilation was present. The capsules were acceptably uniform without significant irregularities. The left kidney measured 6.0 cm. The right kidney measured 6.0 cm.

Adrenal Glands

Both **adrenal glands** were visualized and recognized as having normal shape, size, position and echogenicity for this breed. The phrenic vasculature, glandular echogenicity and detail were unremarkable. Capsule, cortex, and medullary definition were normal for this age patient. The right adrenal gland measured 0.80 cm at the cranial pole and 0.60 cm at the caudal pole. The left adrenal gland measured 0.60 cm.

Spleen

The **spleen** presented a smooth homogeneous parenchyma hyperechoic to liver and renal cortical parenchyma. The capsule was smooth without noticeable expansion or deviation from within the spleen or adjacent pathology. The splenic vasculature demonstrated normal volume without signs of congestion or thrombosis. No sonographic evidence of acute or chronic inflammatory, neoplastic, or infarctual changes were noted.

Liver

The **liver** images submitted revealed subjectively normal liver size, contour, and structure. Parenchymal echogenicity was naturally coarse and hypoechoic to the spleen. Vascular and biliary tracts were of normal volume with no evidence of congestion. The gallbladder presented acceptably thin walls with primarily anechoic content. The cystic and common bile ducts were normal. No pathological hepatic



PATIENT

Chester Southerland

lymphadenopathy was evident. No overt structural evidence of inflammatory, infiltrative or regenerative pathology was evident.

Gastrointestinal

SPECIES

Canine

Examination of the **gastrointestinal tract** revealed a stomach and intestine free of stasis, of normal wall thickness, acceptable curvilinear mural detail, and peristaltic activity. Small and large intestine demonstrated normal luminal chyme and stool consistency respectively. No obstructive or overt infiltrative disease was noted. No associated abnormal lymphatic activity was noted.

BREED

Brittany Spaniel

Pancreas

The base and limbs of the **pancreas** were observed to be largely isoechoic to surrounding omental fat. Pancreatic duct and capsular contour were acceptably normal and parenchyma respected normal curvilinear patterns. No overt evidence of active inflammatory or neoplastic disease was noted.

SEX

Male

ULTRASONOGRAPHIC FINDINGS

- BPH prostate, unremarkable abdomen otherwise

AGE

5 Years

INTERPRETATION OF THE FINDINGS & FURTHER RECOMMENDATIONS

No evidence of visceral disease related to the patient history. Infectious agents likely.

WEIGHT

38 Pounds

INTERPRETED BY

Eric Lindquist, DMV

DABVP, Cert. IVUSS

IMAGING PERFORMED BY

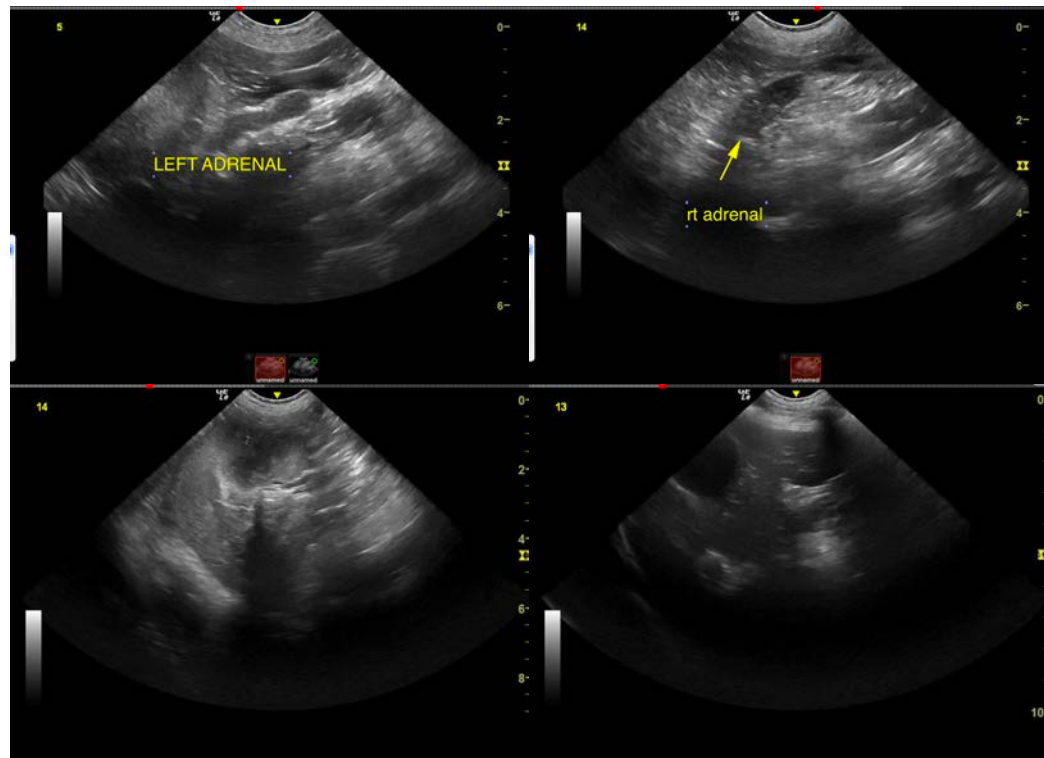
Dr. James Hornbuckle

HOSPITAL NAME

Golden Isles AH

REFERRING VET

Dr. James Hornbuckle



INVOICE

43506

DATE

12/16/22



PATIENT

Chester Southerland

SPECIES

Canine

BREED

Brittany Spaniel

SEX

Male

AGE

5 Years

WEIGHT

38 Pounds

INTERPRETED BY

Eric Lindquist, DMV

DABVP, Cert. IVUSS

IMAGING PERFORMED BY

Dr. James Hornbuckle

HOSPITAL NAME

Golden Isles AH

REFERRING VET

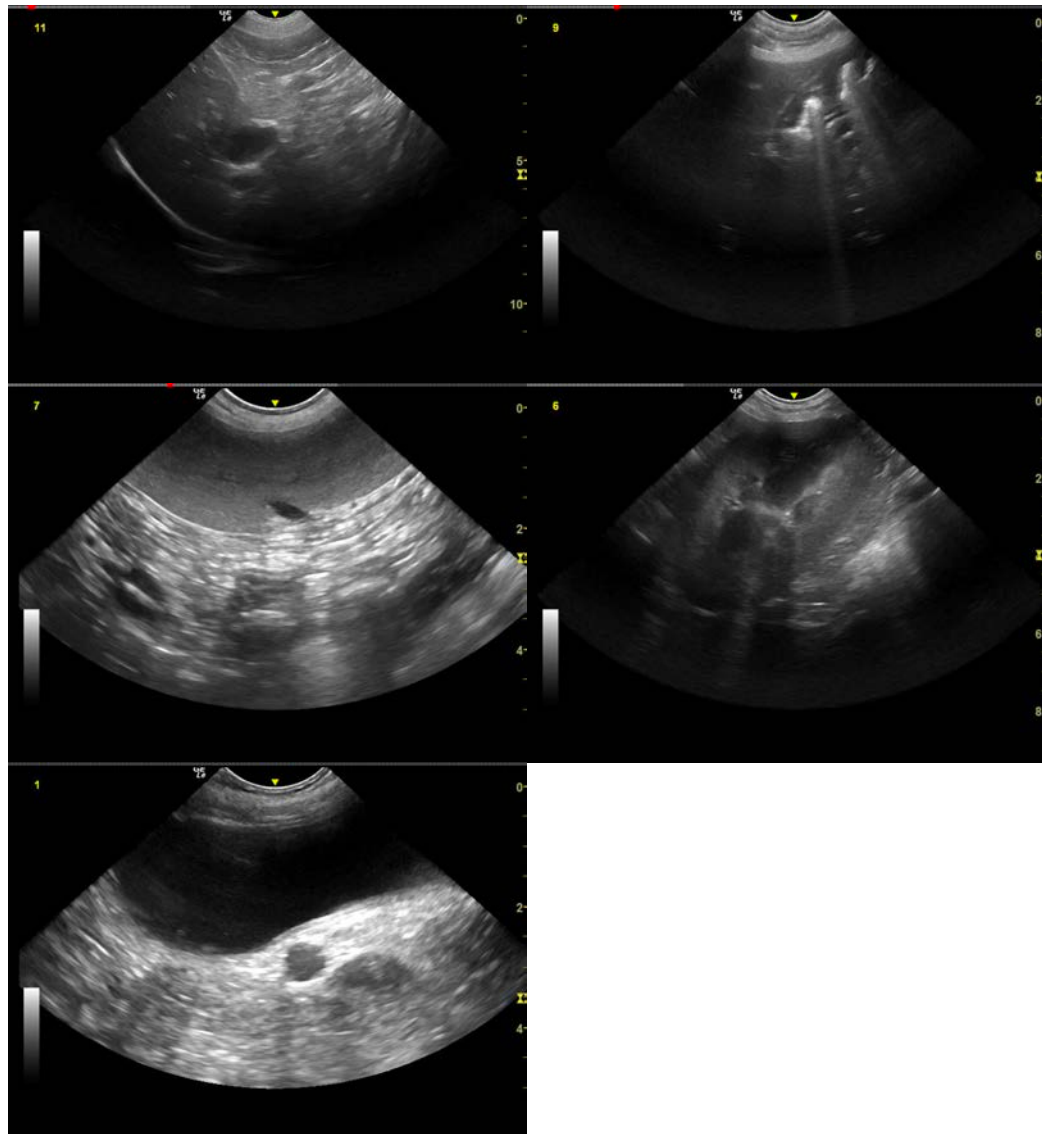
Dr. James Hornbuckle

INVOICE

43506

DATE

12/16/22



The information and recommendations provided are based on the images presented by the referring veterinarian/sonographer. No evaluation can be communicated regarding pathology that was not visible in the image/video clips provided.

Thank you for this referral. If the clinical or image interpretation does not parallel your findings or if I can be of any further assistance please contact me.


Eric Lindquist, DMV, DABVP, Cert. IVUSS, CEO of SonoPath.com

info@SonoPath.com



PATIENT

Chester Southerland



The following is an applicable excerpt from the *Curbside Guide to Diagnosis & Treatment of Sonographic Disease* offered by [SonoPath.com](http://sonopath.com) Lindquist, Frank, Lobetti, and Modler.

SPECIES

Canine

An essential quick guide for every general practitioner and sonographer.

<https://sonopath.com/products/curbside-guide-editing-due-release-12012015>

BREED

Brittany Spaniel

Fever of Unknown Origin

<http://www.sonopath.com/FUO>

SEX

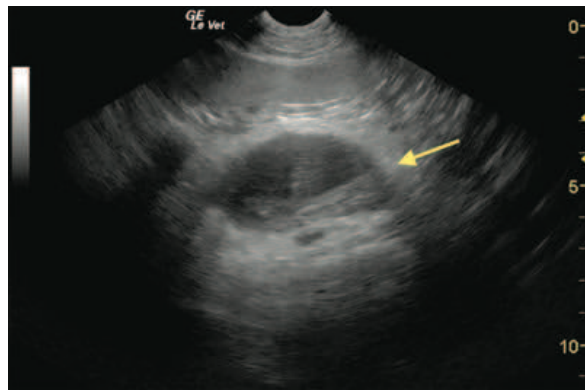
Male

AGE

5 Years

WEIGHT

38 Pounds



Long axis of the mid-abdomen in a dog with an omental abscess after foreign body penetration from the gastrointestinal tract. The hypoechoic necrotic center of the lesion is surrounded by a thick echogenic capsule and hyperechoic mesenteric fat (arrow) indicating focal peritonitis. The linear echogenic needle (5 cm depth) is barely visible owing to the density of the purulent material contained within the abscess.

INTERPRETED BY

Eric Lindquist, DMV

DABVP, Cert. IVUSS

IMAGING PERFORMED BY

Dr. James Hornbuckle

HOSPITAL NAME

Golden Isles AH

Description: The definition of a fever of unknown origin (FUO) has not been clearly defined for animals. Currently, it is either understood to be a fever that does not resolve within the period one would expect for a “self-limiting infection” being treated with appropriate antimicrobial therapy, or that for which an underlying diagnosis has not been determined despite considerable diagnostic effort. The common causes of FUO were summarized concisely in a presentation at the American College of Veterinary Internal Medicine 2004 Forum. The presenters synthesized information from three veterinary papers on the subject, which suggested the following:

REFERRING VET

Dr. James Hornbuckle

INVOICE

43506

DATE

12/16/22

Final Diagnosis	Bennett (dogs & cats)	Dunn and Dunn (dogs only)	Lunn (dogs & one cat)	Total	Percent
Infection	21	16	10	47	28
Immune	18	22	6	46	27
Bone marrow disease	4	22	2	28	16


PATIENT

Chester Southerland

SPECIES

Canine

BREED

Brittany Spaniel

SEX

Male

AGE

5 Years

WEIGHT

38 Pounds

INTERPRETED BY

Eric Lindquist, DMV

DABVP, Cert. IVUSS

IMAGING PERFORMED BY

Dr. James Hornbuckle

HOSPITAL NAME

Golden Isles AH

REFERRING VET

Dr. James Hornbuckle

INVOICE

43506

DATE

12/16/22

Final Diagnosis	Bennett (dogs & cats)	Dunn and Dunn (dogs only)	Lunn (dogs & one cat)	Total	Percent
Neoplasia (outside marrow)	0	10	2	12	7
Miscellaneous	2	12	2	16	9
No diagnosis	0	19	2	21	12
TOTALS	45	101	24	170	99

The types of infection diagnosed in this case series were varied, ranging from discospondylitis (8 cases), blastomycosis (6), and bacterial endocarditis (4), to leishmaniasis (1), prostatitis (1), and *Ehrlichia canis* infection (1); a multitude of other infectious causes also fell within the spectrum. Of the cases in which immune-mediated disease was found, 44% had immune-mediated polyarthritis. Bone marrow diseases included myeloproliferative disease, myelodysplasia (8), lymphocytic leukemia (8), myeloma (3), chronic granulocytic leukemia (3), lymphoblastic leukemia, and malignant histiocytosis. The types of neoplasia located outside the bone marrow included lymphoma (6), metastatic disease (2), and neoplasms of the lung, spleen, and stomach. Finally, miscellaneous diseases included hypertrophic osteodystrophy (6), meningitis (3), portosystemic shunt (3), lymphadenitis (2), panosteitis, and intervertebral disc disease. Overall, the most common causes across all cases were polyarthritis (44), lymphoid neoplasia (15), discospondylitis (8), myelodysplasia (8), hypertrophic osteodystrophy (6), and blastomycosis (6).

Clinical Signs: Animals usually present with either persistent or waxing and waning fevers ranging from 103°F to 106°F. Other clinical signs depend on the underlying cause of the fever. Careful and thorough physical examination is required to assess potential causes.

Diagnostics: F.U.O etiologies are partly related to geography, and thus locale or travel history should factor into a practitioner's diagnostic approach. A patient's lifestyle may also provide clues regarding exposure to certain etiologic agents. Therefore, conducting a thorough history can unveil important pieces of the diagnostic puzzle. Physical examination is especially important and should include an inspection of all accessible lymph nodes, palpation and movement of the joints, a fundic examination, a neurological evaluation, spinal and limb palpation and range of motion tests, and a rectal examination.

A minimum database should include a CBC reviewed by a clinical pathologist, as well as a biochemical profile and urinalysis. Retroviral testing should also be considered in cats. In areas where tick-borne disease is prevalent, in-house testing should be performed early. Advanced laboratory work can include: urine culture, blood culture, and infectious disease panels (PCR and/or serology). In dogs, one may screen for the following infectious agents: *Ehrlichia* spp., *Borrelia burgdorferi*, Rock Mountain Spotted Fever, *Bartonella* spp. (culture and PCR), and *Leptospira* spp. in cases of hepatic or renal involvement. In cats, one should evaluate for FeLV, FIV, feline infectious peritonitis (FIP) virus, toxoplasmosis, *Hemoplasma* spp. (*Mycoplasma*), and *Bartonella* spp. (culture and PCR). Testing for *Ehrlichia* spp., *Rickettsia* spp., and *Anaplasma phagocytophilum* can also be considered. A fungal assay is indicated if the patient lives in or has had exposure to a region with a higher incidence of fungal disease. Other infectious disease tests may be performed depending on the geographical location of the pet. Screening for *Brucella* should be done in breeding dogs. Immune-mediated disease screening can include a Coomb's test, a slide agglutination test (if the patient is anemic), and an antinuclear antibody (ANA) test. Immune disease is often a diagnosis of exclusion.



PATIENT

Chester Southerland

SPECIES

Canine

BREED

Brittany Spaniel

SEX

Male

AGE

5 Years

WEIGHT

38 Pounds

INTERPRETED BY

Eric Lindquist, DMV

DABVP, Cert. IVUSS

IMAGING PERFORMED BY

Dr. James Hornbuckle

HOSPITAL NAME

Golden Isles AH

REFERRING VET

Dr. James Hornbuckle

INVOICE

43506

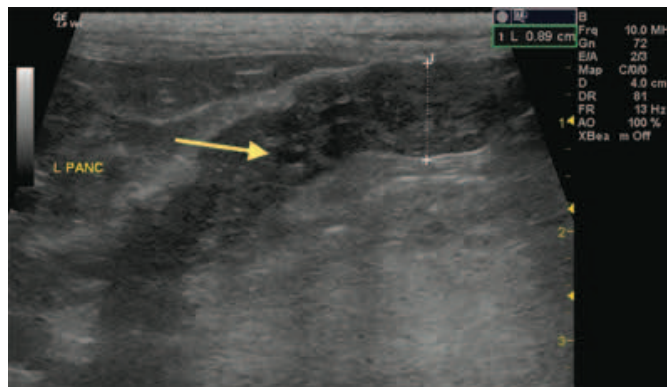
DATE

12/16/22

Imaging should include thoracic radiographs, abdominal ultrasound, and/or abdominal radiographs. Ultrasound can be very useful for assessing evidence of cholangiohepatitis, pyelonephritis, chronic urinary tract infection, abscess formation, peritonitis, and neoplasia; it also permits an examination of the intra-abdominal lymph nodes. An echocardiogram can offer assessment for vegetative endocarditis, whereas spinal radiographs offer assessment for discospondylitis. In cases where all other testing has proven negative and the patient has not responded to broad-spectrum antibiotics and supportive care, arthrocentesis should be considered to evaluate for septic joint disease, immune-mediated polyarthritis, and infectious disease. Finally, one can consider assessing the cerebrospinal fluid for meningoencephalitis, GME, and meningitis/arteritis. A bone marrow exam should be performed if blood dyscrasias are noted on the CBC.

Treatment: Treatment of the fever depends entirely on the underlying cause. Ideally, a thorough diagnostic plan will yield a diagnosis that will guide the appropriate therapeutic course. However, if an exhaustive approach has not produced a definitive diagnosis and there is no response to broad-spectrum antibiotics, trial therapy with immunosuppressive agents such as prednisolone can be considered to treat presumed immune-mediated diseases. Given the potential for negative sequelae should an underlying infection be present, one must be certain that the investigation is thorough and monitor the patient's response carefully.

Conclusion: If a documented fever has not responded to antibiotics, antipyretics, or general nursing care, it is important to obtain a diagnosis to guide more specific treatment. A systematic physical examination and thorough history-taking will help inform further diagnostics in addition to what is revealed by the minimum database.



Long axis of the left pancreatic limb (between calipers) in a cat with pancreatitis after undergoing a renal transplant. Note the decrease in echogenicity and mild loss of regular echotexture of the swollen and irregularly contoured pancreas. Also note the mild dilation of the pancreatic duct (arrow). Focal peritonitis is evident by increased echogenicity and loss of the linear echotexture of the surrounding mesentery.



PATIENT

Chester Southerland

SPECIES

Canine

BREED

Brittany Spaniel

SEX

Male

AGE

5 Years

WEIGHT

38 Pounds

INTERPRETED BY

Eric Lindquist, DMV

DABVP, Cert. IVUSS

IMAGING PERFORMED BY

Dr. James Hornbuckle

HOSPITAL NAME

Golden Isles AH

REFERRING VET

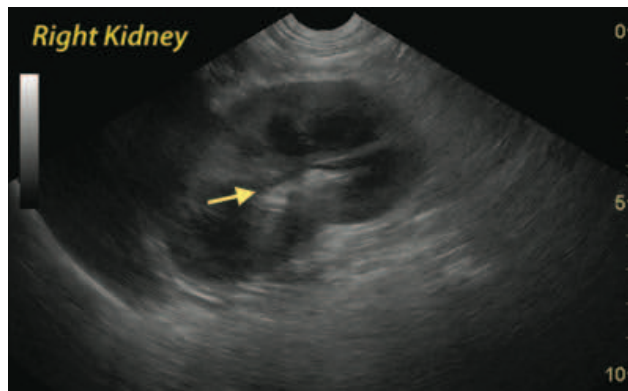
Dr. James Hornbuckle

INVOICE

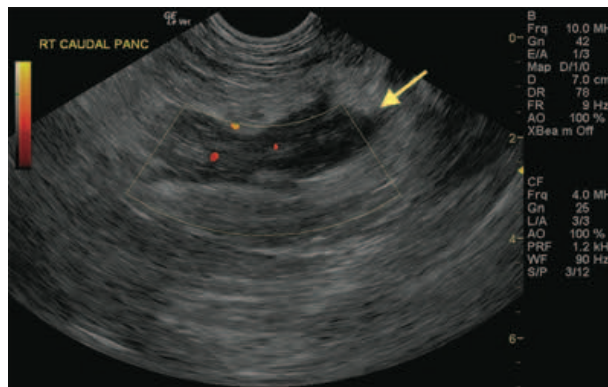
43506

DATE

12/16/22



Long axis of the right kidney in a dog with pyelonephritis. Note the increased echogenicity and irregular outline of the renal crest and diverticuli and the mild dilation of the renal pelvis (arrow).



Long axis of the right pancreatic limb in a dog with acute pancreatitis. The swollen hypochoic pancreas is embedded in hyperechoic mesenteric fat (arrow). Note the regional differences in blood flow intensity within the parenchyma as demonstrated by Power Doppler interrogation compatible with multifocal disruption of vascularization as a sequela of the severe inflammation.

References:

Bennet D. Diagnosis of pyrexia of unknown origin. *In Practice* 1995;17(10):470-81.

Dunn KJ, Dunn JK. Diagnostic investigations in 101 dogs with pyrexia of unknown origin. *J Sm Anim Pract* 1998;39(12):574-80.

Flood J. The diagnostic approach to fever of unknown origin in cats. *Compend Contin Educ Vet* 2009;31(1):26-31.

Flood J. The diagnostic approach to fever of unknown origin in dogs. *Compend Contin Educ Vet* 2009;31(1):14-21.

Lappin MR. The role of blood borne pathogens in feline fever of unknown origin. Proceedings from the American College of Veterinary Internal Medicine, Denver, CO, June 15-18, 2011.

Lunn KF. Fever of unknown origin: a systematic approach to diagnosis. *Compend Contin Educ Vet* 2001;23(11):976-92.

Lunn KF. Fever of unknown origin: appropriate choice of diagnostic tests. Proceedings from the American College of Veterinary Internal Medicine, Minneapolis, MN, June 9-12, 2004.