

IMAGING PERFORMED BY

IntraPet.com



Clinical Sonography & Telecytology

EDUCATIONAL TELECONSULTATION SERVICES™

1-800-838-4268 info@sonopath.com SonoPath.com

**DATE**

12/16/22

**PATIENT**

Bunny Greenwood

**SPECIES**

Canine

**BREED**

Bernese Mtn Dog

**SEX**

Intact Female

**AGE**

12/4/18

**WEIGHT**

90 Pounds

**INTERPRETED BY**

Eric Lindquist, DMV  
DABVP, Cert. IVUSS

**IMAGING PERFORMED BY**

Rachel Brilhart RDMS

**HOSPITAL NAME**

Madonna Vet Clinic

**REFERRING VET**

Dr. Brockett

**INVOICE**

43534

**PRESENTING CLINICAL SIGNS**

Pregnancy Scan.

Current Medications: None listed.

Date of Previous IntraPet Ultrasound: No previous.

Sedation: Not required to complete full diagnostic ultrasound.

Stat Report: Not requested.

**LIMITED ULTRASONOGRAPHIC EXAMINATION**

The urinary bladder, trigone, and pelvic urethra presented normal thicknesses and normal tone. The ureters were not visible which is normal. No uroliths or sediment were visualized and anechoic urine was present. No evidence of inflammatory or neoplastic changes were noted. Ureteral papillae were normal.

The kidneys revealed normal size and structure, corticomedullary definition and ratio for this age. The cortices presented largely uniform texture with normal echogenic relationship to liver and spleen. Medullary structure differed distinctly from the cortex and no evidence of pelvic dilation was present. The capsules were acceptably uniform without significant irregularities. The left kidney measured 7.55 cm. The right kidney measured 7.5 cm.

The uterus was unremarkable. The right ovary measured 0.85 cm x 1.0 cm. The left ovary revealed active corpus luteum, measuring 2.05 cm x 1.34 cm caudal and 0.75 cm cranial, with minor cysts.

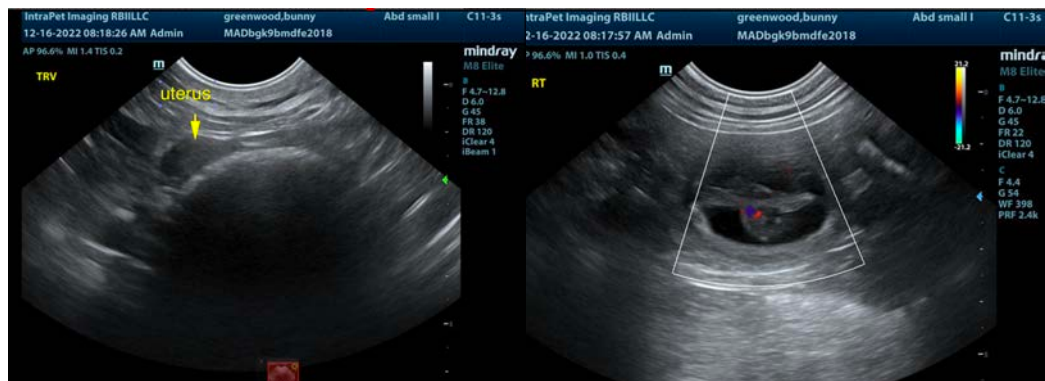
Viable pregnancy with at least 5-6 fetuses. Normal heartbeats. Anechoic amniotic fluid present. Fetal length was approximately 2.4 cm head to rump. No evident pathology. Approximately 25-28 days gestation.

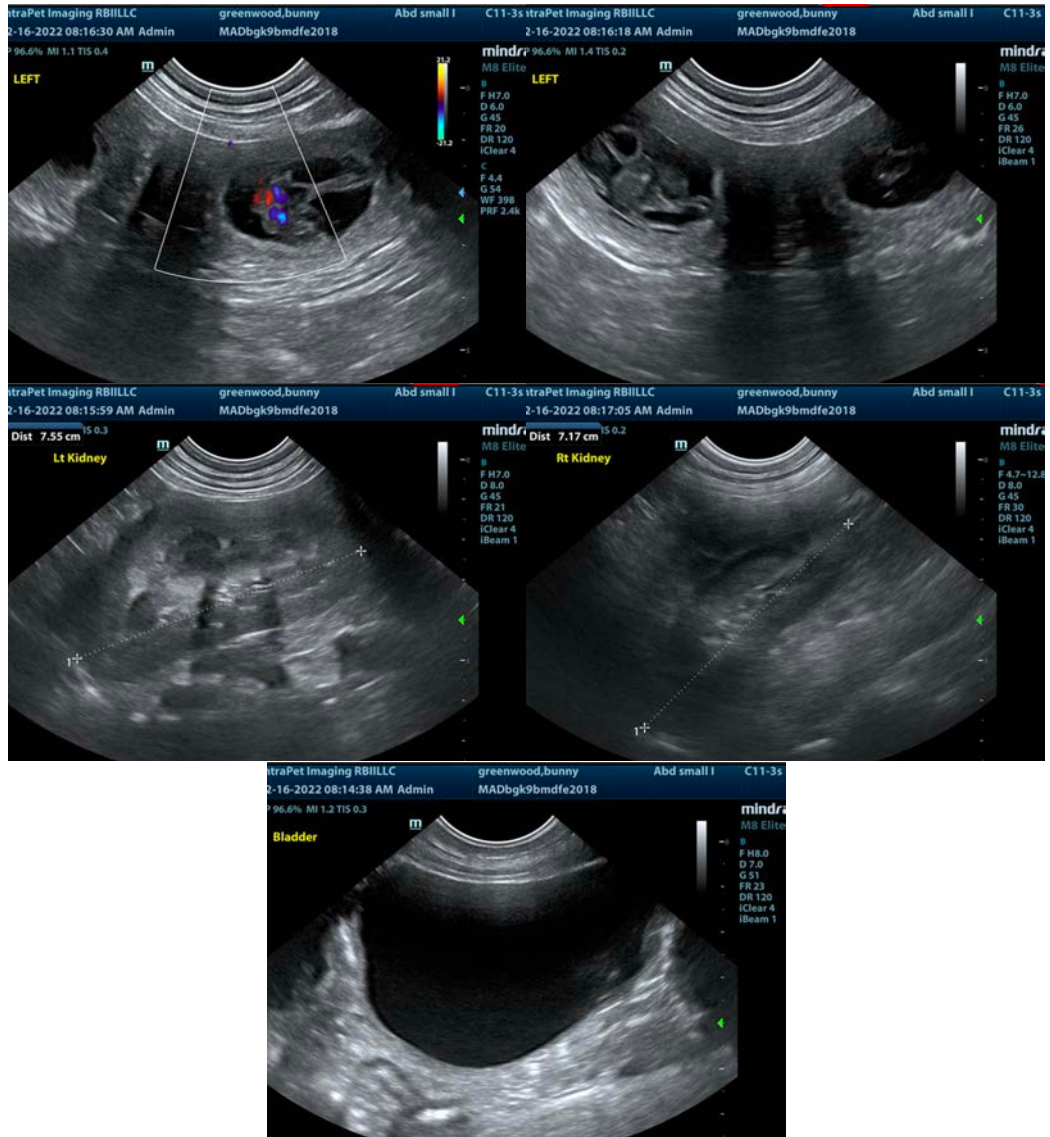
**ULTRASONOGRAPHIC FINDINGS**

- Viable pregnancy (at least 5-6 fetuses) approximately 25-28 days with corpus luteum on the right ovary

**INTERPRETATION OF THE FINDINGS & FURTHER RECOMMENDATIONS**

Viable pregnancy. No evidence of pathology.





The information and recommendations provided are based on the images presented by the referring veterinarian/sonographer. No evaluation can be communicated regarding pathology that was not visible in the image/video clips provided.

Thank you for this referral. If the clinical or image interpretation does not parallel your findings or if I can be of any further assistance please contact me.

**Eric Lindquist**, DMV, DABVP, Cert. IVUSS, CEO of SonoPath.com  
[info@SonoPath.com](mailto:info@SonoPath.com)