



PATIENT

Abbie Salander

PRESENTING CLINICAL SIGNS

History: Hx of having only 1 kidney. Hx of chronic vomiting. Currently on hydrolyzed protein diet

SPECIES

Feline

ULTRASONOGRAPHIC EXAMINATION OF THE ABDOMEN

Urinary System

BREED

Domestic Medium Hair

The **urinary bladder**, trigone, and pelvic urethra presented normal thicknesses and normal tone. The ureters were not visible which is normal. No uroliths or sediment were visualized and anechoic urine was present. No evidence of inflammatory or neoplastic changes was noted. Ureteral papillae were normal.

SEX

Spayed female

The left kidney was severely dystrophic with end stage degenerative changes. The left kidney measured 1.76 cm in length. The right kidney was normal in size and contour with slight pinpoint mineralization and trace pyelectasia. The right kidney measured 4.4 cm.

AGE

16 years

Adrenal Glands

WEIGHT

12 lbs

Both **adrenal glands** were visualized and recognized as having normal shape, size, position and echogenicity for this breed. The phrenic vasculature, glandular echogenicity and detail were unremarkable. Capsule, cortex, and medullary definition were normal for this age patient.

INTERPRETED BY

Eric Lindquist, DMV
DABVP, Cert. IVUSS

Spleen

IMAGING PERFORMED BY

Dr. Waffle

The **spleen** presented a smooth homogeneous parenchyma hyperechoic to liver and renal cortical parenchyma. The capsule was smooth without noticeable expansion or deviation from within the spleen or adjacent pathology. The splenic vasculature demonstrated normal volume without signs of congestion or thrombosis. No sonographic evidence of acute or chronic inflammatory, neoplastic, or infarctual changes was noted.

HOSPITAL NAME

Torch Lake VC

Liver

REFERRING VET

Dr. Waffle

The **liver** images from right and left intercostal as well as subcostal views revealed subjectively normal liver size, contour, and structure. Some age-related parenchymal remodeling was noted but likely not clinically significant at this time. Vascular and biliary tracts were of normal volume and no evidence of congestion was noted. The gallbladder presented some dependent debris with essentially normal contour. The cystic and common bile ducts were normal. No overt evidence of active inflammatory, infiltrative or regenerative pathology was noted but should be paired with current or past LE elevations regarding any clinical significance to this presentation. The hepatic lymph nodes were unremarkable.

INVOICE

43168

Gastrointestinal

DATE

12/16/22

The **stomach** was filled with progressively shadowing material. I suspect hairball accumulation. The small intestines and colon were unremarkable.



PATIENT

Pancreas

Abbie Salander

The base and limbs of the **pancreas** were observed to be largely isoechoic to surrounding omental fat. Pancreatic duct and capsular contour were acceptably normal and parenchyma respected normal curvilinear patterns. No overt evidence of active inflammatory or neoplastic disease was noted.

SPECIES

Feline

ULTRASONOGRAPHIC FINDINGS

BREED

Dystrophic left kidney, end stage.

Domestic Medium Hair

Mild degenerative right renal changes.

SEX

INTERPRETATION OF THE FINDINGS & FURTHER RECOMMENDATIONS

Spayed female

The left kidney is present, yet significantly small and dystrophic owing to degenerative progression or primary dysplasia with secondary degenerative changes. The gastric presentation is most consistent with hairball accumulation. Hairball therapy is warranted over the next 3 weeks with a recheck sonogram at that time. Full urinary work-up is warranted if not already performed.

AGE

16 years

WEIGHT

12 lbs

INTERPRETED BY

Eric Lindquist, DMV
DABVP, Cert. IVUSS

IMAGING PERFORMED BY

Dr. Waffle

HOSPITAL NAME

Torch Lake VC

REFERRING VET

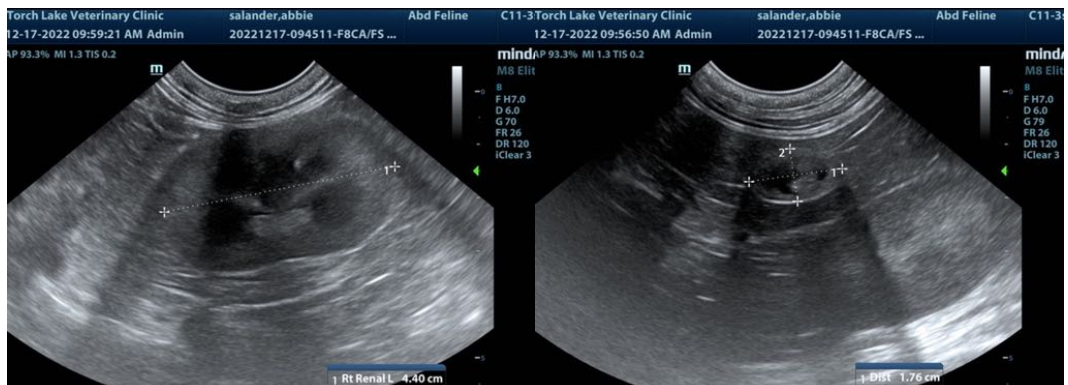
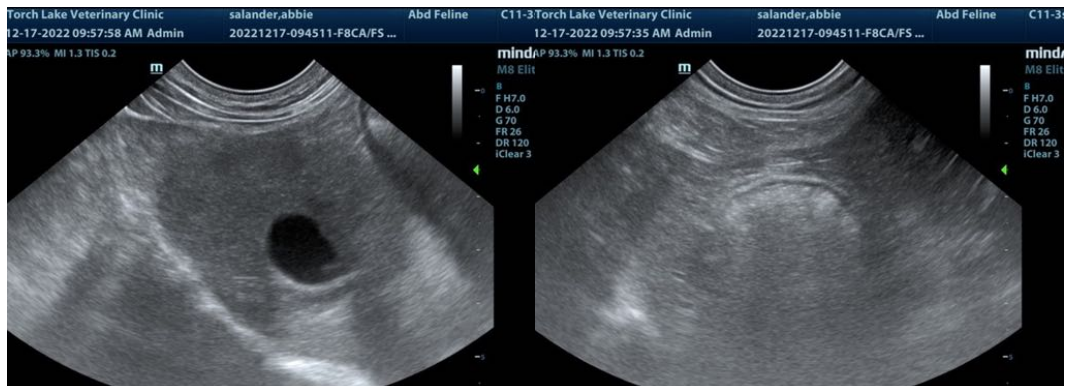
Dr. Waffle

INVOICE

43168

DATE

12/16/22



The information and recommendations provided are based on the images presented by the referring veterinarian/sonographer. No evaluation can be communicated regarding pathology that was not visible in the image/video clips provided.

Thank you for this referral. If the clinical or image interpretation does not parallel your findings or if I



PATIENT

can be of any further assistance please contact me.

Abbie Salander

Eric Lindquist, DMV, DABVP, Cert. IVUSS, CEO of SonoPath.com
info@SonoPath.com

SPECIES

Feline

BREED

Domestic Medium Hair

SEX

Spayed female

AGE

16 years

WEIGHT

12 lbs

INTERPRETED BY

Eric Lindquist, DMV
DABVP, Cert. IVUSS

**IMAGING
PERFORMED BY**

Dr. Waffle

HOSPITAL NAME

Torch Lake VC

REFERRING VET

Dr. Waffle

INVOICE

43168

DATE

12/16/22