

PATIENT PRESENTING CLINICAL SIGNS

PATIENT Lui Flower
SPECIES Canine
BREED Chihuahua
SEX Neutered male
AGE Unknown
WEIGHT lbs

PRESENTING CLINICAL SIGNS
 History: Coughing. Some response to Doxycycline and cough suppressants. No heart murmur ausculted.
 Abnormal PE/Chem/CBC/UA Results: none provided.

ULTRASONOGRAPHIC EXAMINATION OF THE HEART

The echocardiogram in this patient demonstrated normal **left atrial** size based on 3 separate methods of LA evaluation. The cranial and caudal **mitral** valve leaflets presented normal linear structure, extension in systole, and union in diastole with normal kinesis. The **left ventricle** presented thicknesses with linear contour and was not dilated nor restricted. The **myocardium** presented normal echogenicity without subjective evidence of significant fibrotic or ischemic disease. **Contractility** of the ventricular walls was adequate and in normal range for this patient evidenced by the fractional shortening measurement and subjective evaluation of the different regions of the myocardium. The **left ventricular outflow** tract demonstrated normal laminar flow and subjective structural integrity. The **right atrium** and auricle revealed normal size, structure and content. No evidence of masses was noted. **Tricuspid** valvular assessment demonstrated adequate linear morphology and kinesis. The **right ventricle** was of normal size (1/3 diameter of LV), chordae structure, myocardial echogenicity and thickness. **Pulmonary outflow** tract assessment revealed normal valve structure, laminar flow, and diameter (approx. 1:1 pa/ao ratio). No visible **pericardial** or free pleura fluid was noted. The cranial **mediastinum and pericardial and extra-cardiac regions** were free of masses in the visible window.

INTERPRETED BY

Eric Lindquist, DMV
 DABVP, Cert. IVUSS

IMAGING PERFORMED BY

Potomac Mobile
 Veterinary Ultrasound

HOSPITAL NAME

Glenkirk AH

REFERRING VET

Dr. Jarrett

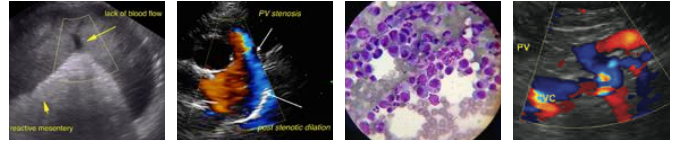
INVOICE

94665

DATE

12/16/21

CANINE CARDIAC PARAMETERS	MR VMAX (m/s)	TR VMAX (m/s)	LA/AO (Boon method)	LA/AO (Heart Base; Swe)	FS (%)	EF (%)	EPSS (cm)
NORMAL PARAMETER	4.5-5.5	<2.7	1.3	<1.6	28-40	40-100	<0.6
PATIENT			1.1	1.2	52	85	0.27
CANINE CARDIAC PARAMETERS	HR (BPM)	AV VMAX (m/s)	PV MAX (m/s)	BODY WEIGHT (kg)	LA (2D short axis Base view) (cm)	LVIDd (Avg; 2D and m-mode short axis) (cm)	LVIDs (Avg; 2D and m-mode short axis) (cm)
NORMAL PARAMETER	50-100	0.7-1.7	0.7-1.6				
PATIENT		1.12	0.88		1.96	2.15	



PATIENT **ULTRASONOGRAPHIC FINDINGS**

Lui Flower Normal echocardiogram.

SPECIES **INTERPRETATION OF THE FINDINGS & FURTHER RECOMMENDATIONS**

Canine

The cough is not cardiogenic in this patient. The chamber sizes and function were normal. Primary respiratory protocol is recommended based on radiographic and clinical findings. There was no evidence of pulmonary hypertension.

BREED

Chihuahua

SEX

Neutered male

AGE

Unknown

WEIGHT

lbs

INTERPRETED BY

Eric Lindquist, DMV
DABVP, Cert. IVUSS

IMAGING PERFORMED BY

Potomac Mobile
Veterinary Ultrasound

HOSPITAL NAME

Glenkirk AH

REFERRING VET

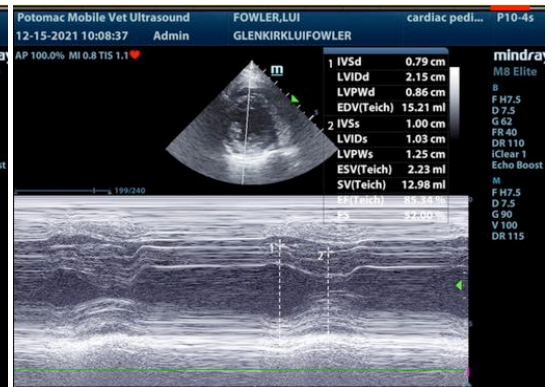
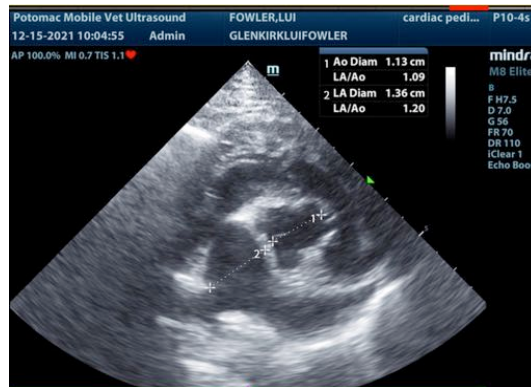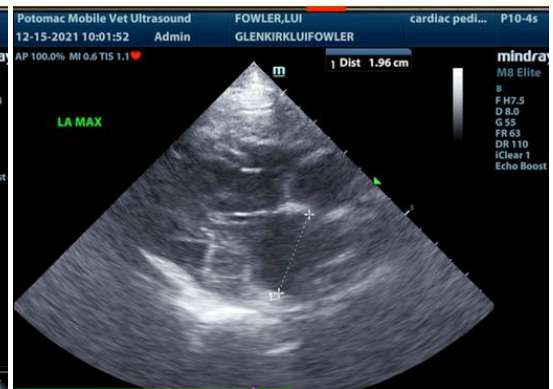
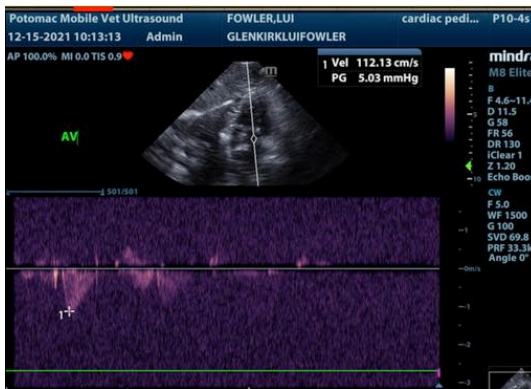
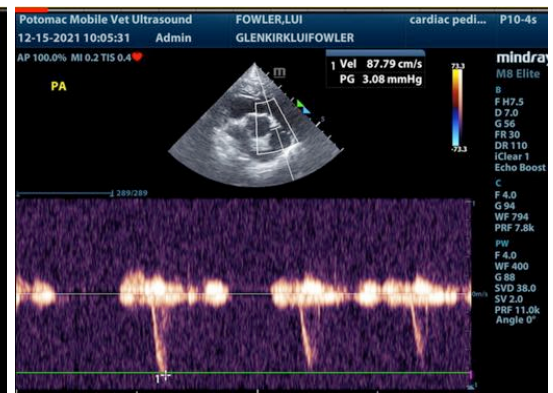
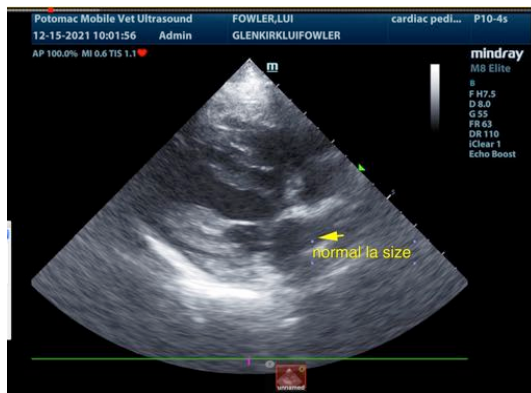Dr. Jarrett

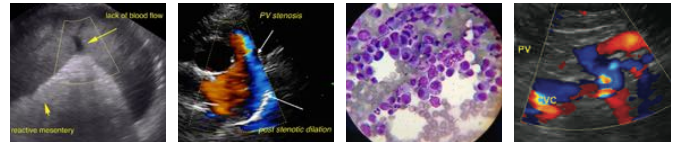
INVOICE

94665

DATE

12/16/21





PATIENT

Lui Flower

SPECIES

Canine

BREED

Chihuahua

SEX

Neutered male

AGE

Unknown

WEIGHT

lbs

INTERPRETED BY

Eric Lindquist, DMV
DABVP, Cert. IVUSS

IMAGING PERFORMED BY

Potomac Mobile
Veterinary Ultrasound

HOSPITAL NAME

Glenkirk AH

REFERRING VET

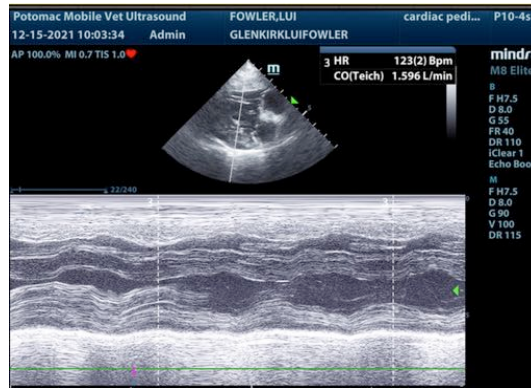
Dr. Jarrett

INVOICE

94665

DATE

12/16/21



The information and recommendations provided are based on the images presented by the referring veterinarian. No evaluation can be communicated regarding pathology that was not visible in the image/video clips provided.

Thank you for this referral. If the clinical or image interpretation does not parallel your findings or if I can be of any further assistance please contact me.

Eric Lindquist, DMV, DABVP, Cert. IVUSS

CEO of Sonopath.com

info@SonoPath.com