



PATIENT

Otis Roberts

SPECIES

Canine

BREED

Corgi

SEX

Neutered male

AGE

9 years

WEIGHT

38.4 lbs

INTERPRETED BY

Eric Lindquist, DMV
DABVP, Cert. IVUSS

IMAGING PERFORMED BY

Rachel South, DVM

HOSPITAL NAME

River Valley AH

REFERRING VET

Dr. South

INVOICE

69299

DATE

12/15/25

PRESENTING CLINICAL SIGNS

History: Otis has a history of chronically vomiting undigested food and/or bile. He also has a history of occasional pancreatitis. P is currently on Cerenia and omeprazole PRN. Owner able to usually minimize vomiting with medications and only having to give a couple times a week. Frequency of vomiting has started to increase and O having to give medications daily. P still eating and drinking normal with normal stool production.

Abnormal PE/Chem/CBC/UA Results: Bloodwork on 12/12 revealed a mildly elevated pancreatic lipase, otherwise unremarkable. (Attached)

ULTRASONOGRAPHIC EXAMINATION OF THE ABDOMEN

Urinary System

The **urinary bladder**, trigone, and pelvic urethra presented normal thicknesses and normal tone. The ureters were not visible which is normal. No uroliths or sediment were visualized and anechoic urine was present. No evidence of inflammatory or neoplastic changes was noted. Ureteral papillae were normal.

The **right kidney** revealed normal size and structure, corticomedullary definition and ratio for this age. The cortices presented largely uniform texture with normal echogenic relationship to liver and spleen. Medullary structure differed distinctly from the cortex and no evidence of pelvic dilation was present. The capsule was acceptably uniform without significant irregularities. The right kidney measured 6.7 cm. The left kidney was severely dystrophic and subnormal in size. The left kidney measured 1.7 cm with mineralization. This is likely secondary to end stage pelvic obstruction.

The residual prostate measured 0.5 cm.

Adrenal Glands

Both **adrenal glands** were visualized and recognized as having normal shape, size, position and echogenicity for this breed. The phrenic vasculature, glandular echogenicity and detail were unremarkable. Capsule, cortex, and medullary definition were normal for this age patient. The left adrenal gland measured 2.4 x 0.45 cm at the caudal pole and 0.45 cm at the cranial pole. The right adrenal gland measured 2.71 x 0.4 cm.

Spleen

The **spleen** presented a smooth homogeneous parenchyma hyperechoic to liver and renal cortical parenchyma. The capsule was smooth without noticeable expansion or deviation from within the spleen or adjacent pathology. The splenic vasculature demonstrated normal volume without signs of congestion or thrombosis. No sonographic evidence of acute or chronic inflammatory, neoplastic, or infarctual changes was noted.



PATIENT

Otis Roberts

SPECIES

Canine

BREED

Corgi

SEX

Neutered male

AGE

9 years

WEIGHT

38.4 lbs

INTERPRETED BY

Eric Lindquist, DMV
DABVP, Cert. IVUSS

IMAGING PERFORMED BY

Rachel South, DVM

HOSPITAL NAME

River Valley AH

REFERRING VET

Dr. South

INVOICE

69299

DATE

12/15/25

Liver

The **liver** images submitted revealed subjectively normal liver size, contour, and structure. Parenchymal echogenicity was naturally coarse and hypoechoic to the spleen. Vascular and biliary tracts were of normal volume with no evidence of congestion. The gallbladder presented acceptably thin walls with primarily anechoic content. The cystic and common bile ducts were normal. No pathological hepatic lymphadenopathy was evident. No overt structural evidence of inflammatory, infiltrative or regenerative pathology was evident.

Gastrointestinal

The **gastrointestinal tract** revealed hyperperistalsis and spastic small intestine.

Pancreas

The base and limbs of the **pancreas** were observed to be largely isoechoic to surrounding omental fat. Some parenchymal remodeling, however, with mild deviation from curvilinear normalcy was observed. Pancreatic duct and capsular irregularities were present consistent with age related changes. If pain upon imaging (+ Murphy sign) was present or if the patient is focally painful in subxiphoid palpation then low-grade smoldering chronic pancreatitis should be suspected.

ULTRASONOGRAPHIC FINDINGS

Vestigial left kidney, normal right kidney.

Otherwise, unremarkable abdomen with minor spastic bowel.

INTERPRETATION OF THE FINDINGS & FURTHER RECOMMENDATIONS

The left kidney is not likely functional. Management for gastritis with the following protocol should prove effective. Hydrolyzed diet may be in this patient's best interest.

Helicobacter/Gastritis protocol

A clinical trial of **Zithromax (Dogs: 5-10 mg/kg p.o. q24h. May increase dosing interval to q48h after 3-5 days of treatment)**, **Metronidazole (10-20 mg/kg p.o. b.i.d.)**, **Pepcid (0.5-1 mg/kg s.i.d.)** and **Sucralfate (0.5-2 g/dog PO)** or **Omeprazole (1 mg/kg p.o. s.i.d.)** over the next 3 weeks along with a **novel-protein or hydrolyzed diet** with slurry feeding b.i.d./t.i.d. over the next 2-4 days and then increase to canned diet bid. Dry food should be avoided over the next 4 weeks. A recheck sonogram to assess GI improvement or progression would be ideal in 4 weeks.



PATIENT

Otis Roberts

SPECIES

Canine

BREED

Corgi

SEX

Neutered male

AGE

9 years

WEIGHT

38.4 lbs

INTERPRETED BY

Eric Lindquist, DMV
DABVP, Cert. IVUSS

IMAGING PERFORMED BY

Rachel South, DVM

HOSPITAL NAME

River Valley AH

REFERRING VET

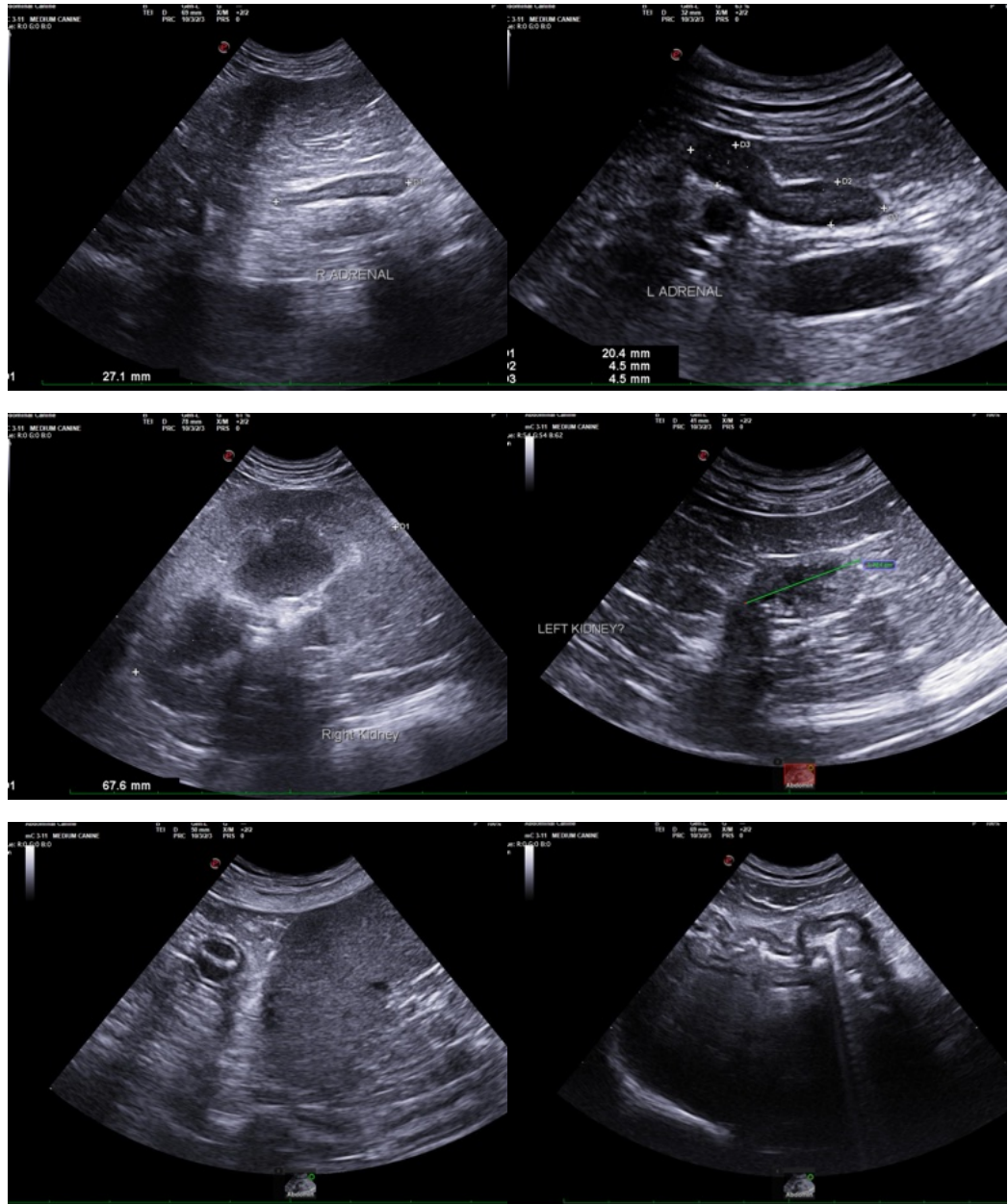
Dr. South

INVOICE

69299

DATE

12/15/25





PATIENT

Otis Roberts

SPECIES

Canine

BREED

Corgi

SEX

Neutered male

AGE

9 years

WEIGHT

38.4 lbs

INTERPRETED BY

Eric Lindquist, DMV
DABVP, Cert. IVUSS

IMAGING PERFORMED BY

Rachel South, DVM

HOSPITAL NAME

River Valley AH

REFERRING VET

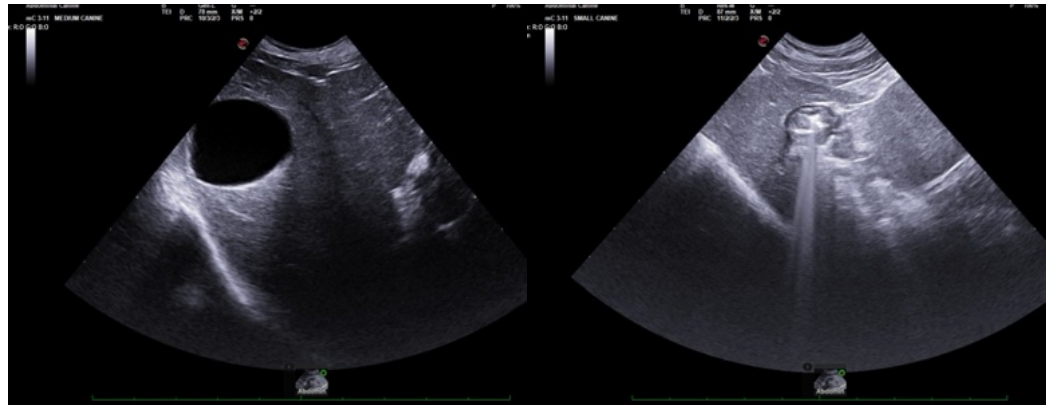
Dr. South

INVOICE

69299

DATE

12/15/25



The information and recommendations provided are based on the images presented by the referring veterinarian/sonographer. No evaluation can be communicated regarding pathology that was not visible in the image/video clips provided.

Thank you for this referral. If the clinical or image interpretation does not parallel your findings or if I can be of any further assistance please contact me.

Eric Lindquist, DMV, DABVP (CFM), Cert. IVUSS, CEO of SonoPath.com

info@SonoPath.com