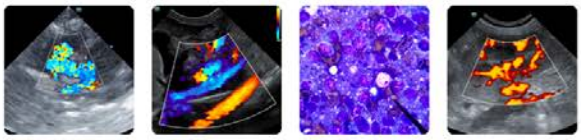

DATE
12/15/25

PATIENT
Koda Krueger

SPECIES
Canine

BREED
German Shepherd x

SEX
Neutered Male

AGE
1/29/18

WEIGHT
28.7 kg

INTERPRETED BY
Eric Lindquist, DMV, DABVP, Cert. IVUSS

HOSPITAL NAME
Eastern Animal Hospital

REFERRING VET
Dr. Ashland

INVOICE
72575

PRESENTING CLINICAL SIGNS

Patient History: Presented for diarrhea 11/20/25 O elected outpatient supportive care. Recheck on 11/24/25 with diagnostics showed sublumbar LN enlargement on radiographs and rectal exam showed large left sided perianal mass. FNA came back consistent with AGASACA.

Current Medications: Gabapentin 300mg morning of AUS, Trazodone 200mg morning of AUS, Maropitant 60mg morning of AUS, Omeprazole 20mg morning of AUS
Labwork Results: Labwork not attached, reported as: Sublumbar lymphadenopathy. Mild elevation of liver values - ALT 203, ALP 327, GGT 13. Previously WNL in August of this year. FNA of perianal mass came back consistent with AGASACA
Date of Previous IntraPet Ultrasound: No previous.
Sedation: Not required to complete full diagnostic ultrasound.
Stat Report: STAT requested.
Imaging Performed by: Rachel Brilhart, RDMS.

ULTRASONOGRAPHIC EXAMINATION OF THE ABDOMEN

Urinary System

The **urinary bladder**, trigone, and pelvic urethra presented normal thicknesses and normal tone. The ureters were not visible which is normal. No uroliths or sediment were visualized and anechoic urine was present. No evidence of inflammatory or neoplastic changes were noted. Ureteral papillae were normal. The pelvic urethra was imaged 3.0 cm beyond the cystourethral junction.

The **kidneys** revealed normal size and structure, corticomedullary definition and ratio for this age. The cortices presented largely uniform texture with normal echogenic relationship to liver and spleen. Medullary structure differed distinctly from the cortex and no evidence of pelvic dilation was present. The capsules were acceptably uniform without significant irregularities. Right kidney measured 7.5 cm.

Adrenal Glands

Both **adrenal glands** were visualized and recognized as having normal shape, size, position and echogenicity for this breed. The phrenic vasculature, glandular echogenicity and detail were unremarkable. Capsule, cortex, and medullary definition were normal for this age patient. Right adrenal gland measured 3.37 cm x 0.56 cm at the caudal pole and 0.60 cm at the cranial pole.

Spleen

The **spleen** presented a smooth homogeneous parenchyma hyperechoic to liver and renal cortical parenchyma. The capsule was smooth without noticeable expansion or deviation from within the spleen or adjacent pathology. The splenic vasculature demonstrated normal volume without signs of congestion or thrombosis. No sonographic evidence of acute or chronic inflammatory, neoplastic, or infarctual changes were noted.

Liver

The **liver** images submitted revealed subjectively normal liver size, contour, and structure. Parenchymal echogenicity was naturally coarse and hypoechoic to the spleen. Vascular and biliary tracts were of normal volume with no evidence of congestion. The gallbladder presented acceptably thin walls with primarily anechoic content. The cystic and common bile ducts were normal. No pathological hepatic lymphadenopathy was evident. No overt structural evidence of inflammatory, infiltrative or regenerative pathology was evident.

Gastrointestinal

An undifferentiated pelvic mass was noted measuring approximately 10+ cm, deviating the colon and upper GI tract. A cluster of multiple lymph nodes comprised the mass. Secondary free fluid noted owing to lymphatic obstruction. The pelvic mass encompassed the colon, causing an obstructive pattern. The pathology appears to enter into the colorectum, possible extension of the mass or separate involvement of the mass.
The entire gastrointestinal tract was obstructed owing to the pelvic pathology.

Pancreas

The base and limbs of the **pancreas** were observed to be largely isoechoic to surrounding omental fat. Pancreatic duct and capsular contour were acceptably normal and parenchyma respected normal curvilinear patterns. No overt evidence of active inflammatory or neoplastic disease was noted.

ULTRASONOGRAPHIC FINDINGS

- Colorectal mass with iliac and pelvic lymph node involvement and secondary obstructive GI pattern.

INTERPRETATION OF THE FINDINGS & FURTHER RECOMMENDATIONS

Immediate ultrasound guided FNA and STAT cytology with chemotherapeutic reduction approach recommended to liberate the GI tract if possible. The masses are not resectable. Prognosis is poor.

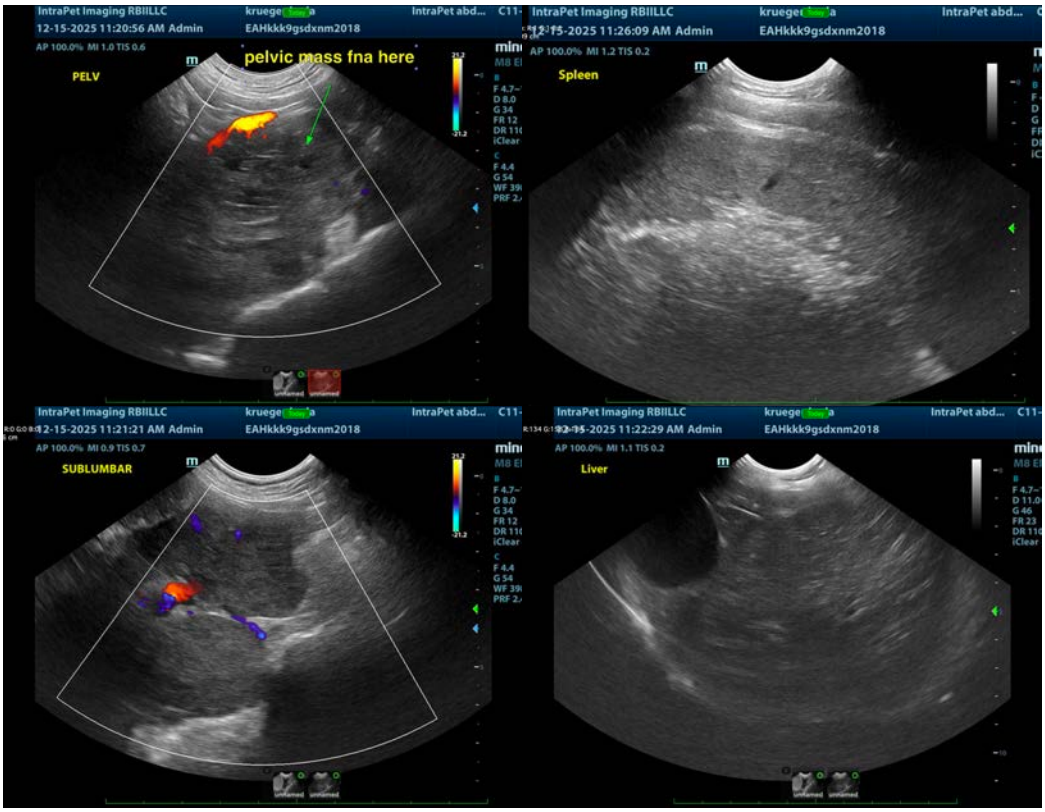

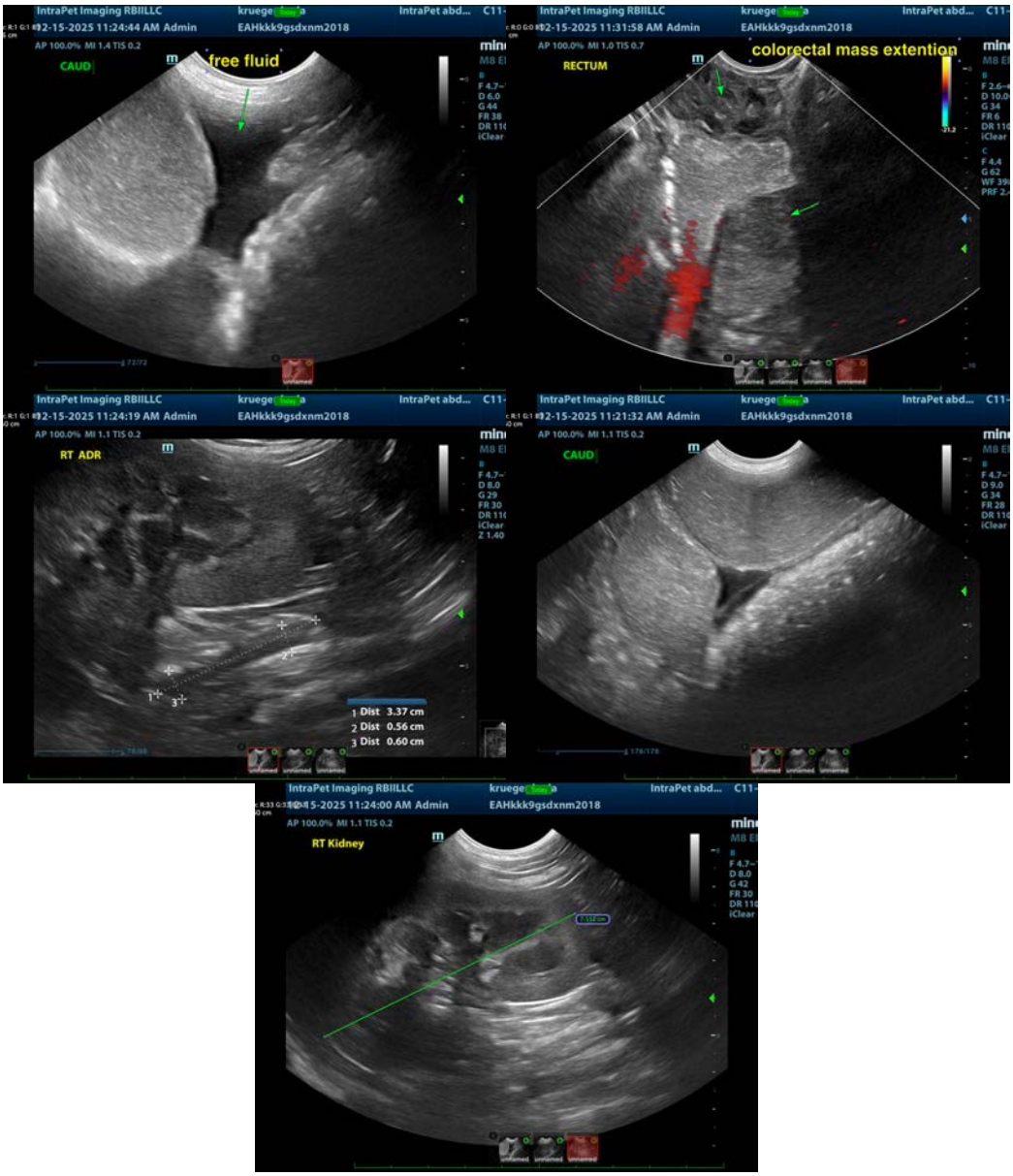

The information and recommendations provided are based on the images presented by the referring veterinarian/sonographer. No evaluation can be communicated regarding pathology that was not visible in the image/video clips provided.

Thank you for this referral. If the clinical or image interpretation does not parallel your findings or if I can be of any further assistance please contact me.

Eric Lindquist, DMV, DABVP(CFM), Cert. IVUSS,
CEO, Owner, Founder -- SonoPath.com
info@SonoPath.com