PATIENT
Joy Liceaga

SPECIES
Canine

BREED
Pembroke Welsh Corgi

SEX
Spayed Female

AGE
1 Year 5 Months

WEIGHT
29.6 Pounds

INTERPRETED BY
Eric Lindquist, DMV, DABVP (CFM), Cert. IVUSS

IMAGING PERFORMED BY
Dr. Gabriel Ferrer, DVM

HOSPITAL NAME
Pulse Pet Ultrasound

REFERRING VET
Dra. Maricarmen Vega

INVOICE
35917

DATE
12/15/25

PRESENTING CLINICAL SIGNS

History: Presented as a referral for an abdominal ultrasound to evaluate mild elevated liver enzymes and bile acids. Pt is doing well at home and not on any medication. Pt has elevated ALT and it was recommended bile acids and anomia levels. DDX microvascular dysplasia, PSS.

Abnormal PE/Chem/CBC/UA Results: Bloodwork and Bile acids attached as supporting documents.

ULTRASONOGRAPHIC EXAMINATION OF THE ABDOMEN

Urinary System

The **urinary bladder**, trigone, and pelvic urethra presented normal thicknesses and normal tone. The ureters were not visible which is normal. No uroliths or sediment were visualized and anechoic urine was present. No evidence of inflammatory or neoplastic changes was noted. Ureteral papillae were normal. The pelvic urethra was imaged 3.0 cm beyond the cystourethral junction.

The **kidneys** revealed normal size and structure, corticomedullary definition and ratio for this age. The cortices presented largely uniform texture with normal echogenic relationship to liver and spleen. Medullary structure differed distinctly from the cortex, and no evidence of pelvic dilation was present. The capsules were acceptably uniform without significant irregularities. The right kidney measured 5.4 cm. The left kidney measured 5.22 cm.

Adrenal Glands

Both **adrenal glands** were visualized and recognized as having normal shape, size, position and echogenicity for this breed. The phrenic vasculature, glandular echogenicity and detail were unremarkable. Capsule, cortex, and medullary definition were normal for this age patient. The right adrenal gland measured 1.8 cm x 0.36 cm at the cranial pole and 0.46 cm at the caudal pole. The left adrenal gland measured 0.32 cm at the cranial pole and 0.43 cm at the caudal pole.

Spleen

The **spleen** presented a smooth homogeneous parenchyma hyperechoic to liver and renal cortical parenchyma. The capsule was smooth without noticeable expansion or deviation from within the spleen or adjacent pathology. The splenic vasculature demonstrated normal volume without signs of congestion or thrombosis. No sonographic evidence of acute or chronic inflammatory, neoplastic, or infarctual changes were noted. The spleen was folded upon itself.

Liver

The **liver** was slightly subnormal in size. The gallbladder and common bile duct were unremarkable. The portal vein to vena cava ratio was 1:1. No evidence of portosystemic shunting. Intrahepatic vascular volume also appeared normal.

Gastrointestinal

Examination of the **gastrointestinal tract** revealed a stomach and intestine free of stasis, of normal wall thickness, acceptable curvilinear mural detail, and peristaltic activity. Small and large intestine demonstrated normal luminal chyme and stool consistency respectively. No obstructive or overt infiltrative disease was noted. No associated abnormal lymphatic activity was noted.

Pancreas

PATIENT

Joy Liceaga

SPECIES

Canine

BREED

Pembroke Welsh Corgi

SEX

Spayed Female

AGE

1 Year 5 Months

WEIGHT

29.6 Pounds

INTERPRETED BY

Eric Lindquist, DMV, DABVP (CFM), Cert. IVUSS

IMAGING PERFORMED BY

Dr. Gabriel Ferrer, DVM

HOSPITAL NAME

Pulse Pet Ultrasound

REFERRING VET

Dra. Maricarmen Vega

INVOICE

35917

DATE

12/15/25

The base and limbs of the **pancreas** were observed to be largely isoechoic to surrounding omental fat. Pancreatic duct and capsular contour were acceptably normal and parenchyma respected normal curvilinear patterns. No overt evidence of active inflammatory or neoplastic disease was noted.

ULTRASONOGRAPHIC FINDINGS

- Structurally normal abdomen with minor microhepatica, likely portal hypoplasia/microvascular dysplasia. No evidence of macroscopic shunting.
- Spleen folded upon itself

INTERPRETATION OF THE FINDINGS & FURTHER RECOMMENDATIONS

Core liver biopsy or surgical liver biopsy is indicated if bile acids remain elevated.

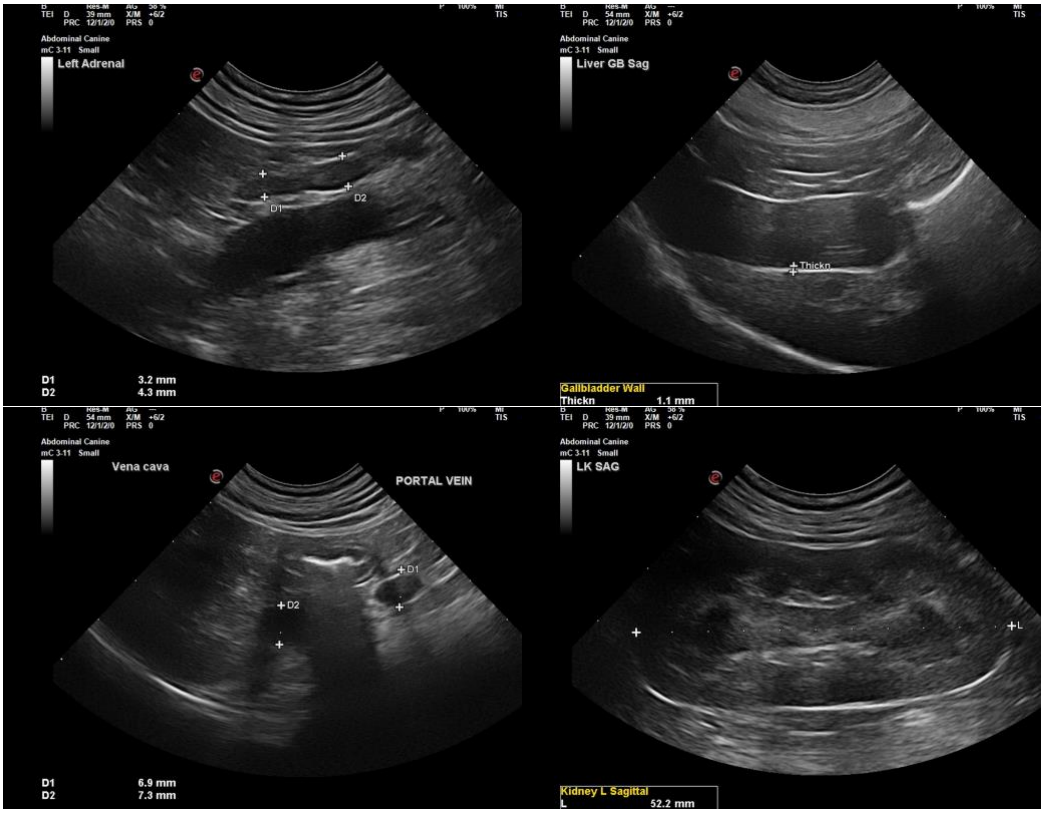

PATIENT

Joy Liceaga

SPECIES

Canine

BREED

Pembroke Welsh Corgi

SEX

Spayed Female

AGE

1 Year 5 Months

WEIGHT

29.6 Pounds

INTERPRETED BY

Eric Lindquist, DMV, DABVP (CFM), Cert. IVUSS

IMAGING PERFORMED BY

Dr. Gabriel Ferrer, DVM

HOSPITAL NAME

Pulse Pet Ultrasound

REFERRING VET

Dra. Maricarmen Vega

INVOICE

35917

DATE

12/15/25

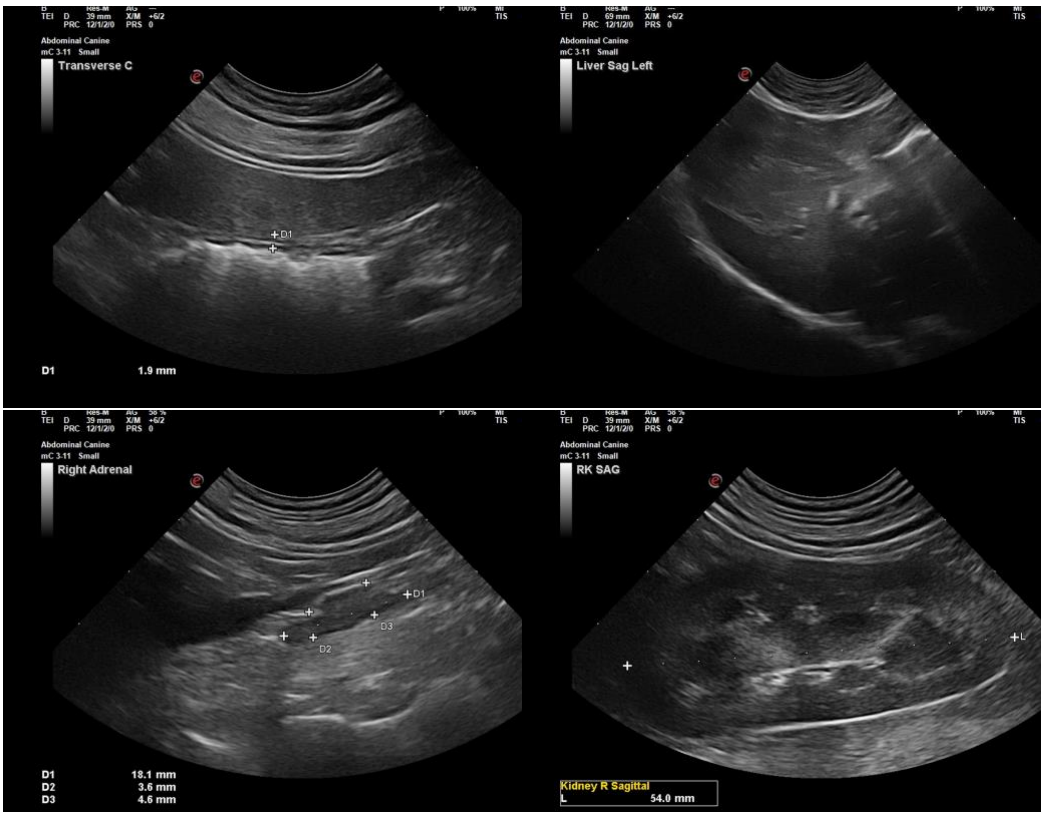

The information and recommendations provided are based on the images presented by the referring veterinarian/sonographer. No evaluation can be communicated regarding pathology that was not visible in the image/video clips provided.

Thank you for this referral. If the clinical or image interpretation does not parallel your findings or if I can be of any further assistance please contact me.

Eric Lindquist, DMV, DABVP(CFM), Cert. IVUSS,
CEO, Owner, Founder -- SonoPath.com
info@SonoPath.com