



PATIENT PRESENTING CLINICAL SIGNS

Millie Chamberlain Distended abdomen Reduced activity level, reduced/variable appetite Moist/rough inspiratory respiratory sounds Clients report a tracheal cough yesterday, better today History of radiographs and ultrasound in February 2019.

SPECIES Abnormal PE/Chem/CBC/UA Results: pending lab results. Will provide at procedure. Last urine culture was negative.

Canine

BREED

Pimobendan 5mg 1 in AM, 1/2 in PM, Enalapril 5mg 1/2 BID, Spironolactone 25mg 1/2 BID, Formula CV 1 BID, Urinary Tract Support 2 BID, Provable Forte 1 SID, Boswellia Complex, Phycos MAX. Added 12/14/21: 40mg Lasix, 1/2 tablet POq12h, increase to 1 tablet q12h in 4 days if breathing not improved.

Cavalier King Charles Spaniel

ULTRASONOGRAPHIC EXAMINATION OF THE HEART

SEX

Spayed Female

AGE

9 Years

WEIGHT

31.2 Pounds

INTERPRETED BY

Eric Lindquist, DMV, DABVP, Cert. IVUS

CANINE CARDIAC PARAMETERS	MR VMAX (m/s)	TR VMAX (m/s)	LA/AO (Boon method)	LA/AO (Heart Base; Swe)	FS (%)	EF (%)	EPSS (cm)
NORMAL PARAMETER	4.5-5.5	<2.7	1.3	<1.6	28-40	40-100	<0.6
PATIENT	5.2	2.6	1.8	2.2	64	02	0.22
CANINE CARDIAC PARAMETERS	HR (BPM)	AV VMAX (m/s)	PV MAX (m/s)	BODY WEIGHT (kg)	LA 2D short axis Base view (cm)	LVIDd Avg; 2D and m-mode short axis (cm)	LVIDs Avg; 2D and m-mode short axis (cm)
NORMAL PARAMETER	50-100	0.7-1.7	0.7-1.6				
PATIENT	182	1.3	0.9		5.9	3.5	

IMAGING PERFORMED BY

Jenna Walsh, CVT

HOSPITAL NAME

VCA McKenzie AH

REFERRING VET

Dr. Fricke

DATE

12/15/21

INVOICE

33436

Cardiac Presentation

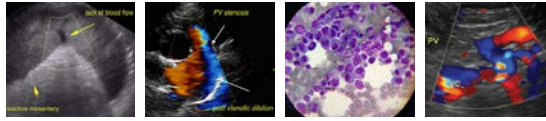
The cardiac presentation revealed severe left-sided enlargement in all three measurements with frequent arrhythmia. Trace pericardial effusion noted, likely secondary to volume overload. However, slight atrial tear cannot be completely ruled out. Severe mitral insufficiency noted. Contractility was subnormal for compensatory activity. Tricuspid insufficiency noted with mild right atrial enlargement. Minor pulmonic insufficiency noted. No masses present in the right auricle.

ULTRASONOGRAPHIC FINDINGS

- Left-sided congestive heart failure with trace pericardial effusion

INTERPRETATION OF THE FINDINGS & FURTHER RECOMMENDATIONS

Given the current quadrotherapy in this patient, prognosis is extremely poor. I'm strongly concerned for pericardial effusion being owing to left atrial tear. Recommend increasing Lasix to 3-4 mg/kg BID, increasing Pimobendan to TID dosing at 0.3 mg/kg. However, this patient is at end stage cardiac disease. Prognosis is poor. Do not expect any significant response, as the ability to medicate this patient has diminished with available medications/ Sildenafil could be attempted at 1mg/kg BID as well.



PATIENT

Millie Chamberlain

SPECIES

Canine

BREED

Cavalier King Charles
Spaniel

SEX

Spayed Female

AGE

9 Years

WEIGHT

31.2 Pounds

INTERPRETED BY

Eric Lindquist, DMV,
DABVP, Cert. IVUS

IMAGING PERFORMED BY

Jenna Walsh, CVT

HOSPITAL NAME

VCA Mckenzie AH

REFERRING VET

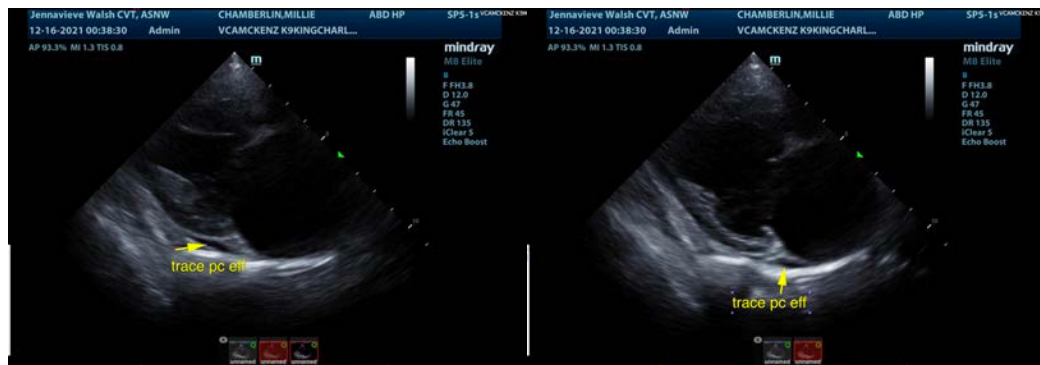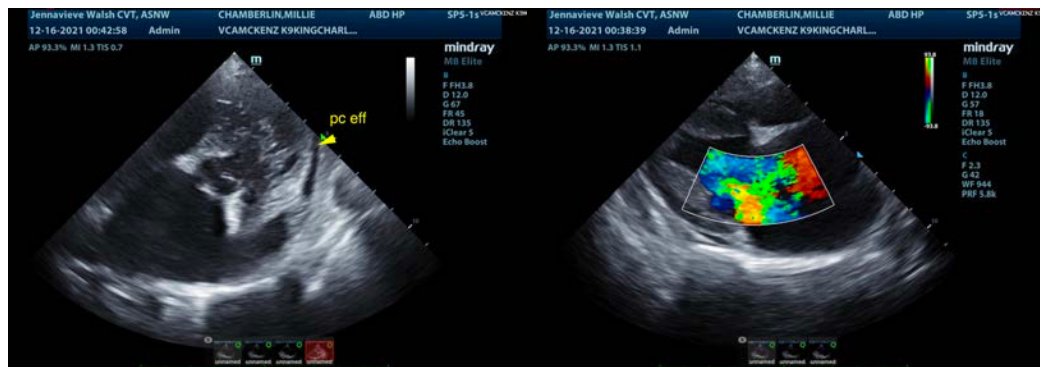
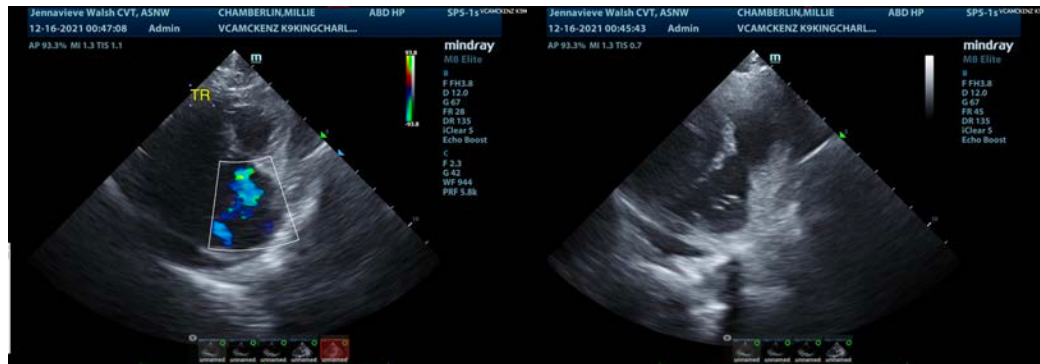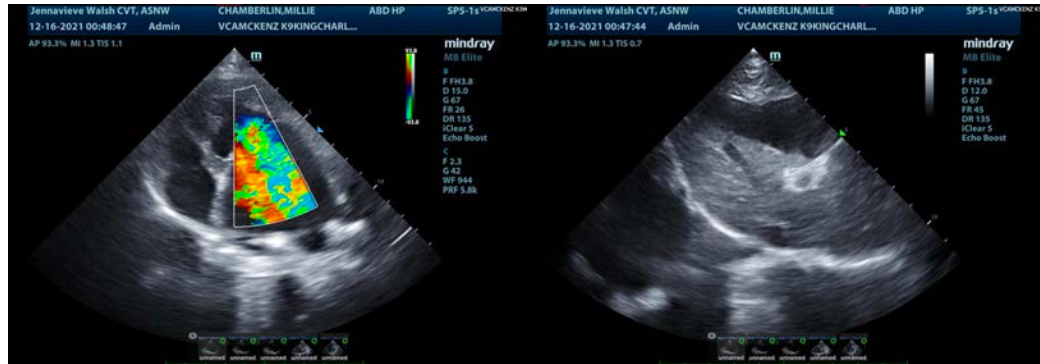Dr. Fricke

DATE

12/15/21

INVOICE

33436





PATIENT

Millie Chamberlain

SPECIES

Canine

BREED

Cavalier King Charles Spaniel

SEX

Spayed Female

AGE

9 Years

WEIGHT

31.2 Pounds

INTERPRETED BY

Eric Lindquist, DMV,
 DABVP, Cert. IVUS

IMAGING PERFORMED BY

Jenna Walsh, CVT

HOSPITAL NAME

VCA Mckenzie AH

REFERRING VET

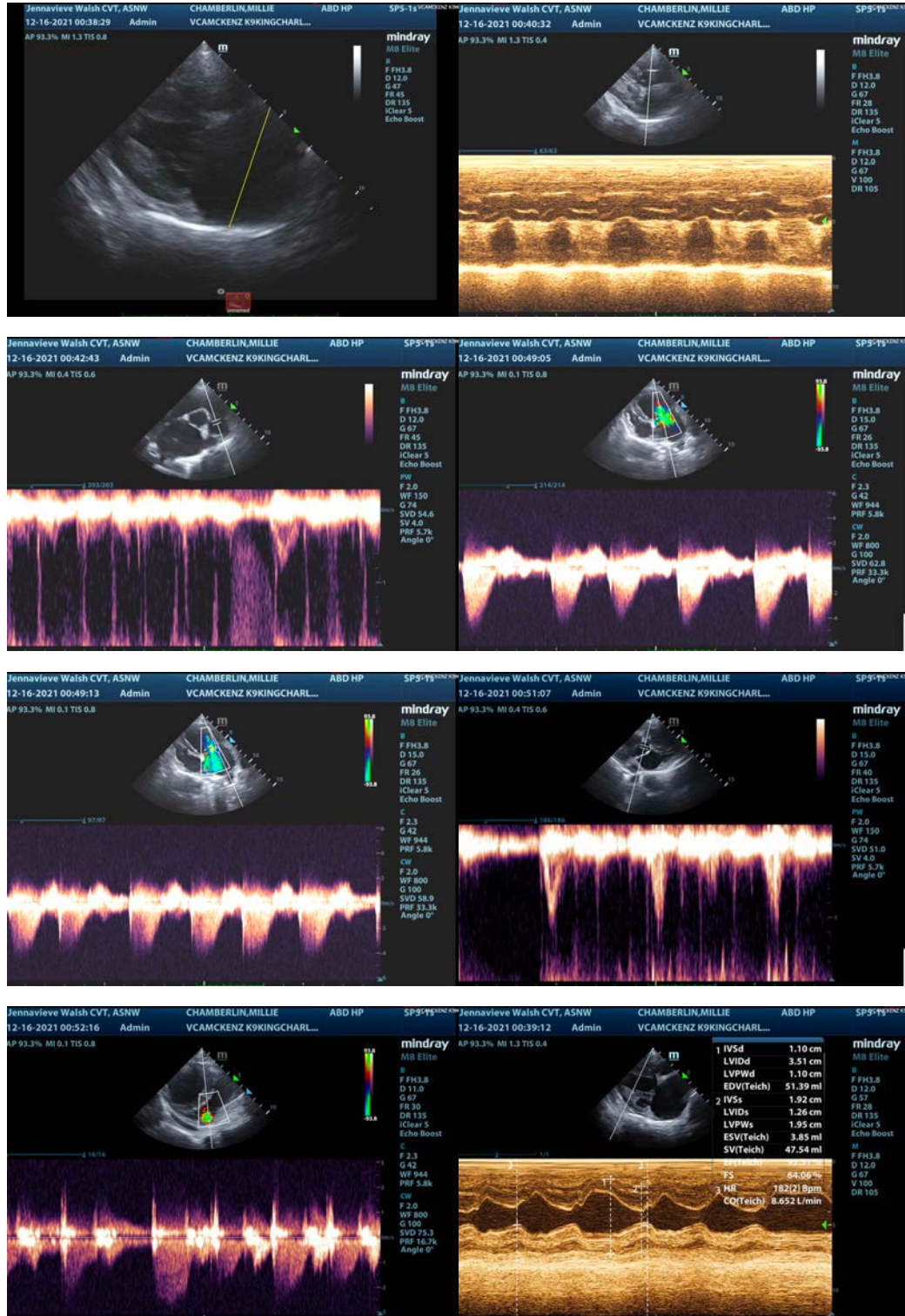
Dr. Fricke

DATE

12/15/21

INVOICE

33436





PATIENT

Millie Chamberlain

SPECIES

Canine

BREED

Cavalier King Charles Spaniel

SEX

Spayed Female

AGE

9 Years

WEIGHT

31.2 Pounds

INTERPRETED BY

Eric Lindquist, DMV, DABVP, Cert. IVUSS

IMAGING PERFORMED BY

Jenna Walsh, CVT

HOSPITAL NAME

VCA Mckenzie AH

REFERRING VET

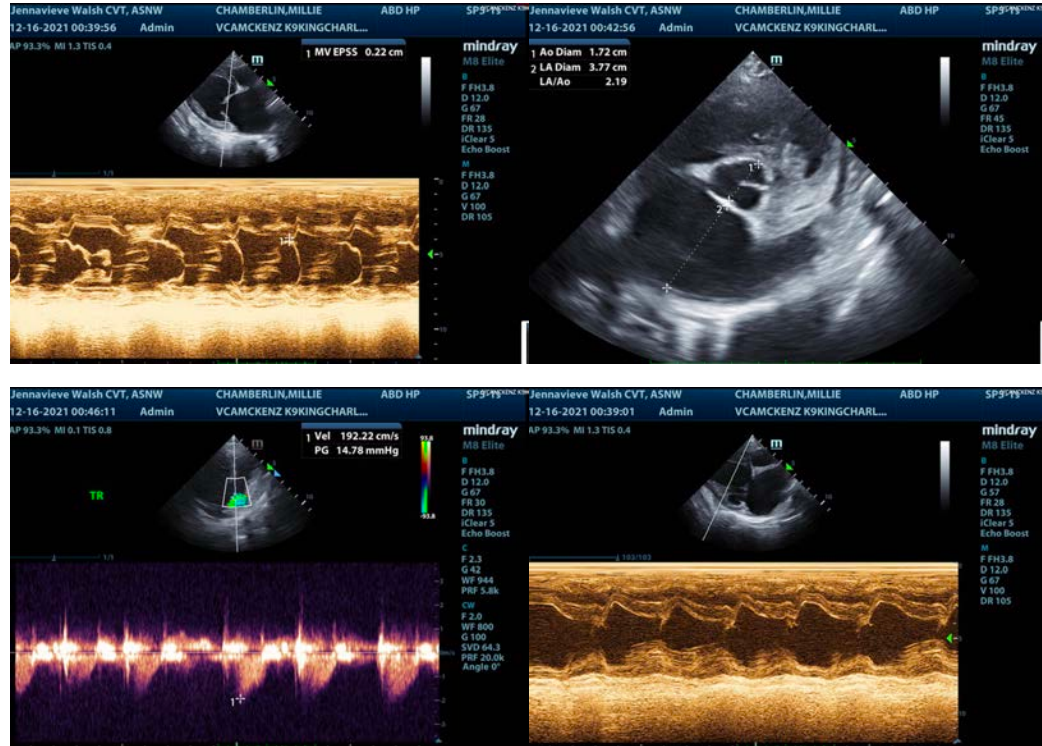
Dr. Fricke

DATE

12/15/21

INVOICE

33436



The information and recommendations provided are based on the images presented by the referring veterinarian. No evaluation can be communicated regarding pathology that was not visible in the image/video clips provided.

Thank you for this referral. If the clinical or image interpretation does not parallel your findings or if I can be of any further assistance please contact me.

Eric Lindquist, DMV, DABVP, Cert. IVUSS

CEO of Sonopath.com

Eric.Lindquist@SonoPath.com