



PATIENT PRESENTING CLINICAL SIGNS

Luci Detrick Increased respiratory rate and effort, panting when stressed

SPECIES ULTRASONOGRAPHIC EXAMINATION OF THE HEART

Feline

BREED

Persian

SEX

Intact Female

AGE

4 Years

WEIGHT

8.62 Pounds

INTERPRETED BY

Eric Lindquist, DMV,
DABVP, Cert. IVUSS

IMAGING PERFORMED BY

Jenna Walsh, CVT

HOSPITAL NAME

Santa Clara AH

REFERRING VET

Dr. Zulauf

DATE

12/15/21

INVOICE

33440

FELINE CARDIAC PARAMETERS	BODY WEIGHT (kg)	HR (BPM)	IVSd (cm)	LVIDd (cm)	LVWd (cm)	FS (%)	EF (%)
NORMAL PARAMETER	-----	150-240	0.3-0.6	1.0-2.1	0.25-0.6	35-67	80-100
PATIENT		233	0.71	1.08	0.71	76	98
FELINE CARDIAC PARAMETERS	LA/AO (Boon)	LA/AO HEART BASE (Sisson)	LA 2D 4-chamber long axis AS to FW (Sisson) (cm)	LVOT VEL. (m/s)	RVOT VEL. (m/s)	IVRT (m/)	
NORMAL PARAMETER	<1.5	0.88-1.79	0.7-1.7	<1.6	<1.3	40-60	
PATIENT	1.5	2.0	1.77	3.5	0.68	NM	
Adapted from June Boon, Veterinary Echocardiography, 1998 Sisson D et al. JVIM 1991; 5: 232, Jacobs et al. Am J Vet Res 1985; 46:1705							

Cardiac Presentation

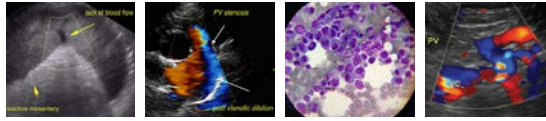
The cardiac presentation revealed mildly enlarged right and left atria with concentric left ventricular hypertrophy. Right atrial to left atrial ratio was 1:1. Systolic anterior motion of the mitral valve noted, consistent with dynamic obstruction. Mitral insufficiency noted at 5.5 m/sec. Tachycardia present. Mild pericardial effusion noted. B-lines noted in the peripheral lung fields.

ULTRASONOGRAPHIC FINDINGS

- Hypertrophic cardiomyopathy (moderate to severe) with right and left atrial enlargement
- Mild pericardial effusion owing to left-sided heart failure

INTERPRETATION OF THE FINDINGS & FURTHER RECOMMENDATIONS

Recommend Lasix at 12.5 mg BID x3 doses, then 12.5 mg SID, ACE inhibitor 0.5 mg/kg SID. Plavix therapy also warranted. Recheck echo in one week. I do not recommend Atenolol therapy in this patient owing to current early heart failure. However, it may be necessary later. EKG and blood pressures indicated.



PATIENT

Luci Detrick

SPECIES

Feline

BREED

Persian

SEX

Intact Female

AGE

4 Years

WEIGHT

8.62 Pounds

INTERPRETED BY

Eric Lindquist, DMV,
DABVP, Cert. IVUS

IMAGING PERFORMED BY

Jenna Walsh, CVT

HOSPITAL NAME

Santa Clara AH

REFERRING VET

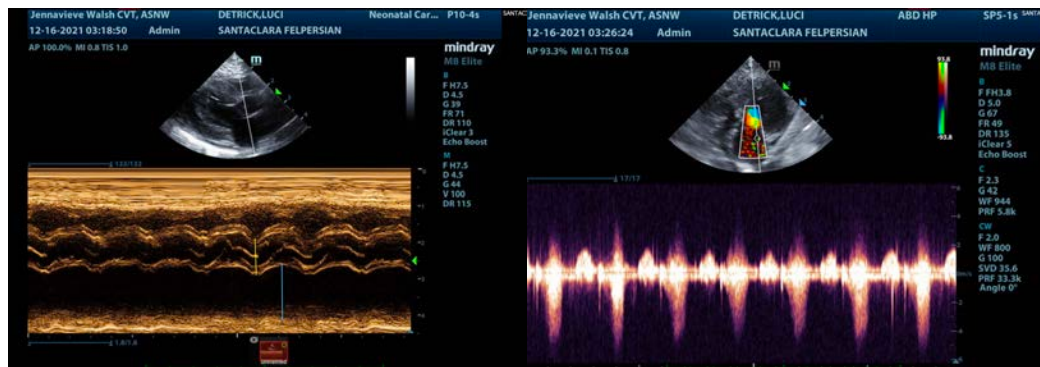
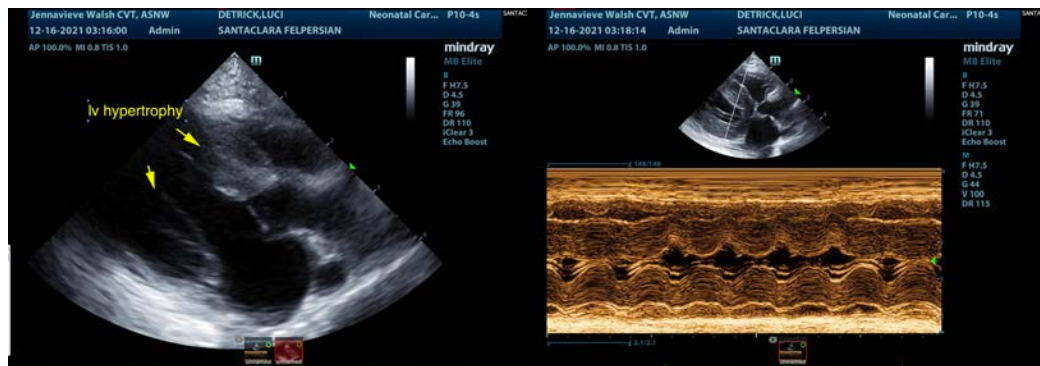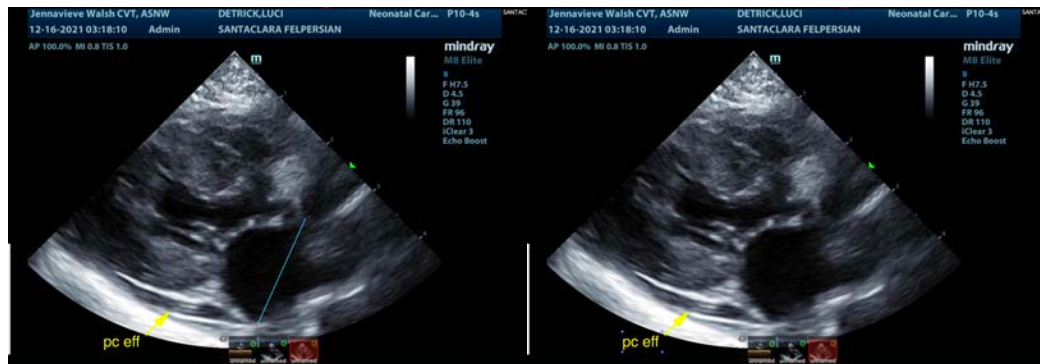
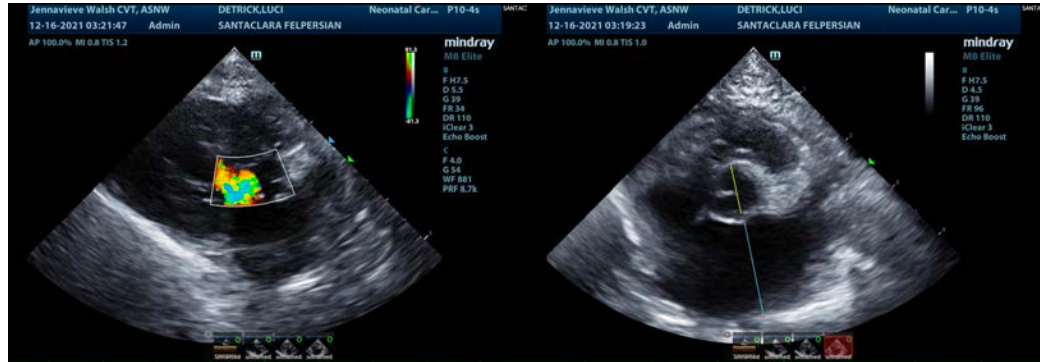
Dr. Zulauf

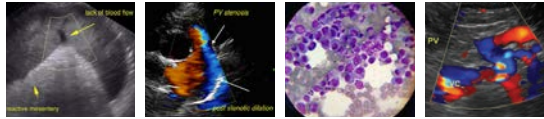
DATE

12/15/21

INVOICE

33440





PATIENT

Luci Detrick

SPECIES

Feline

BREED

Persian

SEX

Intact Female

AGE

4 Years

WEIGHT

8.62 Pounds

INTERPRETED BY

Eric Lindquist, DMV,
DABVP, Cert. IVUSS

IMAGING PERFORMED BY

Jenna Walsh, CVT

HOSPITAL NAME

Santa Clara AH

REFERRING VET

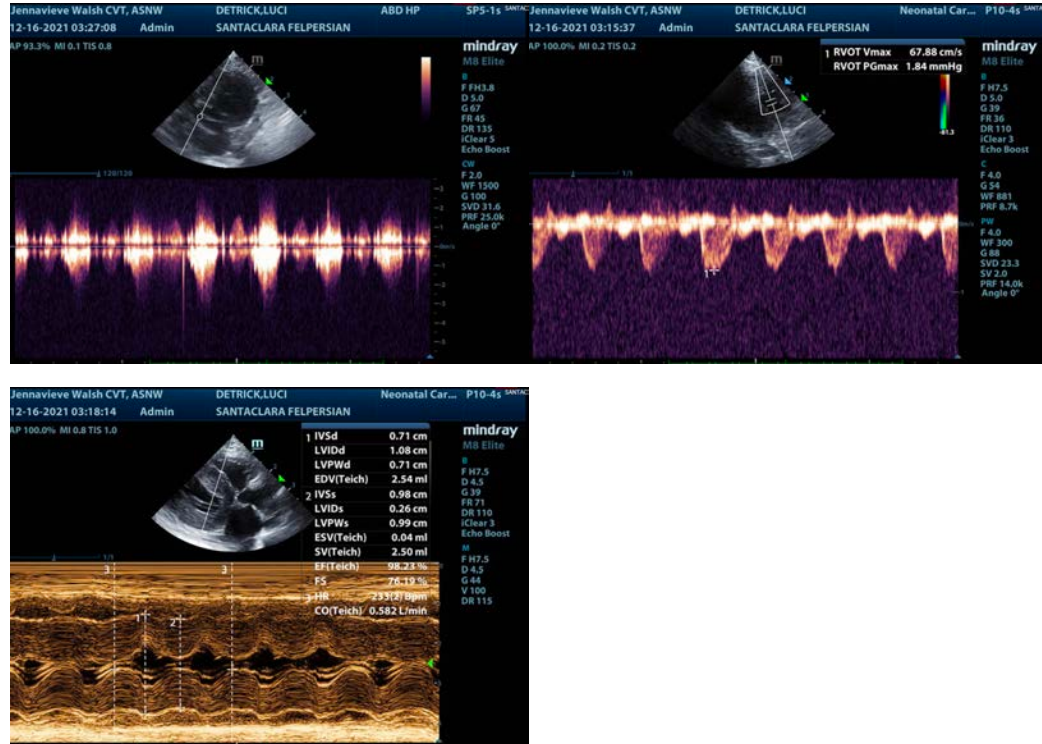
Dr. Zulauf

DATE

12/15/21

INVOICE

33440



The information and recommendations provided are based on the images presented by the referring veterinarian. No evaluation can be communicated regarding pathology that was not visible in the image/video clips provided.

Thank you for this referral. If the clinical or image interpretation does not parallel your findings or if I can be of any further assistance please contact me.

Eric Lindquist, DMV, DABVP, Cert. IVUSS

CEO of Sonopath.com

Eric.Lindquist@SonoPath.com