

**DATE PRESENTING CLINICAL SIGNS**

12/15/21 History: lethargy, hx of renal dz.
 Current Medications: Gabapentin 600mg 0.25 tablet PO bid, Galliprant 60mg 0.5 tablet PO sid,
PATIENT Methocarbamol 500mg 0.5 tablet PO BID.
 Joe Simms Date of Previous IntraPet Ultrasound: No previous IntraPet scans.
 Sedation: Not required for a full diagnostic ultrasound.
 Stat Report: Not requested.

SPECIES ULTRASONOGRAPHIC EXAMINATION OF THE ABDOMEN

Canine

Urinary System**BREED**

Chinese Pug

The **urinary bladder**, trigone, and pelvic urethra presented normal thicknesses and normal tone. The ureters were not visible which is normal. No uroliths or sediment were visualized and anechoic urine was present. No evidence of inflammatory or neoplastic changes were noted. Ureteral papillae were normal. The residual prostate measured 1.15 cm, slightly heterogeneous yet uniform contour.

SEX

Neutered Male

The **kidneys** presented moderate degenerative changes, loss of corticomedullary definition, and pelvic mineralization. The right kidney measured 4.78 cm. The left kidney measured 5.77 cm with corticomedullary mineralization noted and echogenic cortical changes. Blood flow to the kidneys appeared to be adequate on color flow assessment. Occasional degenerative cortical cysts noted in both renal cortices.

AGE

2/16/11

Adrenal Glands**WEIGHT**

30.5 Pounds

Both **adrenal glands** were visualized and recognized as having normal shape, size, position and echogenicity for this breed. The phrenic vasculature, glandular echogenicity and detail were unremarkable. Capsule, cortex, and medullary definition were normal for this age patient. The right adrenal gland measured 1.74 cm x 0.26 cm at the caudal pole and 0.56 cm at the cranial pole. The left adrenal gland measured 2.3 cm x 0.55 cm at the caudal pole and 0.50 cm at the cranial pole.

INTERPRETED BYEric Lindquist, DMV
DABVP, Cert. IVUSS**Spleen****IMAGING PERFORMED BY**Stephanie Pearce
RDCS, RVT

The **spleen** presented a smooth homogeneous parenchyma hyperechoic to liver and renal cortical parenchyma. The capsule was smooth without noticeable expansion or deviation from within the spleen or adjacent pathology. The splenic vasculature demonstrated normal volume without signs of congestion or thrombosis. No sonographic evidence of acute or chronic inflammatory, neoplastic, or infarctual changes were noted.

HOSPITAL NAME

Claws N Paws AH

Liver**REFERRING VET**

Dr. Singh

The **liver** images submitted revealed subjectively normal liver size, contour, and structure. Parenchymal echogenicity was naturally coarse and hypoechoic to the spleen. Vascular and biliary tracts were of normal volume with no evidence of congestion. The gallbladder presented acceptably thin walls with primarily anechoic content. The cystic and common bile ducts were normal. No pathological hepatic lymphadenopathy was evident. No overt structural evidence of inflammatory, infiltrative or regenerative pathology was evident.

INVOICE

33481

Gastrointestinal

Some retention of ingesta noted in the **stomach**. The small intestine and colon were unremarkable.

Pancreas

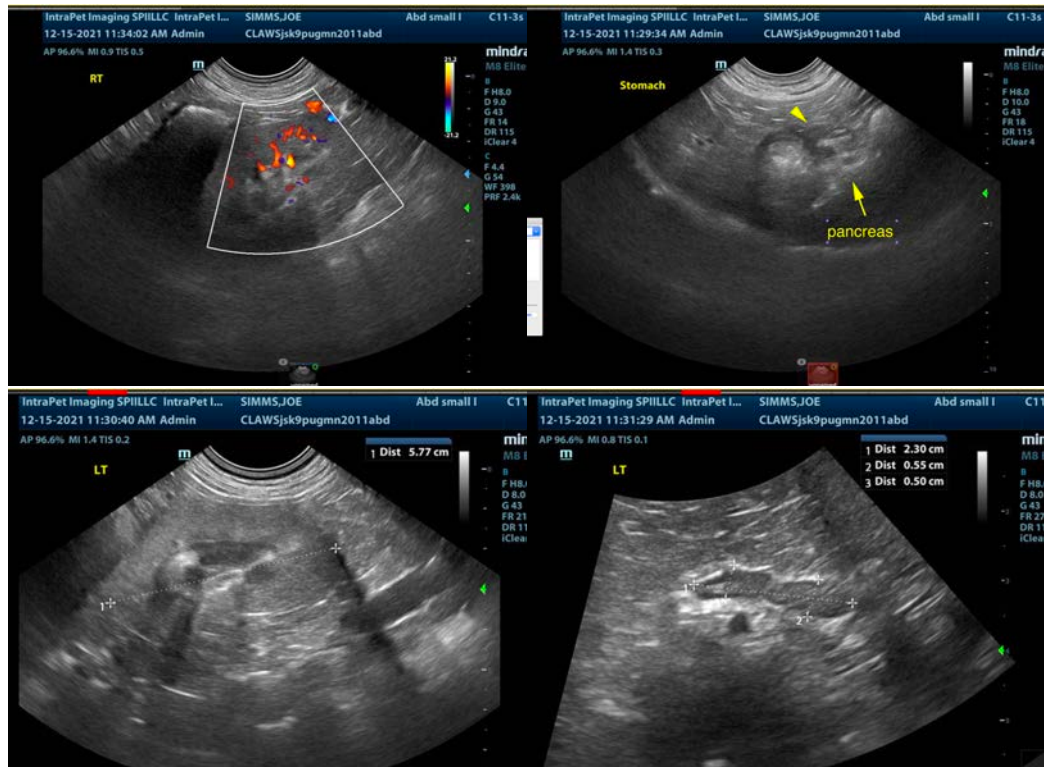
The **pancreas** was mildly heterogeneous with coarse architecture. Subxiphoid palpation is recommended to assess for pain or discomfort associated with the pancreas.

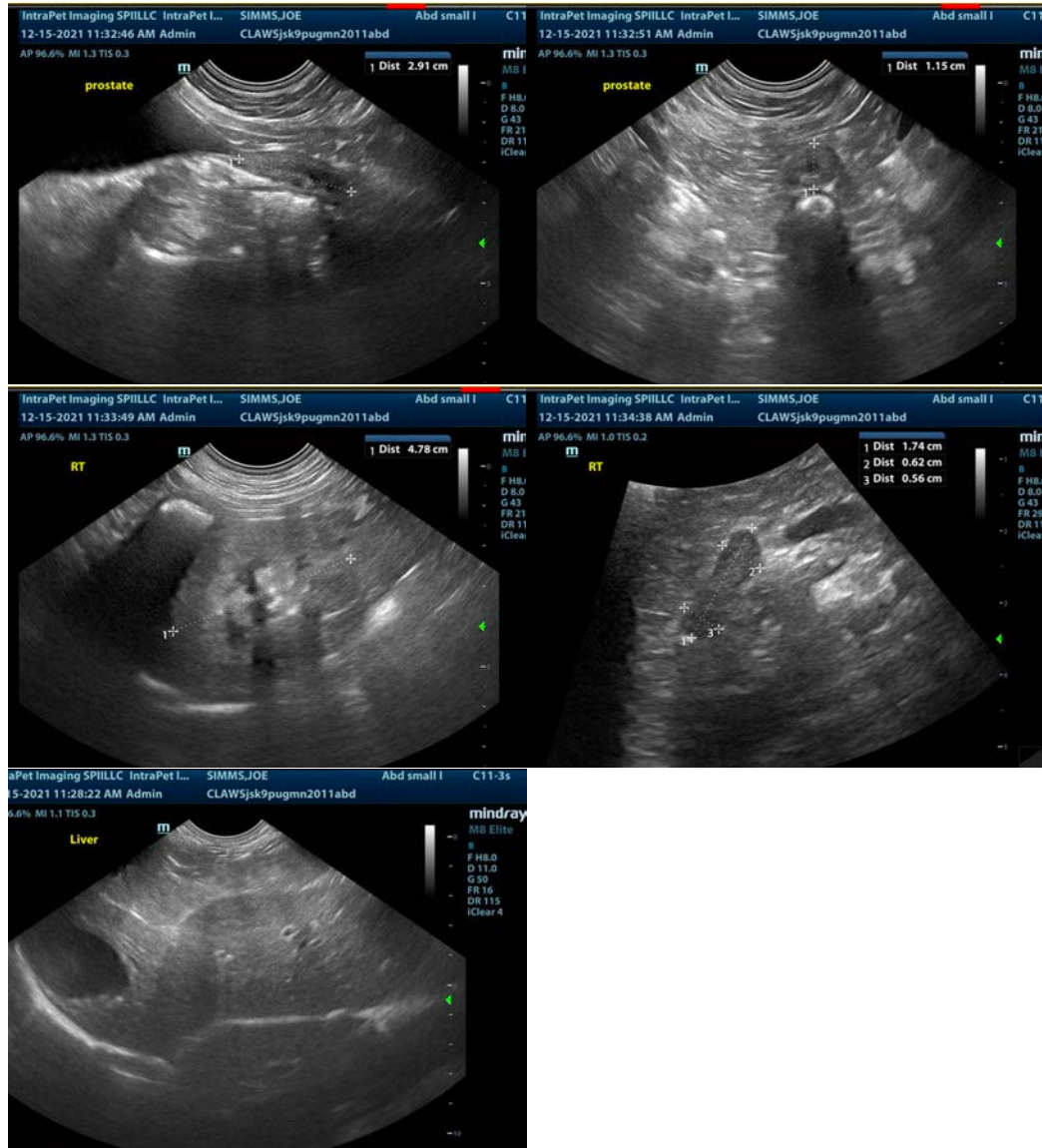
ULTRASONOGRAPHIC FINDINGS

- Moderate non-specific degenerative renal changes with interstitial nephrosis pattern and areas of mineralization in the right kidney.
- Suspect low-grade pancreatitis versus sequelae from prior episodes of pancreatitis

INTERPRETATION OF THE FINDINGS & FURTHER RECOMMENDATIONS

The cause of lethargy is not overtly clear. Some retention of ingesta noted in the stomach despite NPO status. Delayed outflow may be an issue. If renal values are contained in this patient and blood pressures are not excessively elevated, then other causes of lethargy such as orthopedic, CNS or thoracic disease should be considered.





The information and recommendations provided are based on the images presented by the referring veterinarian. No evaluation can be communicated regarding pathology that was not visible in the image/video clips provided.

Thank you for this referral. If the clinical or image interpretation does not parallel your findings or if I can be of any further assistance please contact me.

Eric Lindquist, DMV, DABVP, Cert. IVUSS, CEO of SonoPath.com
info@SonoPath.com