

**PATIENT**

Digger LaDuke

**SPECIES**

Canine

**BREED**

Dachshund

**SEX**

Spayed Female

**AGE**

15 years

**WEIGHT**

11 lbs

**INTERPRETED BY**

Eric Lindquist, DMV  
DABVP, Cert. IVUSS

**IMAGING PERFORMED BY**

Dr. Ammeraal

**HOSPITAL NAME**

Sova AH

**REFERRING VET**

Dr. Ammeraal

**INVOICE**

94644

**DATE**

12/15/21

**PRESENTING CLINICAL SIGNS**

History: Has been having accidents in the house was asking to go out every 2 hours. Past couple days improving. R/O Urinary Calculi, Neoplasia  
Abnormal PE/Chem/CBC/UA Results: USG: 1.022, WBC 2-3 HPF ( free catch).

**ULTRASONOGRAPHIC EXAMINATION OF THE ABDOMEN**

**Urinary System**

The **urinary bladder**, trigone, and pelvic urethra presented normal thicknesses and normal tone. The ureters were not visible which is normal. No uroliths or sediment were visualized and anechoic urine was present. No evidence of inflammatory or neoplastic changes was noted. Ureteral papillae were normal.

The residual prostate measured 0.4 cm.

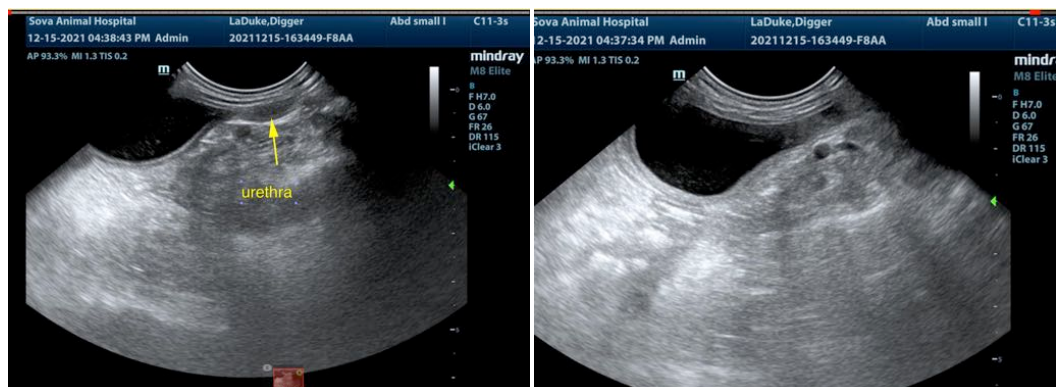
The **kidneys** revealed normal size and structure, corticomedullary definition and ratio for this age. The cortices presented largely uniform texture with normal echogenic relationship to liver and spleen. Medullary structure differed distinctly from the cortex and no evidence of pelvic dilation was present. The capsules were acceptably uniform without significant irregularities. The left kidney measured 4.0 cm. The right kidney measured 4.0 cm.

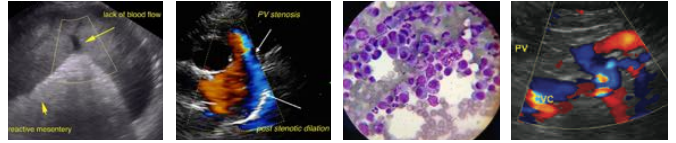
**ULTRASONOGRAPHIC FINDINGS**

Structurally unremarkable urinary tract.

**INTERPRETATION OF THE FINDINGS & FURTHER RECOMMENDATIONS**

There was no overt cause of clinical signs. Coverage for occult urinary tract infection with washout effect and treatment for primary urinary incontinence can be considered. However, subjectively the urethral tone appeared unremarkable. Examination of the vaginal vestibule for concurrent pathology is recommended.





**PATIENT**

Digger LaDuke

**SPECIES**

Canine

**BREED**

Dachshund

**SEX**

Spayed Female

**AGE**

15 years

**WEIGHT**

11 lbs

**INTERPRETED BY**

Eric Lindquist, DMV  
DABVP, Cert. IVUSS

**IMAGING PERFORMED BY**

Dr. Ammeraal

**HOSPITAL NAME**

Sova AH

**REFERRING VET**

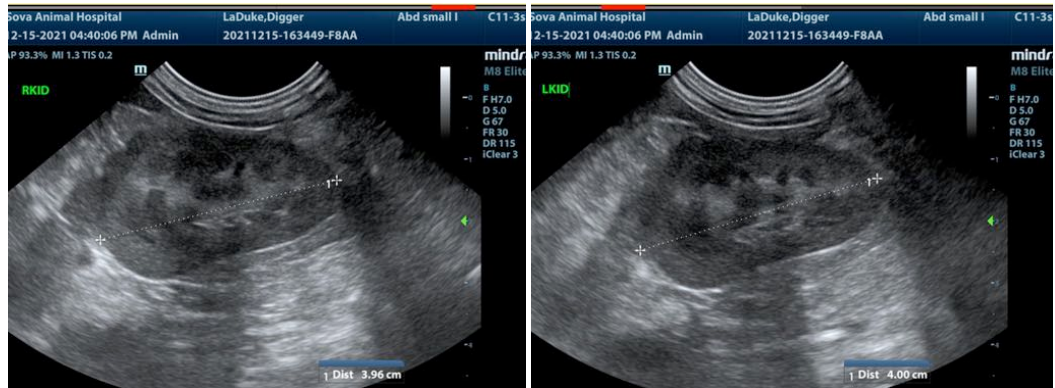
Dr. Ammeraal

**INVOICE**

94644

**DATE**

12/15/21



The information and recommendations provided are based on the images presented by the referring veterinarian. No evaluation can be communicated regarding pathology that was not visible in the image/video clips provided.

Thank you for this referral. If the clinical or image interpretation does not parallel your findings or if I can be of any further assistance please contact me.

**Eric Lindquist, DMV, DABVP, Cert. IVUSS, CEO of SonoPath.com**  
info@SonoPath.com