

PATIENT

PRESENTING CLINICAL SIGNS

Bella Bruton

History: Pet presents for history of bleeding from vulva, CBC - Leukocytosis 21.67k, Neutrophilia 16.57k, Elevated PLT 738k, Chem17 - results wnl, BUN 5, CREA 1.0, Lytes - wnl PT - wnl 15 s PTT - mildly prolonged 126.0 s UA - USG 1.010, pH 7.0, WBC < 1/hpf, RBC 4/hpf

SPECIES

Canine

ULTRASONOGRAPHIC EXAMINATION OF THE ABDOMEN

BREED

Corgi Mix

Urinary System

The **urinary bladder**, trigone, and pelvic urethra presented normal thicknesses and normal tone. The ureters were not visible which is normal. No uroliths or sediment were visualized and anechoic urine was present. No evidence of inflammatory or neoplastic changes was noted. Ureteral papillae were normal.

SEX

Spayed Female

The uterus was thickened in this patient with minor fluid filled lumen. The uterus measured 1.5 cm. The ovaries were not imaged; however, ovarian remnant is suspected in this patient given the uterine dilation and history of being a spayed female. The uterus extended throughout the length of the urinary bladder. Some cystic component of the uterine body was also noted.

AGE

13 years

The **kidneys** revealed normal size and structure, corticomedullary definition and ratio for this age. The cortices presented largely uniform texture with normal echogenic relationship to liver and spleen. Medullary structure differed distinctly from the cortex and no evidence of pelvic dilation was present. The capsules were acceptably uniform without significant irregularities. The left kidney measured 4.0 cm.

WEIGHT

15.2 kg

INTERPRETED BY

ULTRASONOGRAPHIC FINDINGS

Eric Lindquist, DMV
DABVP, Cert. IVUSS

Structurally unremarkable urinary tract.

Open pyometra or active heat cycle.

IMAGING PERFORMED BY

INTERPRETATION OF THE FINDINGS & FURTHER RECOMMENDATIONS

Dr. Peterson

Exploratory surgery is indicated and/or imaging of the ovarian fossa to assess for ovarian remnant.

HOSPITAL NAME

Wilvet Salem

REFERRING VET

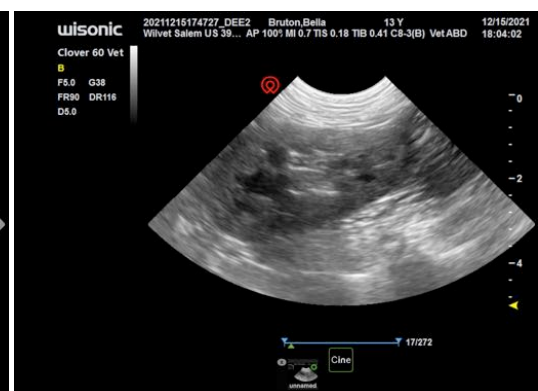
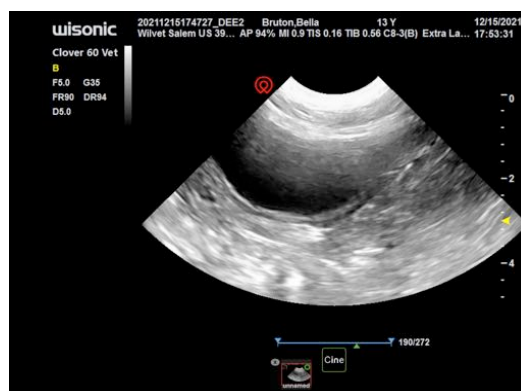Dr. Lewer

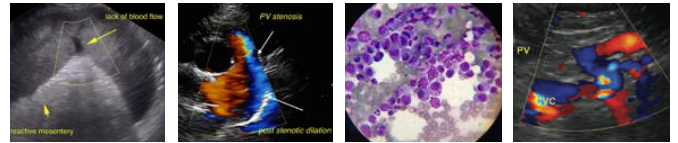
INVOICE

94631

DATE

12/15/21





PATIENT

Bella Bruton

SPECIES

Canine

BREED

Corgi Mix

SEX

Spayed Female

AGE

13 years

WEIGHT

15.2 kg

INTERPRETED BY

Eric Lindquist, DMV
DABVP, Cert. IVUSS

IMAGING PERFORMED BY

Dr. Peterson

HOSPITAL NAME

Wilvet Salem

REFERRING VET

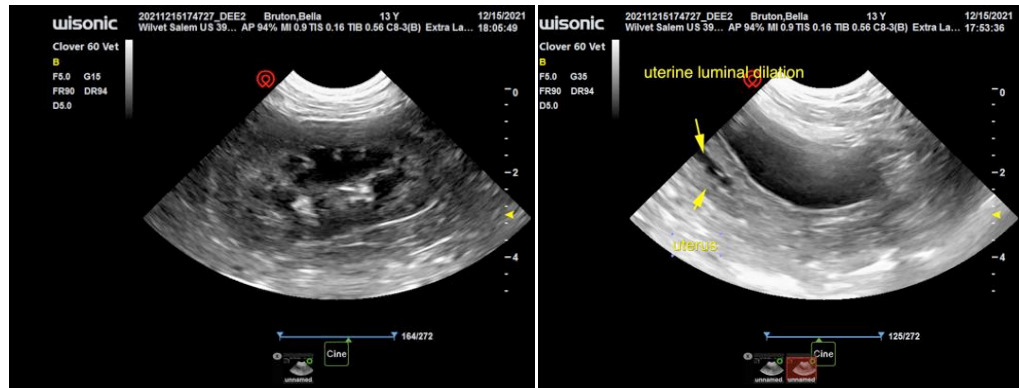
Dr. Lewer

INVOICE

94631

DATE

12/15/21



The information and recommendations provided are based on the images presented by the referring veterinarian. No evaluation can be communicated regarding pathology that was not visible in the image/video clips provided.

Thank you for this referral. If the clinical or image interpretation does not parallel your findings or if I can be of any further assistance please contact me.

Eric Lindquist, DMV, DABVP, Cert. IVUSS, CEO of SonoPath.com
info@SonoPath.com