



## PATIENT

Storm Billings

## SPECIES

Canine

## BREED

Siberian Husky

## SEX

Spayed Female

## AGE

8 Years 5 Months

## WEIGHT

63 lbs

## INTERPRETED BY

Eric Lindquist, DMV,  
DABVP (CFM), Cert.  
IVUSS

## IMAGING PERFORMED BY

Eugene Rivers, DVM

## HOSPITAL NAME

Pain Management for  
Pets

## REFERRING VET

Eugene Rivers, DVM

## INVOICE

72565

## DATE

12/14/25

## PRESENTING CLINICAL SIGNS

This dog was in for a routine annual physical exam and vaccinations. This patient popped positive on a new Idexx Lymphoma Screening test that Idexx is developing. Overweight (BCS of 7/9). Eos 4,792 on CBC, Alk Phos 228 (5-60). Urine USG 1.012. Mild PU/PD per owner. Pro BNP 1257 (0-900). Mild DJD history. Dog very vocal for exam. The technician underused torbugesic--gave 0.7ml iv, my dose recommended was 0.89ml of torbugesic. Patient was very vocal for the US exam. Would scream when the gel was applied and any probe was applied. I suspect the torbugesic injection was not a clean iv administration but the technician said it was. I was unable to "own the near field" because any pressure caused the pet to vocalize and move making any scan attempts impossible. Only 1 person was available to hold this patient for the scan. I was unable to get several of the 17 abdominal areas but am submitting what I did get for you evaluation. I forgot to get the "bears ion the forest" scan because the patient was so unruly by that time. Couldn't get Rt. kidney or either adrenal.

## ULTRASONOGRAPHIC EXAMINATION OF THE ABDOMEN

### Urinary System

The **urinary bladder** presented normal thicknesses and normal tone. The ureters were not visible which is normal. No uroliths or sediment were visualized and anechoic urine was present. No evidence of inflammatory or neoplastic changes were noted. The urethra was not visualized.

The **left kidney** presented a slight cortical infarct yet was structurally unremarkable otherwise.

The **right kidney** was not visualized.

### Adrenal Glands

The **adrenal glands** were not visualized.

### Spleen

The **spleen** appeared uniform, no evident pathology. Minimal views obtained.

### Liver

Minimal **liver** was noted. Approximately 2-3 cm of liver was noted and found to be unremarkable. The remainder of the images were abdominal fat.

### Gastrointestinal

The visible **gastrointestinal tract** was unremarkable with normal curvilinear patterns.

### Pancreas

The visible **pancreas** appeared unremarkable.

### Free Abdomen

Large amount of abdominal fat noted. Abdominal lipomas noted.

## ULTRASONOGRAPHIC FINDINGS

- Slight cortical infarct left kidney.
- Large amount of abdominal fat.



## PATIENT

Storm Billings

## SPECIES

Canine

## BREED

Siberian Husky

## SEX

Spayed Female

## AGE

8 Years 5 Months

## WEIGHT

63 lbs

## INTERPRETED BY

Eric Lindquist, DMV,  
DABVP (CFM), Cert.  
IVUSS

## IMAGING PERFORMED BY

Eugene Rivers, DVM

## HOSPITAL NAME

Pain Management for  
Pets

## REFERRING VET

Eugene Rivers, DVM

## INVOICE

72565

## DATE

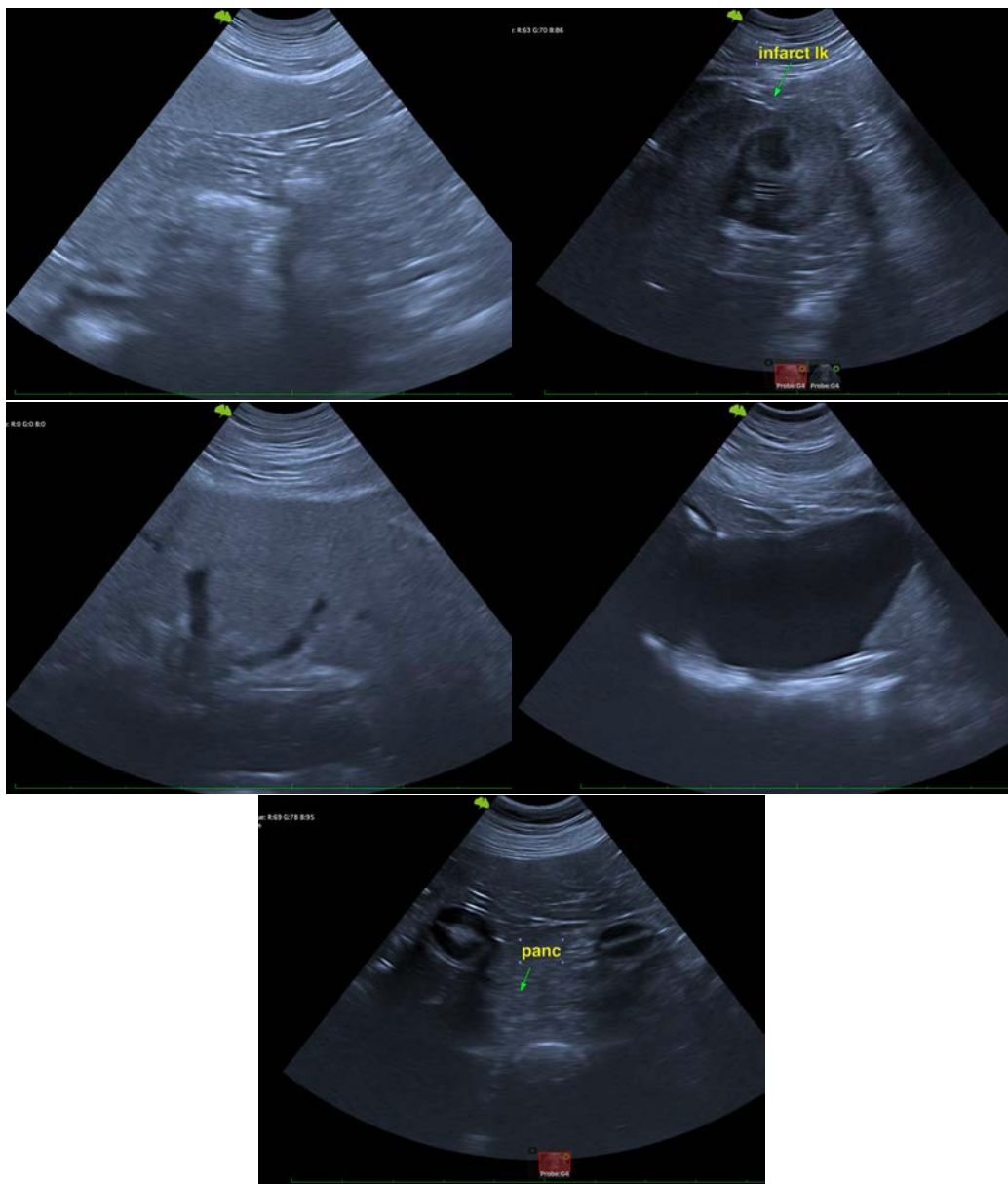
12/14/25

- Abdominal lipomas.

## INTERPRETATION OF THE FINDINGS & FURTHER RECOMMENDATIONS

**\*\*Poor acoustic penetration and lack of contrast resolution was present throughout the image set in this patient. The findings are very limited. Reevaluation of the ultrasound machine utilized for this size patient warranted. There were no diagnostic hepatic, right kidney, right adrenal, or left adrenal images.**

No gross evidence of neoplasia or pathology in the image set provided, yet the abdominal scan is incomplete.





## PATIENT

Storm Billings

## SPECIES

Canine

## BREED

Siberian Husky

## SEX

Spayed Female

## AGE

8 Years 5 Months

## WEIGHT

63 lbs

## INTERPRETED BY

Eric Lindquist, DMV,  
DABVP (CFM), Cert.  
IVUSS

## IMAGING PERFORMED BY

Eugene Rivers, DVM

## HOSPITAL NAME

Pain Management for  
Pets

## REFERRING VET

Eugene Rivers, DVM

## INVOICE

72565

## DATE

12/14/25

The information and recommendations provided are based on the images presented by the referring veterinarian/sonographer. No evaluation can be communicated regarding pathology that was not visible in the image/video clips provided.

Thank you for this referral. If the clinical or image interpretation does not parallel your findings or if I can be of any further assistance please contact me.

**Eric Lindquist**, DMV, DABVP(CFM), Cert. IVUSS,  
CEO, Owner, Founder -- SonoPath.com  
[info@SonoPath.com](mailto:info@SonoPath.com)