

**DATE**

12/14/21

PRESENTING CLINICAL SIGNS

History: Presenting Complaint: Vomiting; Not Eating. Date: 12-11-2021 Notes: started vomiting on Wednesday- initially food, now bile; not really eating; not able to hold down water; had been given french fries and MM prior; husband found a large hole dug in the ground- this is the dog that likes to dig in the yard; has artificial grass; has bamboo; there had been bamboo in one of the vomitus. History - ear infections, loose bowel movement recently- no blood in it. Assessment: vomiting; poor appetite. Plan: discussed possible causes for vomiting; recommend hospitalization, IVF, bloodwork, xrays, medical management. Current Medications: Insulin (Humulin N), Clavamox, Ondansetron, Cerenia, Metronidazole, Omeprazole. Diphenhydramine, Potassium Chloride, Potassium tablets, Pantoprazole, Unasyn.

PATIENT

Willow Fell

SPECIES

Canine

BREED

Labrador Retriever Mix

Lab Results: Attached separately.

Radiographs: Attached separately.

Date of Previous IntraPet Ultrasound: No previous IntraPet scans.

Sedation: Not required to complete full diagnostic ultrasound.

Stat Report: Not requested.

SEX

Spayed Female

ULTRASONOGRAPHIC EXAMINATION OF THE ABDOMEN**Urinary System**

The **urinary bladder**, trigone, and pelvic urethra presented normal thicknesses and normal tone. The ureters were not visible which is normal. No uroliths or sediment were visualized and anechoic urine was present. No evidence of inflammatory or neoplastic changes was noted. Ureteral papillae were normal.

AGE

12/14

The **kidneys** were normal in size and contour; however, a minor hyperechoic ring was noted at the corticomedullary junction. This is consistent with diabetic nephropathy. This is likely from glucosuria.

WEIGHT

63.5 lbs

However, assessment for proteinuria is also warranted. This is an idiopathic finding, but an expected finding in diabetic patients. The left kidney measured 7.33 cm. The right kidney measured 6.42 cm.

INTERPRETED BYEric Lindquist, DMV
DABVP, Cert. IVUSS**Adrenal Glands**

Both **adrenal glands** were visualized and recognized as having normal shape, size, position and echogenicity for this breed. The phrenic vasculature, glandular echogenicity and detail were unremarkable. Capsule, cortex, and medullary definition were normal for this age patient. The left adrenal gland measured 2.95 x 0.95 cm at the caudal pole and 0.98 cm at the cranial pole. The right adrenal gland measured 2.48 x 0.84 cm at the caudal pole and 0.78 cm at the cranial pole.

IMAGING PERFORMED BY

Rachel Brillhart RDMS

Spleen

The **spleen** presented a smooth homogeneous parenchyma hyperechoic to liver and renal cortical parenchyma. The capsule was smooth without noticeable expansion or deviation from within the spleen or adjacent pathology. The splenic vasculature demonstrated normal volume without signs of congestion or thrombosis. No sonographic evidence of acute or chronic inflammatory, neoplastic, or infarctual changes was noted.

HOSPITAL NAMEAnimal Emergency
Hospital**REFERRING VET**

Dr. Willer

Liver

The **liver** was diffusely hyperechoic to the falciform fat. The hepatic parenchyma was uniform. The gallbladder and common bile duct were unremarkable.

INVOICE

94612

Gastrointestinal

Examination of the **gastrointestinal tract** revealed a stomach and intestine free of stasis, of normal wall thickness, acceptable curvilinear mural detail, and peristaltic activity. Small and large intestine demonstrated

normal luminal chyme and stool consistency respectively. No obstructive or overt infiltrative disease was noted. No associated abnormal lymphatic activity was noted.

Pancreas

The **pancreas** revealed extensive, mixed hypoechoic parenchymal changes and irregular contour. The pancreas measured up to 1.95 cm. Extensive pancreatic pathology was noted in the left and right limbs.

ULTRASONOGRAPHIC FINDINGS

Extensive pancreatitis.

Diabetic hepatopathy with inflammatory component.

INTERPRETATION OF THE FINDINGS & FURTHER RECOMMENDATIONS

FNA of the hypoechoic pancreatic parenchyma and liver is recommended for further definition. Aggressive treatment for pancreatitis is warranted. Plasma expanders, GI protectants, broad spectrum antibiotics are all recommended. Insulin dosing should be done carefully as the pancreatic inflammation recedes on medical management, insulin production may be somewhat restored. Recheck sonogram in 72 hours.

Potential Causes of Diabetic Dysregulation

This is a suggestive checkoff list when faced with an unregulated diabetic patient:

UTI

Dietary indiscretion/intolerance

Pancreatitis

Hyperthyroidism/hypothyroidism

Exogenous steroids (including topical eye meds)

Cushing's

Acromegaly

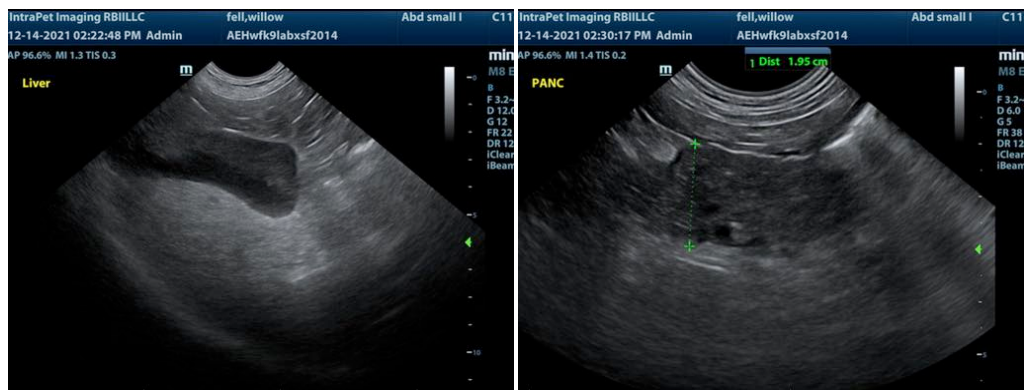
Owner compliance

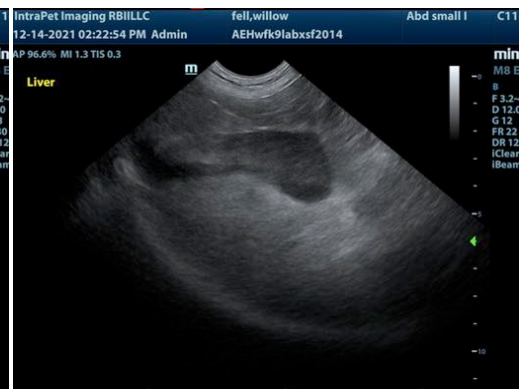
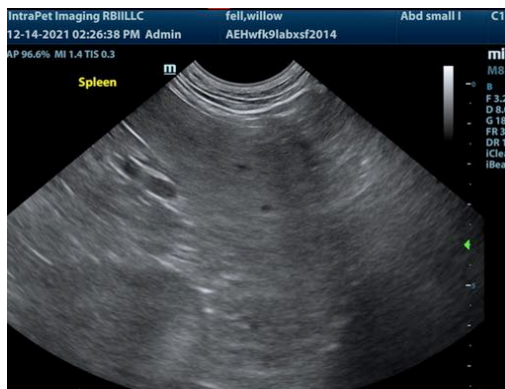
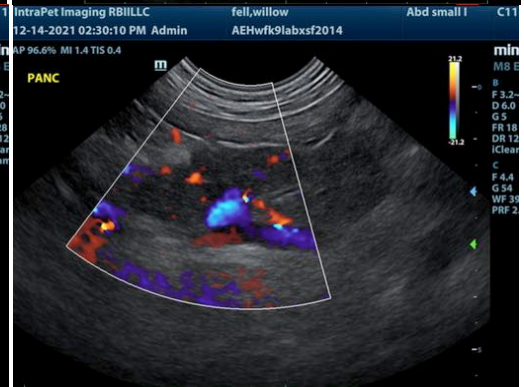
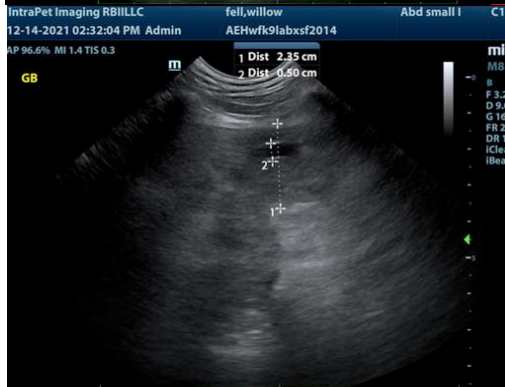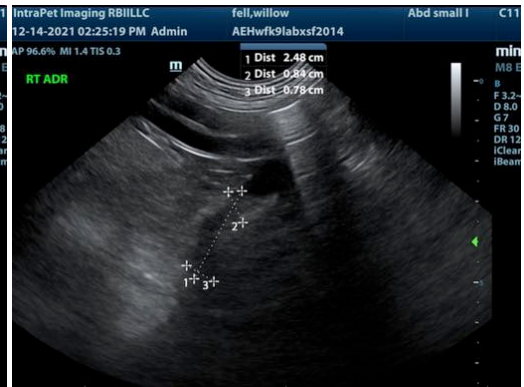
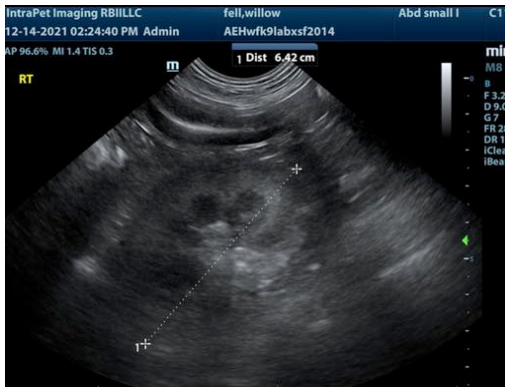
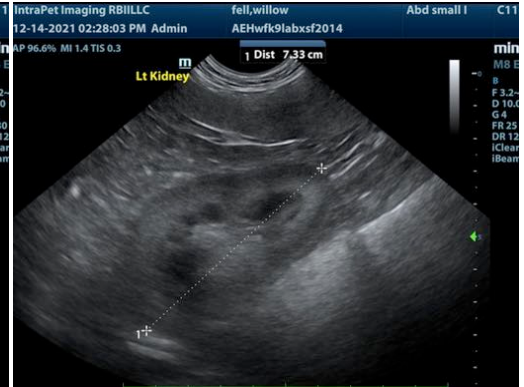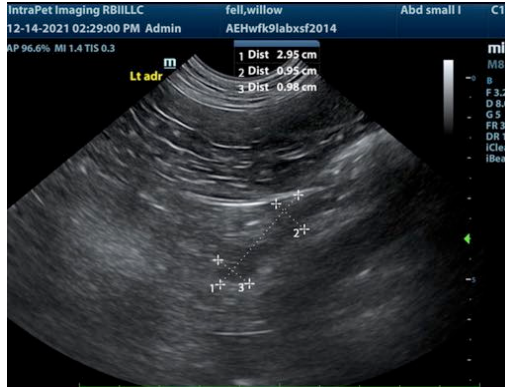Insulin quality issues

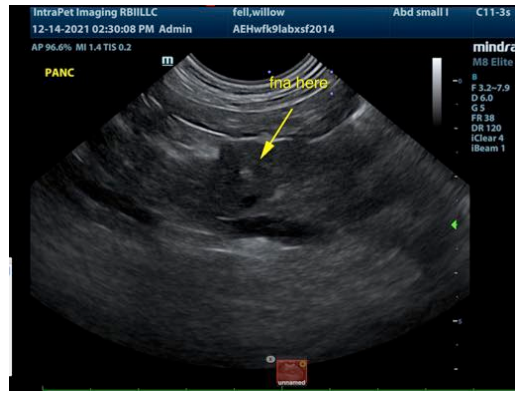
Antibodies to insulin

Underlying Neoplasia

Diffuse liver disease







The information and recommendations provided are based on the images presented by the referring veterinarian. No evaluation can be communicated regarding pathology that was not visible in the image/video clips provided.

Thank you for this referral. If the clinical or image interpretation does not parallel your findings or if I can be of any further assistance please contact me.

Eric Lindquist, DMV, DABVP, Cert. IVUSS, CEO of SonoPath.com
Eric.Lindquist@SonoPath.com