



**PATIENT**

Newman Hackett

**SPECIES**

Canine

**BREED**

Welsh Corgi

**SEX**

Neutered male

**AGE**

10 years

**WEIGHT**

30 lbs

**INTERPRETED BY**

Eric Lindquist, DMV  
DABVP, Cert. IVUSS

**IMAGING PERFORMED BY**

Dr. Griffin

**HOSPITAL NAME**

Northside VC

**REFERRING VET**

Dr. Griffin

**INVOICE**

94598

**DATE**

12/14/21

**PRESENTING CLINICAL SIGNS**

History: Patient has been on Denamarin for increased liver values and presented today for dental cleaning however pre-anesthetic bloodwork showed liver values had gone up more  
CBC: WNL Chem: TP 8.3, ALT 572, ALP 213

**ULTRASONOGRAPHIC EXAMINATION OF THE ABDOMEN**

**Urinary System**

The **urinary bladder**, trigone, and pelvic urethra presented normal thicknesses and normal tone. The ureters were not visible which is normal. No uroliths or sediment were visualized and anechoic urine was present. No evidence of inflammatory or neoplastic changes was noted. Ureteral papillae were normal.

The **kidneys** revealed largely normal size and structure, corticomedullary definition and ratio (cortex 1/3 of medulla) were essentially maintained with some age-related loss of curvilinear patterns regarding the capsule and C/M junction. The cortices presented largely uniform texture with some increased echogenicity expected for this age patient. Medullary structure differed distinctly from that of the cortex and no evidence of pelvic dilation was present. The right kidney measured 6.0 cm. The left kidney measured 6.0 cm.

**Adrenal Glands**

Both **adrenal glands** were visualized and recognized as having normal shape, size, position and echogenicity for this breed. The phrenic vasculature, glandular echogenicity and detail were unremarkable. Capsule, cortex, and medullary definition were normal for this age patient. The right adrenal gland measured 0.8 cm. The left adrenal gland measured 0.7 cm.

**Spleen**

The **spleen** presented a smooth homogeneous parenchyma hyperechoic to liver and renal cortical parenchyma. The capsule was smooth without noticeable expansion or deviation from within the spleen or adjacent pathology. The splenic vasculature demonstrated normal volume without signs of congestion or thrombosis. No sonographic evidence of acute or chronic inflammatory, neoplastic, or infarctual changes was noted.

**Liver**

The **liver** revealed increased portal markings with coarse architecture. Isoechoic nodular changes were noted. This is consistent with hepatic fibrosis and pronounced nodular hyperplasia. The gallbladder presented acceptably thin walls with primarily anechoic content. The cystic and common bile ducts were normal. No pathological hepatic lymphadenopathy was evident.



**PATIENT**

**Gastrointestinal**

Newman Hackett

Examination of the **gastrointestinal tract** revealed a stomach and intestine free of stasis, of normal wall thickness, acceptable curvilinear mural detail, and peristaltic activity. Small and large intestine demonstrated normal luminal chyme and stool consistency respectively. No obstructive or overt infiltrative disease was noted. No associated abnormal lymphatic activity was noted.

**SPECIES**

Canine

**BREED**

Welsh Corgi

**Pancreas**

The base and limbs of the **pancreas** were observed to be largely isoechoic to surrounding omental fat. Pancreatic duct and capsular contour were acceptably normal and parenchyma respected normal curvilinear patterns. No overt evidence of active inflammatory or neoplastic disease was noted.

**SEX**

Neutered male

**ULTRASONOGRAPHIC FINDINGS**

Nodular hepatic changes.

**AGE**

10 years

Otherwise, unremarkable abdomen.

**WEIGHT**

30 lbs

**INTERPRETATION OF THE FINDINGS & FURTHER RECOMMENDATIONS**

Bile acid profile and core biopsy is indicated. The probability of neoplasia is minor. Leptospirosis titers are indicated. Core liver biopsy is strongly recommended. If the bile acids are normal then anesthetic risk is minor; however, I recommend bile acid profile prior to any sedation.

**INTERPRETED BY**

Eric Lindquist, DMV  
DABVP, Cert. IVUSS

**IMAGING PERFORMED BY**

Dr. Griffin

**HOSPITAL NAME**

Northside VC

**REFERRING VET**

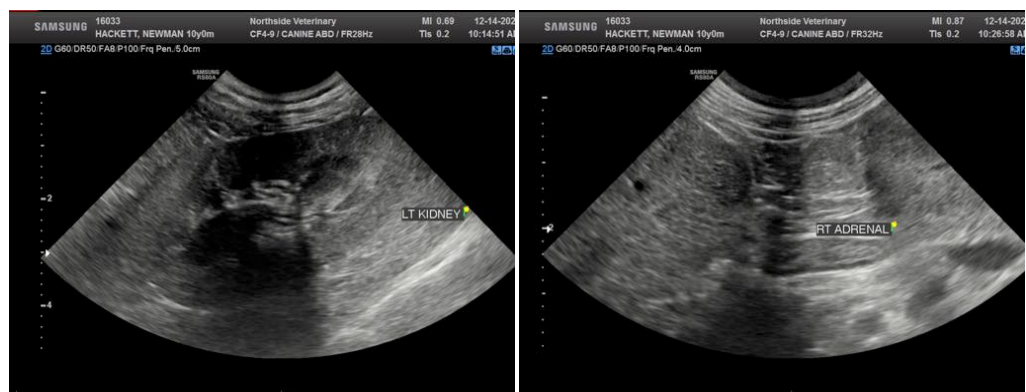
Dr. Griffin

**INVOICE**

94598

**DATE**

12/14/21





**PATIENT**

Newman Hackett

**SPECIES**

Canine

**BREED**

Welsh Corgi

**SEX**

Neutered male

**AGE**

10 years

**WEIGHT**

30 lbs

**INTERPRETED BY**

Eric Lindquist, DMV  
DABVP, Cert. IVUSS

**IMAGING PERFORMED BY**

Dr. Griffin

**HOSPITAL NAME**

Northside VC

**REFERRING VET**

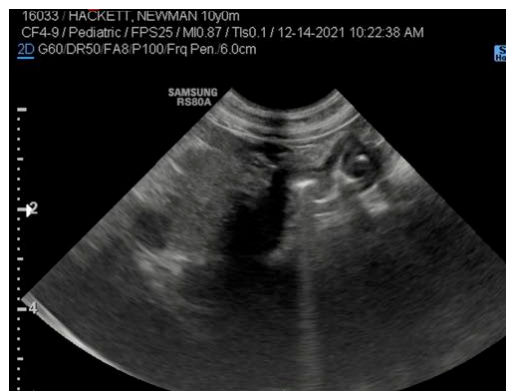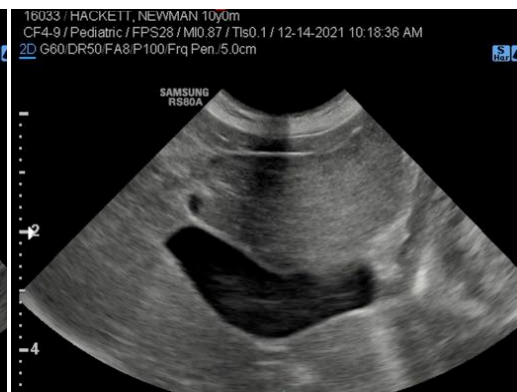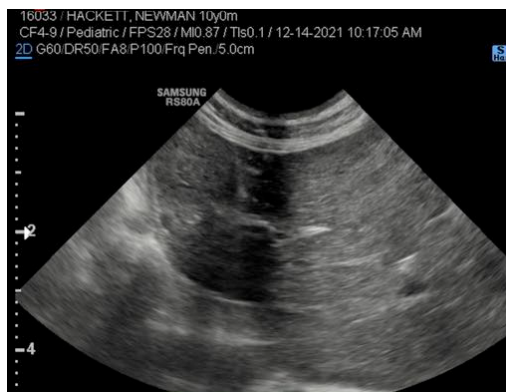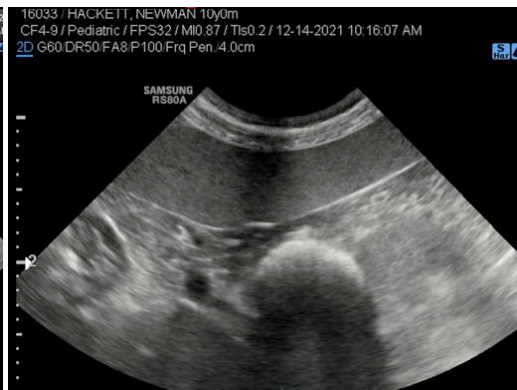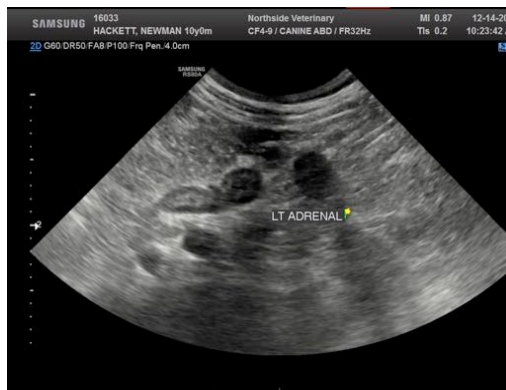Dr. Griffin

**INVOICE**

94598

**DATE**

12/14/21



The information and recommendations provided are based on the images presented by the referring veterinarian. No evaluation can be communicated regarding pathology that was not visible in the image/video clips provided.

Thank you for this referral. If the clinical or image interpretation does not parallel your findings or if I can be of any further assistance please contact me.

Eric Lindquist, DMV, DABVP, Cert. IVUSS, CEO of SonoPath.com



**PATIENT**

info@SonoPath.com

Newman Hackett

**SPECIES**

Canine

**BREED**

Welsh Corgi

**SEX**

Neutered male

**AGE**

10 years

**WEIGHT**

30 lbs

**INTERPRETED BY**

Eric Lindquist, DMV  
DABVP, Cert. IVUSS

**IMAGING  
PERFORMED BY**

Dr. Griffin

**HOSPITAL NAME**

Northside VC

**REFERRING VET**

Dr. Griffin

**INVOICE**

94598

**DATE**

12/14/21