



**PATIENT PRESENTING CLINICAL SIGNS**

**PATIENT** Lola Carlson  
**SPECIES** Canine  
**BREED** Bichon Mix  
**SEX** Spayed Female  
**AGE** 13 years  
**WEIGHT** 11 lbs  
**INTERPRETED BY** Eric Lindquist, DMV DABVP, Cert. IVUSS  
**IMAGING PERFORMED BY** Dr. Rodriguez  
**HOSPITAL NAME** Foxfield VS

**PRESENTING CLINICAL SIGNS**  
 History: Heart murmur 3/6. Prev dx with B2 valv dz and on vetmedin and viagra. Recent episodes of syncope vs mild seizures  
 Abnormal PE/Chem/CBC/UA Results: N/A

**ULTRASONOGRAPHIC EXAMINATION OF THE HEART**

Moderate volume overload of the **left atrium** and **left ventricle** was noted with tachycardia and mitral valve prolapse. All three parameters of left atrial size evaluation are excessive. **Contractility** of the ventricular walls was adequate and in normal range for this patient evidenced by the fractional shortening measurement and subjective evaluation of the different regions of the myocardium. The **left ventricular outflow** tract demonstrated normal laminar flow and subjective structural integrity. The **right atrium** and auricle revealed normal size, structure and content. No evidence of masses was noted. **Tricuspid** insufficiency was noted and is likely underestimated at 2.8 m/sec. The **right ventricle** was of normal size (1/3 diameter of LV), chordae structure, myocardial echogenicity and thickness. **Pulmonary outflow** tract assessment revealed normal valve structure, laminar flow, and diameter (pprox..1:1 pa/ao ratio). No visible **pericardial** or free pleura fluid was noted. The cranial **mediastinum** and **pericardial and extra-cardiac regions** were free of masses in the visible window.

| CANINE CARDIAC PARAMETERS | MR VMAX (m/s) | TR VMAX (m/s) | LA/AO (Boon method) | LA/AO (Heart Base; Swe) | FS (%)                            | EF (%)                                     | EPSS (cm)                                  |
|---------------------------|---------------|---------------|---------------------|-------------------------|-----------------------------------|--|--|
| NORMAL PARAMETER          | 4.5-5.5       | <2.7          | 1.3                 | <1.6                    | 28-40                             | 40-100                                     | <0.6                                       |
| PATIENT                   | 6.2           | 2.8           | 1.6                 | 2.7                     | 45                                | 80   | 0.11                                       |
| CANINE CARDIAC PARAMETERS | HR (BPM)      | AV VMAX (m/s) | PV MAX (m/s)        | BODY WEIGHT             | LA (2D short axis Base view) (cm) | LVIDd (Avg; 2D and m-mode short axis) (cm) | LVIDs (Avg; 2D and m-mode short axis) (cm) |
| NORMAL PARAMETER          | 50-100        | 0.7-1.7       | 0.7-1.6             |                         |                                   |  |  |
| PATIENT                   |               | 1.8           |                     | 11 lbs                  | 3.54                              | 3.2  |  |

**REFERRING VET ULTRASONOGRAPHIC FINDINGS**

**REFERRING VET** Dr. Rodriguez  
 Volume overload of the left atrium and left ventricle.  
 Mitral prolapse.

**INVOICE**

94606

**INTERPRETATION OF THE FINDINGS & FURTHER RECOMMENDATIONS**

**DATE**

12/14/21

Given the patient's history blood pressure measurements are warranted. If the systolic pressure is > 160 then adding ace inhibitor is recommended. I also recommend adding Spironolactone at 1-2 mg/kg b.i.d.



**PATIENT**

and Lasix at 1-2 mg/kg b.i.d. Holter monitor would be optimal in this patient to assess for paroxysmal arrhythmia that may be playing a role in the syncope.

Lola Carlson

**SPECIES**

Canine

**BREED**

Bichon Mix

**SEX**

Spayed Female

**AGE**

13 years

**WEIGHT**

11 lbs

**INTERPRETED BY**

Eric Lindquist, DMV  
DABVP, Cert. IVUS

**IMAGING PERFORMED BY**

Dr. Rodriguez

**HOSPITAL NAME**

Foxfield VS

**REFERRING VET**

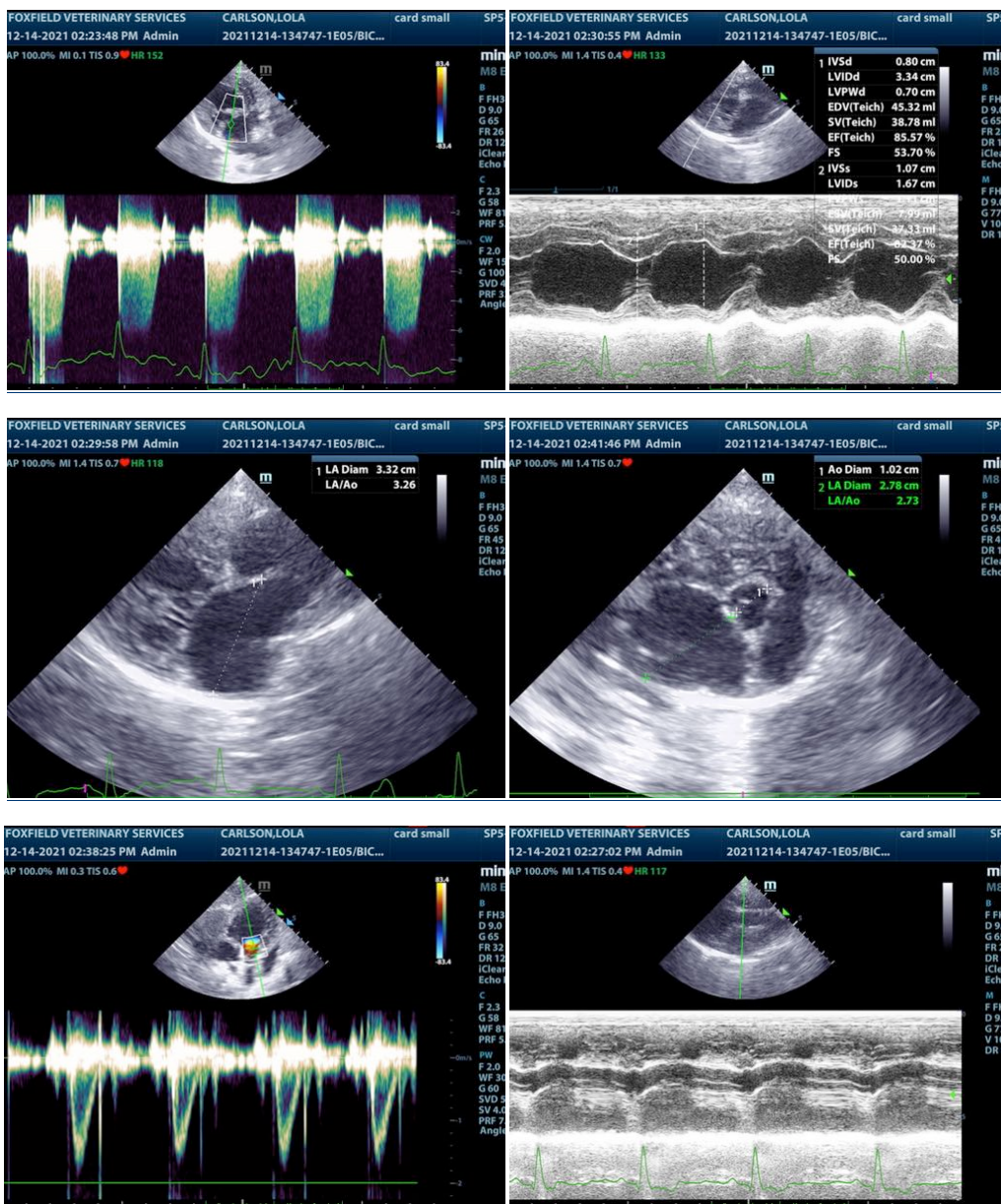
Dr. Rodriguez

**INVOICE**

94606

**DATE**

12/14/21





**PATIENT**

Lola Carlson

**SPECIES**

Canine

**BREED**

Bichon Mix

**SEX**

Spayed Female

**AGE**

13 years

**WEIGHT**

11 lbs

**INTERPRETED BY**

Eric Lindquist, DMV  
DABVP, Cert. IVUSS

**IMAGING PERFORMED BY**

Dr. Rodriguez

**HOSPITAL NAME**

Foxfield VS

**REFERRING VET**

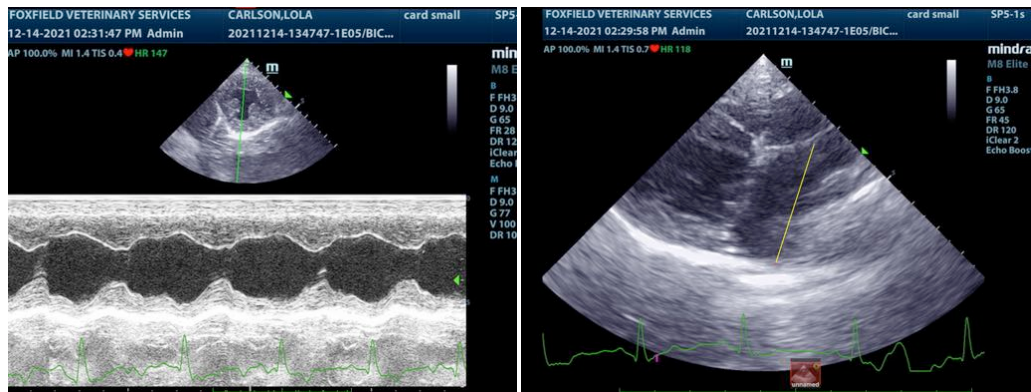
Dr. Rodriguez

**INVOICE**

94606

**DATE**

12/14/21



The information and recommendations provided are based on the images presented by the referring veterinarian. No evaluation can be communicated regarding pathology that was not visible in the image/video clips provided.

Thank you for this referral. If the clinical or image interpretation does not parallel your findings or if I can be of any further assistance please contact me.

**Eric Lindquist, DMV, DABVP, Cert. IVUSS, CEO of SonoPath.com**  
info@SonoPath.com