



PATIENT

Bella Eros

SPECIES

Feline

BREED

DSH

SEX

Spayed Female

AGE

2009

WEIGHT

13.98 lbs

INTERPRETED BY

Eric Lindquist, DMV
DABVP, Cert IVUSS

**IMAGING
PERFORMED BY**

Denise Bruno, LVT,
RDMS

HOSPITAL NAME

Brooklyn Heights VH

REFERRING VET

Dr. Thomson

INVOICE

0000

DATE

12/14/21

PRESENTING CLINICAL SIGNS

History: Inappetence, weight loss, lethargy

Evaluate for GI dx vs pancreatitis vs other

Labs attached

ULTRASONOGRAPHIC EXAMINATION OF THE ABDOMEN

Urinary System

The **urinary bladder**, trigone, and pelvic urethra presented normal thicknesses and normal tone. The pelvic urethra was imaged 3.0 cm beyond the cystourethral junction. The ureters were not visible which is normal. No uroliths or sediment were visualized and anechoic urine was present. No evidence of inflammatory or neoplastic changes was noted. Ureteral papillae were normal.

The **kidneys** revealed normal size and structure, corticomedullary definition and ratio for this age. The cortices presented largely uniform texture with normal echogenic relationship to liver and spleen. Medullary structure differed distinctly from the cortex and no evidence of pelvic dilation was present. The capsules were acceptably uniform without significant irregularities. A cortical infarct was noted in the caudal pole of the left kidney. The right kidney measured 3.10 cm. The left kidney measured 5.02 cm.

Adrenal Glands

Both **adrenal glands** were visualized and recognized as having normal shape, size, position and echogenicity for this breed. The phrenic vasculature, glandular echogenicity and detail were unremarkable. Capsule, cortex, and medullary definition were normal for this age patient. The left adrenal gland measured 0.24 cm.

Spleen

The **spleen** was mildly enlarged with uniform, but subtly micronodular parenchyma, and undulating capsular contour. This is consistent with reactive spleen owing to immune stimulus or early infiltrative disease such as mast cell disease or lymphoma. 25-gauge FNA would be ideal if weight loss is an issue to differentiate early round cell neoplasia versus splenitis or reactive spleen all of which can present in this manner. The spleen measured 1.0 cm in width.

Liver

The **liver** was slightly subnormal in size. Mild cystadenoma type lesion is noted and measured 0.82 x 1.0 cm in the cranial liver. A second cystadenoma type lesion was noted in the left cranial liver. The liver was slightly hyperechoic to the falciform fat. The gallbladder presented some dependent debris with essentially normal contour. The cystic and common bile ducts were normal. No overt evidence of active inflammatory, infiltrative or regenerative pathology was noted but should be paired with current or past LE elevations regarding any clinical significance to this presentation. The hepatic lymph nodes were unremarkable.



PATIENT

Gastrointestinal

Bella Eros

Examination of the **gastrointestinal tract** revealed a stomach and intestine free of stasis, of normal wall thickness, acceptable curvilinear mural detail, and peristaltic activity. Small and large intestine demonstrated normal luminal chyme and stool consistency respectively. No obstructive or overt infiltrative disease was noted. No associated abnormal lymphatic activity was noted.

SPECIES

Feline

BREED

DSH

SEX

Spayed Female

AGE

2009

WEIGHT

13.98 lbs

Pancreas

The **pancreas** revealed prominent, irregular contour.

ULTRASONOGRAPHIC FINDINGS

Prominent, irregular pancreas. Cystadenomatous type liver lesions were noted.

Age related renal changes with minor infarct in the left kidney.

INTERPRETATION OF THE FINDINGS & FURTHER RECOMMENDATIONS

Given the patient's history underlying pancreatitis is suspected. Subxiphoid palpation is recommended to assess for pain-solicited response. If pain is noted low grade pancreatitis is suspected.

INTERPRETED BY

Eric Lindquist, DMV
DABVP, Cert IVUSS

IMAGING PERFORMED BY

Denise Bruno, LVT,
RDMS

HOSPITAL NAME

Brooklyn Heights VH

REFERRING VET

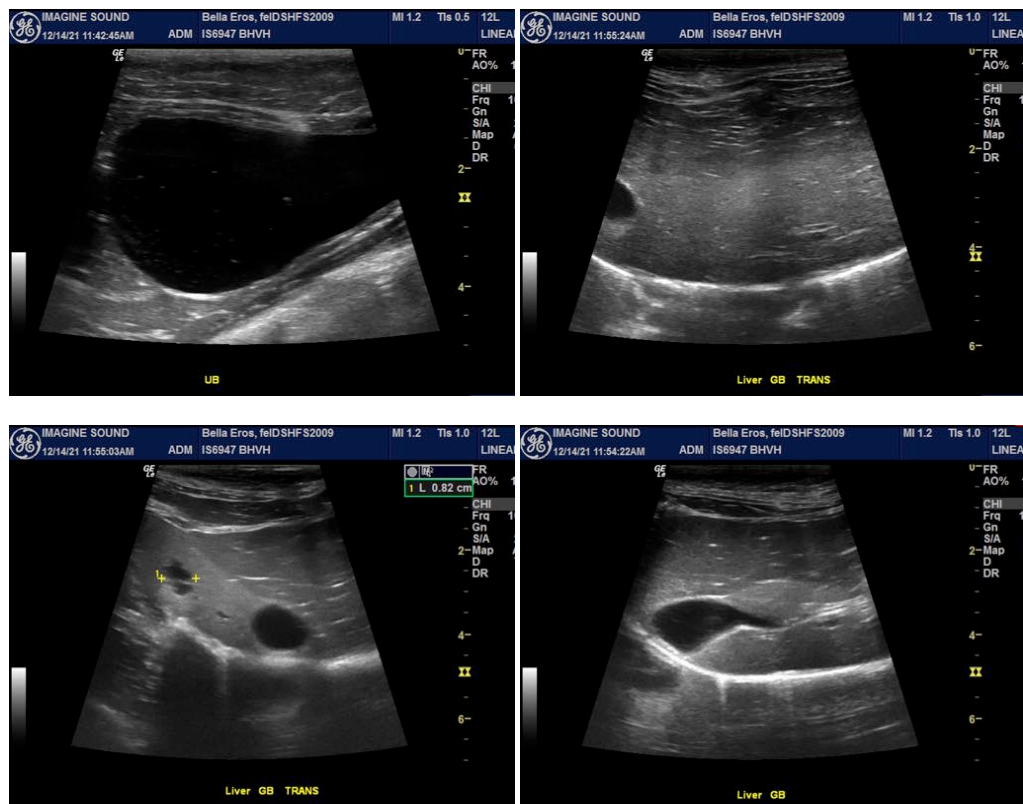Dr. Thomson

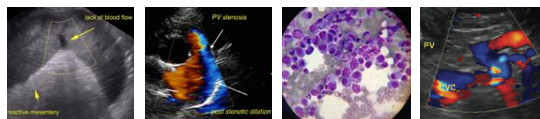
INVOICE

0000

DATE

12/14/21





PATIENT

Bella Eros

SPECIES

Feline

BREED

DSH

SEX

Spayed Female

AGE

2009

WEIGHT

13.98 lbs

INTERPRETED BY

Eric Lindquist, DMV
DABVP, Cert IVUSS

**IMAGING
PERFORMED BY**

Denise Bruno, LVT,
RDMS

HOSPITAL NAME

Brooklyn Heights VH

REFERRING VET

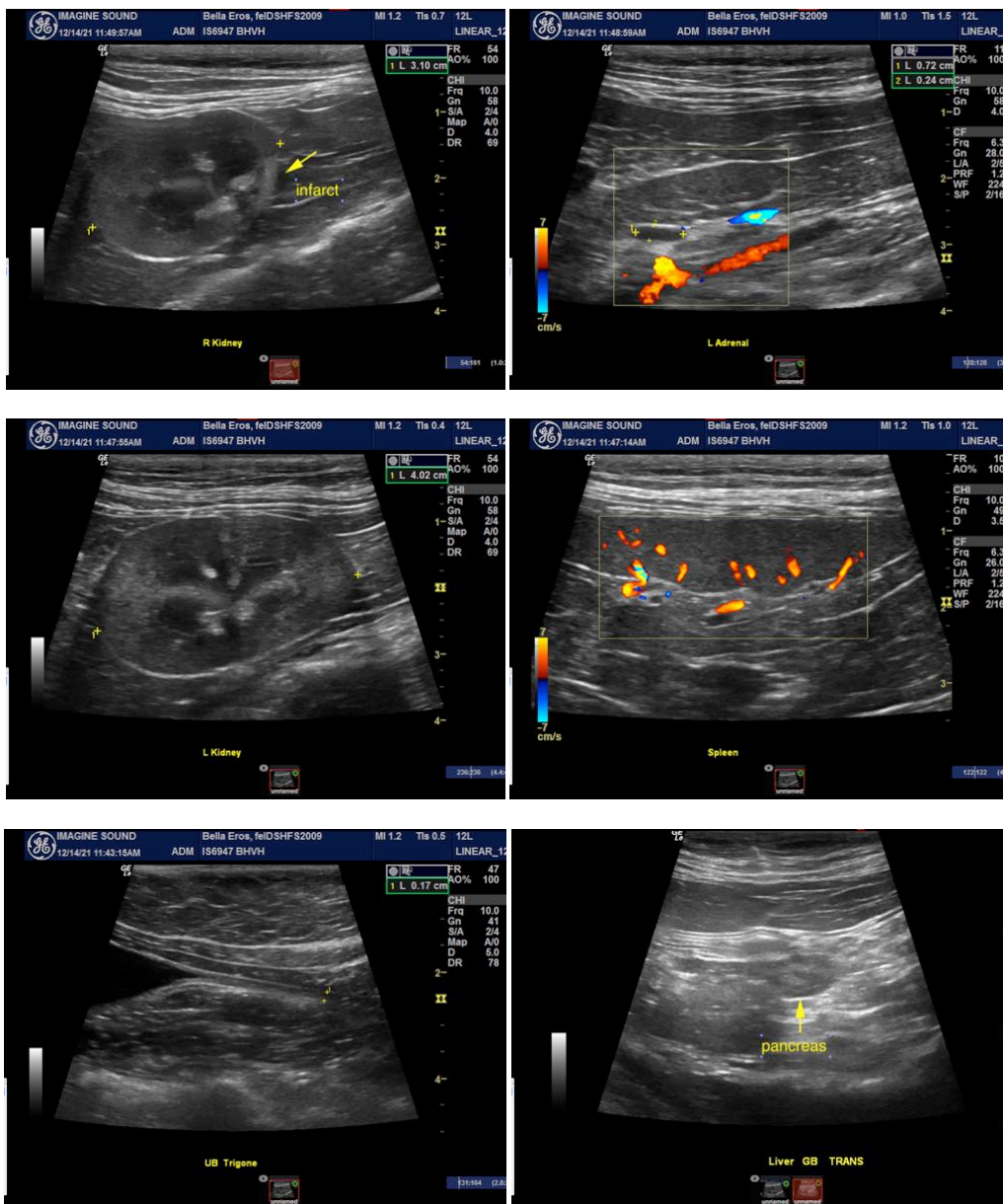
Dr. Thomson

INVOICE

0000

DATE

12/14/21



The information and recommendations provided are based on the images presented by the referring veterinarian. No evaluation can be communicated regarding pathology that was not visible in the image/video clips provided.

Thank you for this referral. If the clinical or image interpretation does not parallel your findings or if I can be of any further assistance please contact me.

Eric Lindquist, DMV, DABVP, Cert. IVUSS, CEO of SonoPath.com
Eric.Lindquist@SonoPath.com