



## PATIENT

Leroy Winans

## SPECIES

Canine

## BREED

Frenchie

## SEX

Neutered Male

## AGE

2

## WEIGHT

18.3

## INTERPRETED BY

Eric Lindquist, DMV,  
DABVP (CFM), Cert.  
IVUSS

## IMAGING PERFORMED BY

Jenn

## HOSPITAL NAME

Rockaway AH

## REFERRING VET

Dr. Maniar

## INVOICE

35868

## DATE

12/13/25

## PRESENTING CLINICAL SIGNS

History: vomited once, straining to defecate, febrile  
Abnormal PE/Chem/CBC/UA Results: WNL

## ULTRASONOGRAPHIC EXAMINATION OF THE ABDOMEN

### *Urinary System*

The **urinary bladder**, trigone, and pelvic urethra presented normal thicknesses and normal tone. The ureters were not visible which is normal. No uroliths or sediment were visualized and anechoic urine was present. No evidence of inflammatory or neoplastic changes was noted. Ureteral papillae were normal. The pelvic urethra was imaged 2.0 cm beyond the cystourethral junction.

The **kidneys** revealed normal size and structure, corticomedullary definition and ratio for this age. The cortices presented largely uniform texture with normal echogenic relationship to liver and spleen. Medullary structure differed distinctly from the cortex, and no evidence of pelvic dilation was present. The capsules were acceptably uniform without significant irregularities. The right kidney measured 4.5 cm. The left kidney measured 4.25 cm.

### *Adrenal Glands*

Both **adrenal glands** were visualized and recognized as having normal shape, size, position and echogenicity for this breed. The phrenic vasculature, glandular echogenicity and detail were unremarkable. Capsule, cortex, and medullary definition were normal for this age patient. The left adrenal gland measured 0.5 cm. The right adrenal gland measured 0.5 cm.

### *Spleen*

The **spleen** presented a smooth homogeneous parenchyma hyperechoic to liver and renal cortical parenchyma. The capsule was smooth without noticeable expansion or deviation from within the spleen or adjacent pathology. The splenic vasculature demonstrated normal volume without signs of congestion or thrombosis. No sonographic evidence of acute or chronic inflammatory, neoplastic, or infarctual changes were noted.

### *Liver*

The **liver** images submitted revealed subjectively normal liver size, contour, and structure. Parenchymal echogenicity was naturally coarse and hypoechoic to the spleen. Vascular and biliary tracts were of normal volume with no evidence of congestion. The gallbladder presented acceptably thin walls with primarily anechoic content. The cystic and common bile ducts were normal. No pathological hepatic lymphadenopathy was evident. No overt structural evidence of inflammatory, infiltrative or regenerative pathology was evident.

### *Gastrointestinal*

The **stomach** was filled with ingesta. The small intestine and colon were unremarkable with normal curvilinear patterns and content. No overt evidence of foreign body, however, delayed outflow may be an issue, as ingesta was still persistently present in the stomach. No shadowing material was noted.

### *Pancreas*



**PATIENT**

Leroy Winans

**SPECIES**

Canine

**BREED**

Frenchie

**SEX**

Neutered Male

**AGE**

2

**WEIGHT**

18.3

**INTERPRETED BY**

Eric Lindquist, DMV,  
DABVP (CFM), Cert.  
IVUSS

**IMAGING PERFORMED BY**

Jenn

**HOSPITAL NAME**

Rockaway AH

**REFERRING VET**

Dr. Maniar

**INVOICE**

35868

**DATE**

12/13/25

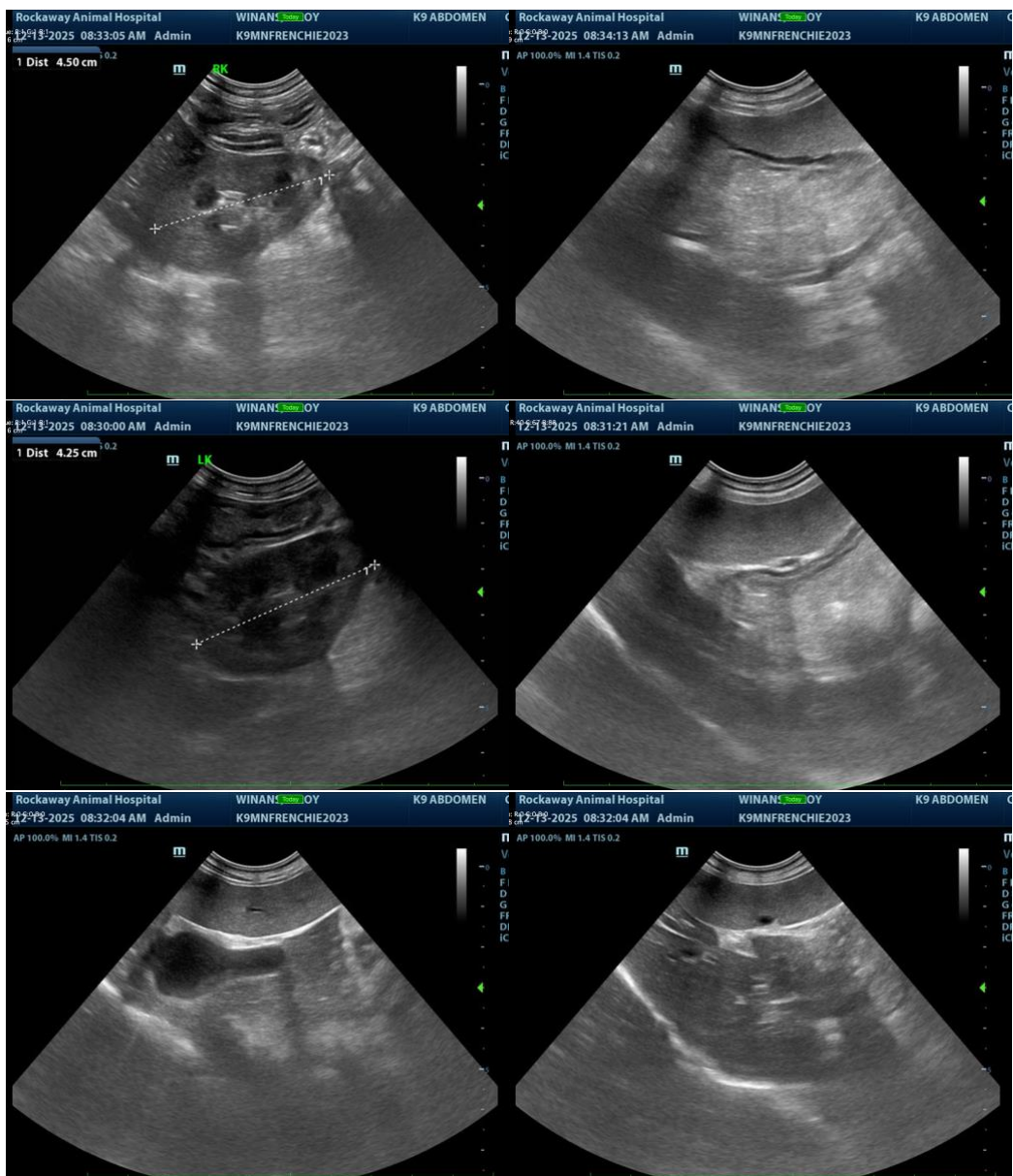
The base and limbs of the **pancreas** were observed to be largely isoechoic to surrounding omental fat. Pancreatic duct and capsular contour were acceptably normal and parenchyma respected normal curvilinear patterns. No overt evidence of active inflammatory or neoplastic disease was noted.

**ULTRASONOGRAPHIC FINDINGS**

- Delayed outflow gastric pattern

**INTERPRETATION OF THE FINDINGS & FURTHER RECOMMENDATIONS**

24-hour NPO and recheck sonogram is indicated. Supportive care is warranted otherwise.



The information and recommendations provided are based on the images presented by the referring



## PATIENT

Leroy Winans

## SPECIES

Canine

## BREED

Frenchie

## SEX

Neutered Male

## AGE

2

## WEIGHT

18.3

## INTERPRETED BY

Eric Lindquist, DMV,  
DABVP (CFM), Cert.  
IVUSS

## IMAGING PERFORMED BY

Jenn

## HOSPITAL NAME

Rockaway AH

## REFERRING VET

Dr. Maniar

## INVOICE

35868

## DATE

12/13/25

veterinarian/sonographer. No evaluation can be communicated regarding pathology that was not visible in the image/video clips provided.

Thank you for this referral. If the clinical or image interpretation does not parallel your findings or if I can be of any further assistance please contact me.

**Eric Lindquist**, DMV, DABVP(CFM), Cert. IVUSS,  
CEO, Owner, Founder -- SonoPath.com  
[info@SonoPath.com](mailto:info@SonoPath.com)